

Prenatal three-dimensional sonographic findings associated with fetal defecation

Robert DANKOVCIK^{1,2}, Svetlana JANOSOVÁ^{1,2}, Silvia VERNEROVA¹, Stela MURANSKA¹, Eduard KUCERA³, Barbora KUBESOVA³, Jan Evangelista JIRASEK⁴, Radoslav MOROCHOVIC⁵, Vladimír FERIANEC⁶, Maria MIKLOSOVA⁷

¹ 2nd Department of Gynecology and Obstetrics, P. J. Safarik University and L. Pasteur University Hospital, Kosice, Slovak Republic

² Center for Prenatal Diagnosis, s.r.o., Kosice, Slovak Republic

³ Department of Gynecology and Obstetrics, Third Faculty of Medicine, Charles University in Prague, Czech Republic

⁴ Mother and Child Care Institute Prague - Podoli, Czech Republic

⁵ Department of Traumatology, P. J. Safarik University and L. Pasteur University Hospital, Kosice, Slovak Republic

⁶ 2nd Department of Obstetrics and Gynecology, School of Medicine, Comenius University, Bratislava, Slovak Republic

⁷ Department of Anatomy, Faculty of Medicine and Dentistry, Palacky University in Olomouc, Czech Republic

Correspondence to: Assoc. Prof. Maria Miklosova, DVM., PhD.
Department of Anatomy, Faculty of Medicine and Dentistry
Palacky University Olomouc,
Hněvotínska 3, Olomouc 77515, Czech Republic.
TEL: +421-903-961-487; E-MAIL: miklosdr@gmail.com

Submitted: 2015-11-14 Accepted: 2015-12-04 Published online: 2015-12-28

Key words: fetal defecation; ultrasound; prenatal diagnosis; 3D ultrasound

Neuroendocrinol Lett 2015; 36(7):656-660 PMID: 26859588 NEL360715C03 © 2015 Neuroendocrinology Letters • www.nel.edu

Abstract

Routine ultrasonography examination may miss fetal defecation and if seen it can be a source of misinterpretation which can lead to a wrong diagnose and management of pregnancy. We report two rare cases of fetal defecation in the second trimester and we describe 3D sonographic findings associated with this condition.

INTRODUCTION

During intrauterine life the human fetus is able to perform many basic physiological functions such as hiccups, swallowing, intestine secretion and transport, digestion and absorption, and immune and endocrine functioning (Ciftci *et al.* 1999). It is accepted that the human fetus *in utero* does not defecate and the presence of meconium in amniotic fluid is a sign of intrauterine asphyxia (Desmond *et al.* 1957). Relatively high incidence of amniotic fluid stained with meconium during labour with low incidence of neonatal complications suppose, that fetal defecation is a sign of normal intrauter-

ine fetal life rather than a consequence of fetal distress. Many experimental and clinical studies have been published supporting this hypothesis.

34-year-old caucasian woman, gravida 3, para 2, examined in the 16+1 gestational week for a positive triple test/risk 4 from 5 for T21) on ultrasound machine GE E 8 Expert (GE Medical systems, Waukesha, WI, USA, abdominal probe RAB 4-8 D). A hypoplastic nasal bone was found on the scan. The examination revealed a tail formed structure in the genital area of a male fetus. During the 3D volume analysis of this area the region of interest was placed so that in the B plane a sagittal view of the pelvis with the complete terminal part

of the intestine was visible. The pivot point was placed in the anal area with scrolling directed towards the anal sphincter (Figure 1B)

Consecutive surface rendering confirmed a communication between the referred tail like structure and the anal opening and suspicion of the presence of stool was expressed (Figure 1C). Amniocentesis was performed after the ultrasound examination and confirmed a 47 XY+21 karyotype. During a check-up scan in 17+3 week the mentioned tail like structure was not observed. The patient opted for a termination of pregnancy, postmortem no pathological structure was found in the genitoanal area, this confirms the fact that during the first ultrasound examination fetal defecation was recorded (Figure 1D)

38-year-old caucasian woman, gravida 2, para 1, was initially referred for a routine second trimester ultrasound scan. The integrated test was negative, with a T21 risk 1: 27000. During the examination a tail like structure in the genital area was observed (Figure 2C,D), 3D volume analysis after setting the sagittal view through the terminal part of large intestine displayed a direct connection between the structure and anus thus suspicion of fetal defecation was assumed (Figure 2 A,B,E). The ultrasound examination was repeated within a

45-minute interval. During the consecutive scan no such structure was visible.

The pregnancy proceeded uncomplicated and delivery occurred at 38 weeks spontaneously / female 2940 g, 48 cm, APGAR score 10/10/10. The genital area with no pathological finding.

Observation of fetal defecations was performed in two centers of prenatal diagnosis from 1st January 2009 until 31st January 2014. In the Center of prenatal diagnosis s.r.o. we observed the two above mentioned fetal defecations during the second trimester scan from the total of 9921 examinations. During the 5271 scans performed at the Clinic of Obstetrics and Gynecology 3. Faculty hospital Prague no defecation was seen. Of the total of 15192 examined patients, fetal defecation was observed in two cases representing a prevalence of 0.013% in this sample of population. Due to the fact that no false positive or false negative assessment was provided, the diagnostic sensitivity and specificity of the prenatal ultrasound examination reached 100%.

Up to this date only few studies investigating fetal defecation during the intrauterine period by ultrasound exist.

In the study of Ramon y Cayal (2004), in 240 fetuses between the 15–41 week of gestation, were examined by ultrasound. Fetal defecation was defined as expulsion

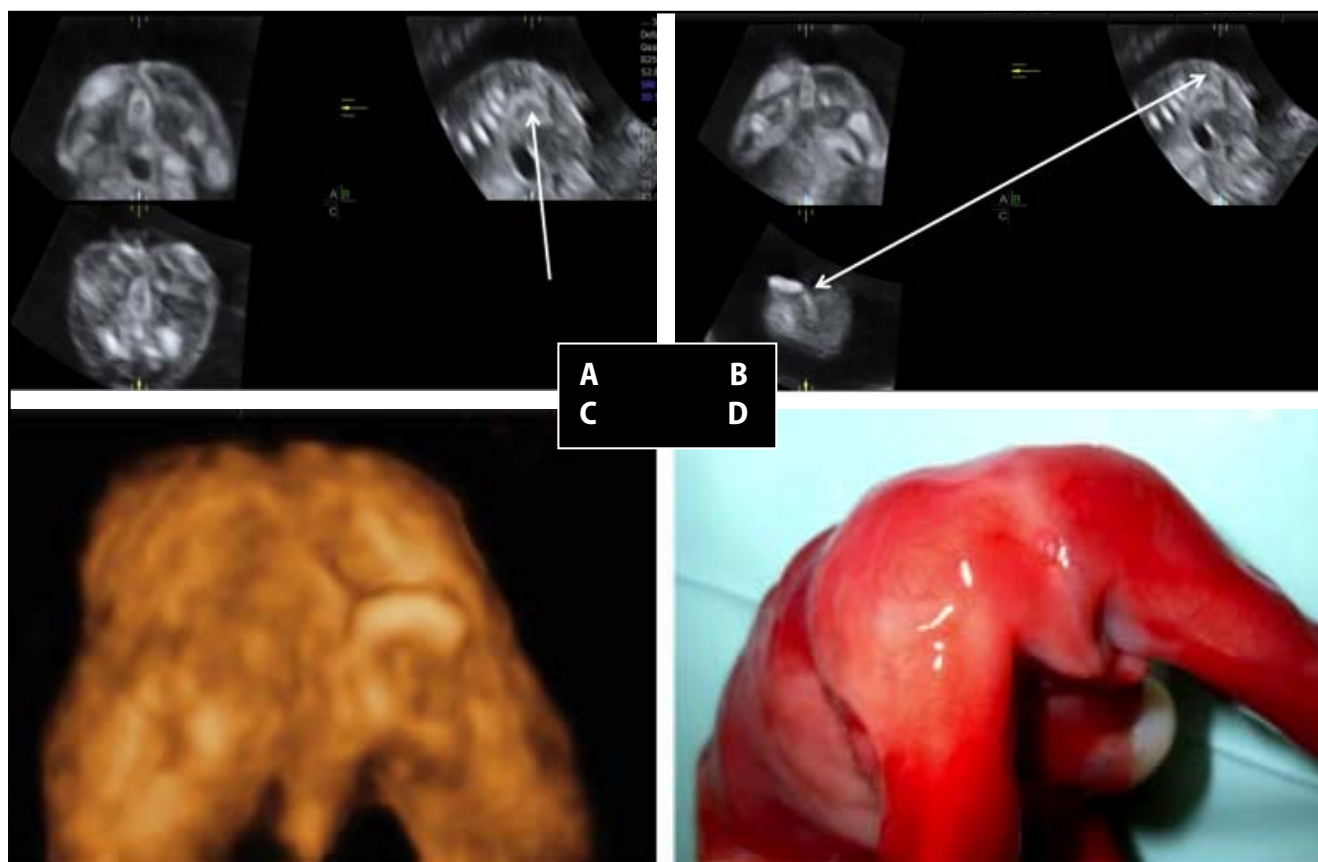


Fig. 1. Case 1: A. multiplanar view + VCI-C. In the B plane the pivot point (white arrow) is placed in the terminal part of the large intestine. B. multiplanar view + VCI-I. B plane – pivot point is placed in the terminal part of visualized in the C plane (bidirectional white arrow). C. 3D surface rendering of the genitoanal area and fetal defecation. D. Photograph of autopsy specimen of the fetus after TOP, normal anal and genitoanal area.

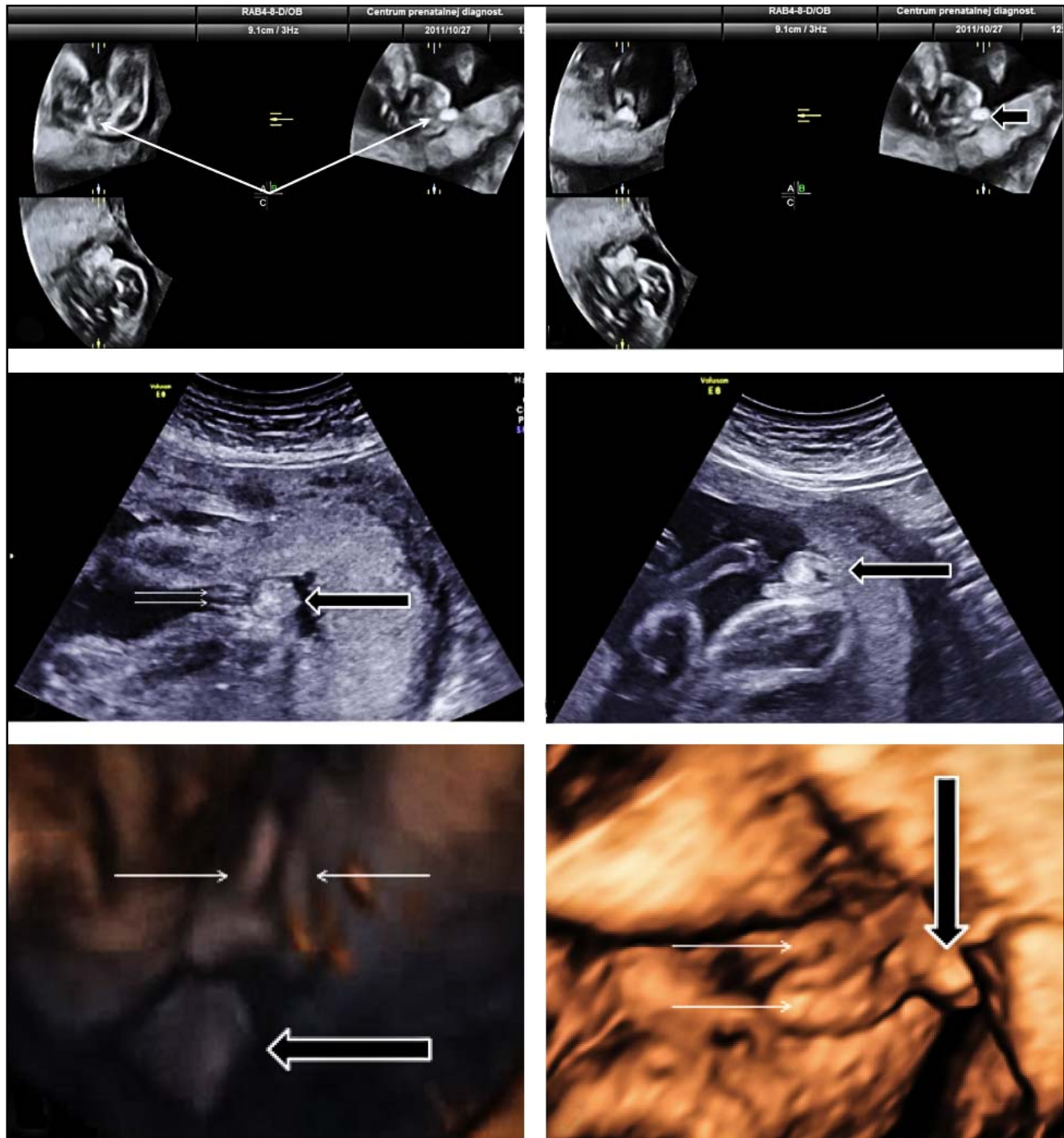


Fig. 2. Case 2: A. Multiplanar view + VCI-C. Pivot point is placed in the anal area (white arrow); B. Multiplanar view + VCI-C. Pivot point is placed on the hyperechogenic structure – stool (coarse arrow with white hem) C. B plane image of female genitalia (thin white arrows) and suspicious structure in the genitoanal region (coarse black arrow with white hem). D. B plane image suspicious structure in genitoanal region (coarse black arrow with white hem). E, F surface rendering of the genitoanal region depicting female genitalia (thin white arrows) and fetal defecation (black coarse arrow with white hem).

of the rectal content via anus into the amniotic fluid. The anus was displayed in the perineal area where it is possible to visualize the external anal sphincter. Harmonic tissue imaging was used in combination with color Doppler imaging using low velocities (15 cm/s). Defecation was noted in each examined fetus, even in the early stage of pregnancy, this means that defecation

begins before the 15th gestational week and continues during the whole intrauterine period with a different frequency.

The process of defecation in the early stage of pregnancy is related to the development of neuron terminations in the fetal anus which occurs approximately up to the 22nd gestational week.

Between the 14th to 20 weeks the external sphincter is under a primitive neurological control. During fetal quiescence as well as during motion the fetus keeps a stable tone /relaxed opened anus/ a it's excessive dilatation is noted only during a few seconds. After the 20th gestational week the neurological command of the external sphincter increases and the anus rests usually closed during motion and quiescence and closes even after defecation that accompanies fetal movements.

Fetal defecation was most frequent before 20 weeks and between 28th and 34th gestational weeks when the sphincter's activity was in accord with fetal movements. Towards the end of pregnancy and during term of delivery the intervals between defecations were longer and the fetus defecated only small amounts of meconium (Ramon y Cajal 2003). Fetal defecation is thus a physiological process typical for the normal intrauterine fetal period and participates on amniotic fluid circulation together with other physiological functions (Kimble *et al.* 1999; Ramon y Cajal *et al.* 2003).

DIFERENTIAL DIAGNOSIS OF FETAL DEFECACTION

Due to the small number of studies and scientific papers discussing the process of human fetal defecation it is possible that this physiological process remains easily not observed even during a routine pregnancy ultrasound scan and is the reason of misleading diagnosis and consecutive management of pregnancy.

Within the differential diagnosis sacrococcygeal teratoma, different forms of spinal dysraphia (spina bifida aperta, occulta) a the so called human tail arise. Sacrococcygeal teratoma is a congenital tumor, usually benign, evolving from germinative cell of all three embryonal layers, localised in the sacral or presacral area, close to the coccygis. It belongs to the most frequent tumor of the neonatal period with a prevalence of 0.25–0.28/1000 live births. Regarding the localisation it is classified into four types (type I – predominantly external localisation with a minimal presacral portion, typ II – tumor localised externally with a significant intrapelvic portion, typ. III – tumor with a external portion and dominant pelvic mass expanding into the abdominal cavity, typ IV – presacral tumor with no external portion). Today it is possible to diagnose most cases prenatally with the aid of ultrasound.

Most frequently, a heterogenous mass of tissue with a solid or cystic component, well demarcated, localised externally in the sacrococcygeal area or completely in the presacral region containing only a cystic component, can be observed. Fetal prognosis correlates with tumor size and situs, growth rate, gestational age at which the tumor appears evident, the presence or absence of placentomegaly, cardiomegaly and or fetal hydrops, presence of oligo/polyhydramnios or associated foetal anomalies, including anorectal and genital malformations (rectouretral fistula, anal and rectal aplasia,

hypospadia, scrotal dysraphia, spinal dysraphia, sacral agenesis, rib dislocation, meningocele, heart defects , gastrointestinal and other congenital anomalies.

A relatively high perinatal/neonatal mortality and morbidity is caused by a higher incidence of pre-term delivery and presence of accompanying complications such as malignant invasion, tumor hemorrhagia, umbilical cord obstruction, heart failure, fetal hydrops and urinary tract obstruction that we can diagnose and treat prenatally (Tuladhar *et al.* 2000). Diferential diagnosis comprises myelomeningocele, lipoma, hydromelia, intracanalicular epidermoid tumors, dermal sinus, extrarenal Wilm's tumor, retrorectal hamartoma, neuroblastoma and pacinoma.

Currently cases of neural tube defects should not be undiagnosed prenatally. The common marker of opened defects is the absence of intact overlying skin and therefore increased levels of alfa-fetoprotein. Myelomeningocele and myelocele represent this group. The ultrasound examination reveals an interruption of the dorsal part of vertebral arches and skin as well as associated anomalies in the skull and brain (Chiari malformation type II). Spinal defects with an intact skin layer are more difficult to diagnose prenatally. They can be divided in two types: occult and cystical. Prenatally during a thorough scan, thanks to a dorsal bulging of soft tissues in the lumbar and sacral region, we are capable of diagnosing only the cystic type of spinal dysraphia. Lipomyelomeningocele, myelocystocele and a simple meningocele belong to this group of defects.

Occult spinal dysraphia includes a large group of anomalies that do not display a bulging of the spine's contour and are difficult to be diagnosed prenatally by ultrasound. In this area we can observe different stigmata of the skin. For example diastematomyelia, neuroenteral cyst, dorsal dermal sinus, coarse filum terminale, intradermal lipoma, syndrome of caudal regression, anterior or lateral meningocele, Currarin's trias. The human tail belongs to rare abnormalities, possible to diagnose prenatally. A real human tail and pseudo-tail can be distinguished. The real persistent tail derives from the most distal part of the remaining embryonal tail. It is composed of fatty, connective tissue, a central part of skeletal striated muscle, vessels and nerves and is covered with skin. Bone, cartilage, notochord and spinal cord is absent. It's origin are structures normally present during the fetal stage. The length is up to 13 cm, it can move and contract and is more frequent in males than females. Familiar occurrence is rare. Surgical removal is easy without residual consequences. Protrusion of the lumbosacral and sacrococcygeal area can present itself as a pseudo-tail, remaining part of the tail. Most often elongated coccygeal vertebrae, lipomas, teratomas, chondromegalia, gliomas or a elongated parasitic fetus are concerned (Dao *et al.* 1984). Tail like structures are associated in 50% of cases with different forms of occult spinal dysraphia. Regarding the mentioned facts it is necessary in the differential diagnosis

to consider not only serious but improbable diagnosis, but also the physiological process of defecation that we can distinguish from other diagnosis by a simple repetition of the ultrasound examination within several minutes. Exact and fast diagnosis can be achieved by 3D ultrasound by placing the pivot point in the multiplanar view gradually within the whole spine length down to the anus and with a consecutive rendering of the area the continuity between the anus and stool can be visualized thus excluding other above mentioned congenital anomalies.

ACKNOWLEDGEMENTS

This work was supported project VEGA 1/0678/15.

REFERENCES

- 1 Ciftci AO, Tanyel FC, Bingol-Kologlu M, Sahin S, Buyukpamakcu N. (1999). Fetal distress does not affect in utero defecation but does impair the clearance of amniotic fluid. *J Pediatr Surg.* **34**: 246–250.
- 2 Dao AH, Netsky MG. (1984). Human tails and pseudotails. *Hum Pathol.* **15**: 449–453.
- 3 Desmond MM, Moore J, Lindley JE, Brown CA. (1957). Meconium staining of the amniotic fluid. A marker of fetal hypoxia. *Obstet Gynecol.* **9**: 91–103.
- 4 Kimble RM, Trudenger B, Cass D. (1999). Fetal defecation: is it a normal physiological process? *J Pediatr Child Health* **35**: 116–119.
- 5 Ramón y Cajal CL, Martínez RO. (2003). Defecation in utero: a physiologic fetal function. *Am J Obstet Gynecol.* **188**: 153–156.
- 6 Ramón y Cajal CL, Martínez RO. (2004). In-utero defecation between weeks 14 and 22 of gestation: stools are whitish. *Ultrasound Obstet Gynecol.* **23**: 93–95.
- 7 Tuladhar R, Patole SK, Whitehall JS. (2000). Review: Sacrococccygeal teratoma in the perinatal period. *Postgrad Med J.* **76**: 754–759.