

Mechano-transduction effect of shockwaves in the treatment of lumbar facet joint pain: Comparative effectiveness evaluation of shockwave therapy, steroid injections and radiofrequency medial branch neurotomy

Tomas NEDELKA^{1,2,3}, Jiri NEDELKA², Jakub SCHLENKER³, Christopher HANKINS⁴, Radim MAZANEC¹

1 Charles University in Prague, 2nd Faculty of Medicine, Department of Neurology, Prague, Czech Republic

2 Center for Rehabilitation and Treatment of Spine Pain, Prague, Czech Republic

3 Czech Technical University, Faculty of Biomedical Engineering, Kladno, Czech Republic

4 Bridgeland Sport and Spine Center, Calgary, Canada

Correspondence to: Tomas Nedelka, MD.
Department of Neurology,
2nd Faculty of Medicine and Motol Faculty Hospital, Charles University in Prague
V Úvalu 84, Prague 5, 150 03, Prague, Czech Republic.
E-MAIL: tnedelka@post.cz

Submitted: 2014-06-11 Accepted: 2014-07-11 Published online: 2014-09-28

Key words: facet joint; shockwave therapy; arthrosis; radiofrequency; neuromodulation; medial branch neurotomy

Neuroendocrinol Lett 2014; 35(5):393–397 PMID: 25275264 NEL350514A04 © 2014 Neuroendocrinology Letters • www.nel.edu

Abstract

OBJECTIVE: Lumbar facet joints (FJ) is a common source of low back pain and contributes approximately on one third of chronic low back pain. Medial branch radiofrequency neurotomy is considered as a gold standard in the treatment of facet joint pain. Corticosteroid injections have also presented effect in FJ pain. As an interventional procedures, they carry not-negligible risk of possible complications including infection, damage to nerve root or medial branch structures. Shockwave therapy (SWT) is a non-invasive method for treatment of various musculoskeletal disorders. Its effect is based on transduction of mechanical energy, transferred to cascade of various biochemical processes in target tissue. Its efficacy was proved in the treatment of different painful conditions. The efficacy of SWT was not yet studied in FJ pain. Aim of our work was to compare the efficacy of SWT against interventional treatment procedures – radiofrequency neurotomy and corticosteroid FJ injections. **METHODS:** A retrospective study was done on 62 selected patients with unilateral chronic lumbar facet pain. There were 32 women and 30 men, divided into SWT group, corticosteroid injections group radiofrequency group. Nociceptive and neuropathic pain intensity and severity of pain were measured. **RESULTS:** Shockwave therapy had shown better longterm results compared to FJ injections group and little inferior efficacy compared to RMBN. We did not observe any adverse effects and complications in SWT group. Moreover, in SWT and RMBN groups, significant longterm improvement in daily activities limitation, was observed. **CONCLUSIONS:** SWT appears to be a safe and perspective option in the treatment of FJ pain with negligible side effects.

INTRODUCTION

A motion segment of lumbar spine consists of intervertebral disc and 2 facet (zygoapophyseal) joints with ligaments and muscular tissue. Traditionally, pain of neuropathic origin in this area is correlated mainly with radiculopathy, which is caused by nerve root compression, most often cause is disc prolapse or foraminal stenosis originated by chondral plate degeneration and spurs in affected facet joints. Facet joints (FJ) may likewise play their role in local neuropathic pain development, usually combined with nociceptive component (Freyenhagen & Baron 2009; Nedelka *et al.* 2011). Overloaded FJ, as they bear more than 20% of weight of upper trunk, are subject to degeneration, destruction of chondral plate and development of spurs and calcifications (Selby & Paris 1981), leading to inflammatory cascade in joints and surrounding soft tissues. This may develop in painful vicious circle of neurogenic inflammation and/or mechanical compression of a medial branch of dorsal nerve root. Some authors also suspect lumbar facet joint meniscoids in role of pain development with good responses to spinal manipulations, however, their role in pain development still remains controversial (Jones *et al.* 1989). Progressive FJ degeneration is not only an issue of elder population, but also of young active individuals with predisposition in lumbar spine overloading – heavy manually working persons, professional sportsmen with excessive axial lower back overloading, such as hockey players, athletes, weightlifters and wrestlers. Prevalence of chronic low back pain of FJ origin is very high and according to literature, it contributes on 31% of chronic low back pain (Manchikanti *et al.* 2002). Lumbar Facet joint syndrome, which was originally described 80 years ago (Ghormley 1933), is characterized by localized axial pain, elicited by hyperextension or rotation in lumbar area, with typical referred pain to the buttocks and posterior or anterolateral thigh. Patients never describe pain irradiation below knee (Marks, 1989). Sometimes, patients suffer from neuropathic sensation in mentioned regions – such as numbness, paresthesias or allodynia, and, more rarely, from trophic changes, or hair loss (Fukui 1997).

Diagnostic methods in lumbar FJ pain outcomes mainly from clinical examination. Most important clinical criterion is pain relief after guided injection of local anesthetics is administered around painful FJ, or the medial branch respectively (Cohen & Raja 2007, Datta *et al.* 2009). Imaging methods such as MRI or CT have only additive value and they are not specific. We use them mainly to exclude other spinal pathologies such as disc herniation, nerve root compression, spinal stenosis or mass lesions within the spinal canal. Bone scintigraphy and single-photon emission computed tomography may offer additional information about inflammatory activity around affected FJ (Pneumatics *et al.* 2006; Khazim *et al.* 2010).

Therapeutical approaches in FJ pain include FJ Intraarticular Injections with limited evidence III, medial branch anaesthetic block with level of evidence II-1 or II-2 (Datta *et al.* 2009) with shorter term pain relief and Radiofrequency Medial Branch Neurotomy (RMBN), considered as a gold standard in lumbar FJ pain with longer lasting analgesic effect (6 months to 2 years), with level of evidence II-1 (Manchikanti *et al.* 2002). Various types of guidance are used for accurate needle placement (Peh 2011).

However, both steroid injections and RMBN are percutaneous interventional procedures and may carry non-negligible risk of complications such as pyogenic infections (Muffollero *et al.* 2001), chemical meningitis (Berrigan 1992), bleeding (Raj *et al.* 2004) and rare but possible damage to neural structures. In mild cases, multifidus muscle atrophy was presented (Dreyfuss *et al.* 2009). In case of inappropriate needle or electrode placement, sensory or motor loss due to nerve root damage was also described (Kornick *et al.* 2004).

Other treatment options of FJ pain may contain pharmacological treatment – 3rd generation anticonvulsant pregabalin, NSAID and/or opioids. Certain rehabilitation techniques (Nedelka *et al.* 2014) or spinal manipulations may have additive positive effect when combined with intervention techniques described above.

According to literature and to our own experience, treatment of different painful conditions with shockwave therapy (SWT) is considered to be safe and effective approach in variety of bone, joint and tendon indications. SWT is non-invasive type of physical treatment, originally derived from extracorporeal shockwave lithotripsy, primarily used for kidney stones disintegration. Either supersonic (focused shockwave therapy) and subsonic acoustic pulses (radial shockwave therapy) may interact with target tissue. Shockwaves that are generated for focused and radial SWT have very different physical characteristics. It is unclear how these characteristics are related to clinical effectiveness. Studies into the biological effects of SWT have mainly used focused shockwave therapy, showing a number of effects of shockwaves on biological tissue. Effect of SWT is created by direct mechanical load on structure, which can be used in disintegration of calcifying processes, such as heel spur and shoulder calcifying tendonitis. Biological effect of SWT was observed in tendon tissue healing (Wang 2012, van der Worp *et al.* 2013), cartilage repair (Wang *et al.* 2012), osteogenesis (Quin *et al.* 2010) and pain modulation (Murata *et al.* 2006). SWT has also shown improvement in motor function and pain in animal model of osteoarthritis (Ochiai *et al.* 2007). Complex interaction between mechanical load and musculoskeletal tissue response is sometimes described as mechanotransduction (Jalouk & Lammerding 2009).

In conformity with those studies, similar pathophysiological principles such as arthritis, chondral plate

damage and degeneration, plays its important role also in FJ pain development.

Moreover, in some animal and *in vitro* studies, authors investigated direct effect of SWT application also on neural structures. Murata *et al.* 2006, studied expression of activating transcription factor 3 (ATF3) and growth-associated phosphoprotein (GAP-43) as markers for nerve injury and axonal regeneration in experimental rat. In conclusion, the SWT application can lead to desensitisation of exposure area. In very interesting recent paper (Mense *et al.* 2013) significant improvement in nerve regeneration was observed in a rodent model of nerve compression using low energy SWT.

THE AIM OF THE STUDY

With regards to above mentioned facts, we decided to conduct a pilot clinical trial evaluating the efficacy of SWT against standard treatment options of FJ pain – medial branch anaesthetic block and radiofrequency neurotomy in patients suffering from chronic lumbar unilateral facet joint pain.

STUDY OBJECTIVE, INCLUSION AND EXCLUSION CRITERIA

A pilot retrospective study comparing effectiveness of shockwave therapy (SWT), guided steroid FJ injections and RMBN was conducted in 62 patients fulfilling diagnostic criteria for chronic unilateral lumbar facet joint pain, lasting for minimum of 3 months. Inclusion criterion was positive response to diagnostic, ultrasound-guided local anesthesia (5 ml 1% trimecaine) medial branch block (Gofeld *et al.* 2012). Pain decrease to fulfill its efficacy was higher than 50% of baseline value in visual analog scale (VAS) (Van Zundert *et al.* 2012). This procedure was performed at least for 3 weeks before therapeutic interventions were applied.

Exclusion criteria contained clinical signs of radiculopathy, presence of sensory loss, motor weakness or electromyography (EMG) abnormalities. Excluded were patients, where MRI revealed nerve root compression, spondylolisthesis, tumours in spinal canal and spinal stenosis.

As the depth of application of our radial device is limited to 4–6 cm in its maximum, we also excluded all patients with body mass index (BMI) > 28 and patients with facet joint depth higher than 6 cm, measured from MRI with remeasurement from ultrasound images just before the application.

METHODS

Study was performed in 62 selected patients with unilateral chronic lumbar facet pain, responding to anesthetic facet joint injection. There were 32 women and 30 men enrolled in our study. Each patient was thor-

oughly examined by clinical neurologist and specialist in rehabilitation and physical medicine including proper check of spine range of motion, presence of muscle spasms and trigger points, motor function, deep tendon reflexes on upper and lower limbs, tactile (filament) and vibration tests. We have conducted electromyography conduction studies in all patients included in our study.

In all 62 patients, we have provided MRI examination of lower back and 28 of patients (10 in SWT group, 10 in RMBN group and 8 in FJ injections group) had a ^{99m}Tc bone scan of their lower back.

As the innervation of facet joints comes from 2 segments (ascending and descending fibers of medial branch), we have decided to apply all of the procedures in 2 segments – in affected medial branch and the segment above. In example, when the affected FJ was L4/5, we applied therapy to L3/4 and L4/5 medial branch.

The pain intensity was measured by standard VAS measurement tool before the treatment, after 2, 6 and 12 months follow-up. We have also rated the severity of low back pain using the Oswestry low back pain validated score before the therapy started and after 12 months follow-up. We have used PainDETECT validated questionnaire for measurement of neuropathic pain.

In statistical analysis, as multiple data and groups were compared, ANOVA tests were used (Freedman *et al.* 2007).

SWT group (group A) contained 21 patients. SWT was performed using Storz Duolith SD-1 T-top device with radial method, using titanium DPI-15 applicator with penetration depth 3 to 6 cm, energy level was set to 3.8 bars (energy flux density approx. 0.12 mJ/mm²). Procedure was applied in 5 weekly sessions with 3 000 shocks per session with initial ultrasound guidance to set the correct angle of applicator head (Figure 1).

FJ injection (Group B) contained 20 patients. In each patient, single injection of 6 ml 1% trimecaine and

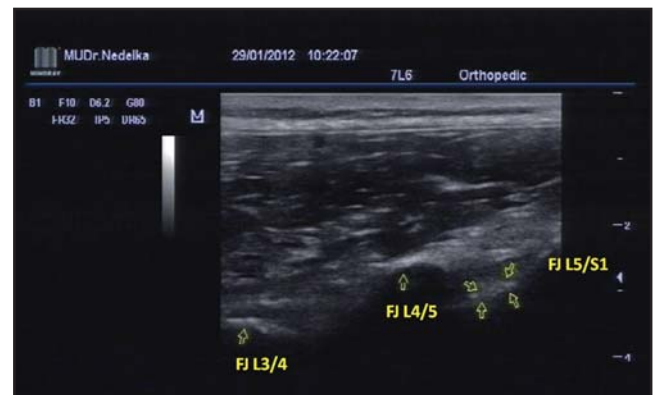

Fig. 1. Inplane ultrasound visualisation of lumbar facet joint. Linear probe, 5 MHz, focus depth set to 30 mm. FJ – corresponding facet joints. 4 arrows on the right side point at the nerve root, with typical „honeycomb” appearance (image from author’s archive).

7 mg of betamethazone was applied to superior articular process of facet joint under US (Mindray Industries DC3, linear probe 5 cm, 5 MHz) and fluoroscopic C-arm guidance (Philips X-ray portable C-arm system, BV Endura).

RMBN (Group C) contained 20 patients, RMBN was performed (K-C radiofrequency pain management pulsed RF generator). Ultrasound and fluoroscopic guidance as well as electrophysiological stimulation was performed for correct placement of electrodes within the medial branch of dorsal nerve root near the superior articular process of facet joint. Pulsed radiofrequency needle tip temperature was set to 42 °C.

There were no complications of SWT procedure. In 2 RMBN and 1 FJ injections patients, temporary increase in pain (more than 3 cm in VAS) was reported in 3 days to 4 weeks period with a need of oral pain killers application (tramadol/paracetamol combined treatment).

RESULTS

The data from all 62 patients were collected. Pre-treatment average visual analogue scale (VAS) mean value was 5.6 cm in group A, 5.0 in group B and 5.2 in group C, respectively (Figure 2).

At 2 months follow up, we registered significant decrease in average VAS against the baseline value in all 3 groups ($p=0.03$ in group A, $p=0.02$ in group B and $p=0.007$ in group C).

After 6 months, SWT (group A, $p=0.02$) and RMBN (group C, $p=0.009$) showed significant changes in average VAS against the baseline, FJ injections group B, however revealed increase in average pain with non-significant results against baseline VAS ($p=0.08$). After 12 months follow-up, there were still significant differ-

ences in group A ($p=0.04$) and group C ($p=0.01$) in comparison to initial values. Oswestry low back pain score was improved in all groups after 2 and 6 months, and in group A and C after one year follow-up (Figure 3).

Neuropathic pain sometimes occurs in patients suffering from FJ pain, localized mainly into lumbar area or buttocks. PainDETECT neuropathic pain questionnaire (Freyenhagen *et al.* 2006) was used for quantification of neuropathic pain clinical signs (irradiating pain, itchy, dull pain, paresthesias, numbness). In our study, 18 patients from 62 presented certain neuropathic pain symptoms. Among those individuals, significant change ($p<0.05$) in SWT and FJ injections group was found in 2 month follow-up only. In contrast, decrease in PainDETECT score was observed at 2, 6 and 12 months follow-up in RMBN group.

DISCUSSION

Different biological aspect of either radial and focused SWT and their clinical outcomes through different diagnoses still remains inconsistent and clear mechanism of therapeutic effect of SWT is unknown. However, the majority of published papers have shown positive and beneficial effects of using SWT as a treatment for variety of musculoskeletal disorders, with high success rate, while the complications are low or negligible (Ioppolo *et al.* 2014).

In our study, we demonstrated, that SWT had shown better longterm pain relief compared to FJ injections group and little inferior efficacy compared to RMBN. Results in RMBN confirm those in previous studies (Cohen & Raja 2007). Moreover, in SWT and RMBN groups, significant longterm improvement in daily activities limitation, caused by chronic low back pain,

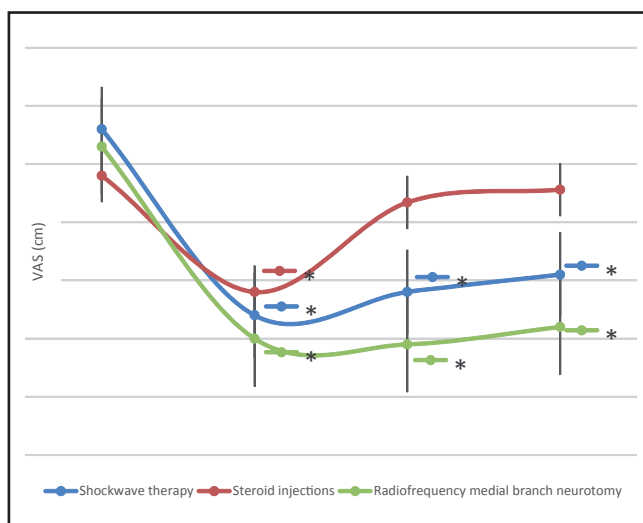


Fig. 2. VAS (cm) values comparison between SWT, FJ medial branch injections and RMBN at baseline, 2, 6 and 12 months follow-up. Mean, maximum and minimal values for each parameter are stated graphically. Significant results ($p<0.05$) marked with *.

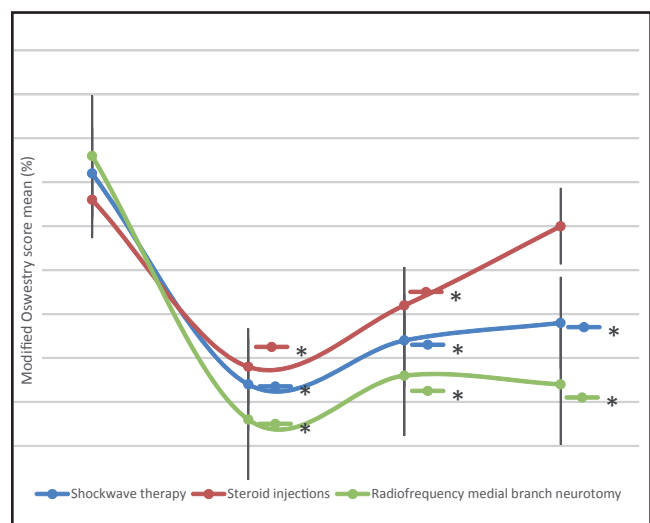


Fig. 3. Modified Oswestry score (%) values comparison between SWT, FJ medial branch injections and RMBN at baseline, 2, 6 and 12 months follow-up. Mean, maximum and minimal values for each parameter are stated graphically. Significant results ($p<0.05$) marked with *.

was observed. We did not encounter any serious adverse effects in SWT group.

Our results show clear improvement in the pain of nociceptive origin. However, in neuropathic pain, no significant longterm changes in its severity were observed in SWT group, although there was obvious longterm decrease of neuropathic pain in RMBN group.

Albeit we used radial SWT generator with deeper penetration and optimal shockwave dispersion, pressure dampening in more superficial tissues and radial characteristic of shockwaves may have caused limitations to energy flux density levels in deep structures of lumbar spine. As a response to this fact, we currently conduct a prospective, placebo (sham device) controlled study using high energy focused electromagnetic device in lumbar facet joint pain, which may help us to eliminate the restriction of radial SWT in application depth and energy flux density fluctuations. From clinical point of view, we also look forward to new perspectives of SWT and their beneficial effect on peripheral nerve reinnervation, as authors recently reported in experimental nerve lesions (Mense *et al.* 2013).

CONCLUSION

Shockwave therapy had shown reasonable efficacy in treatment of chronic lumbar facet joint pain. Neuropathic pain, however, did not show any changes between baseline and 6 and 12 months follow up in the shockwave group. Further studies including focused SWT are needed to confirm our preliminary results.

REFERENCES

- Berrigan T (1992). Chemical meningism after lumbar facet joint block. *Anesthesia*. **7**: 905–906.
- Cohen SP, Raja SN (2007). Pathogenesis, diagnosis, and treatment of lumbar zygapophysial (facet) joint pain. *Anesthesiology*. **106**(3): 591–614.
- Datta S, Lee M, Falco FJ, Bryce DA, Hayek SM (2009). Systematic assessment of diagnostic accuracy and therapeutic utility of lumbar facet joint interventions. *Pain Physician*. **12**(2): 437–60.
- Dreyfuss P, Stout A, Aprill C, Pollei S, Johnson B, Bogduk N (2009). The significance of multifidus atrophy after successful radiofrequency neurotomy for low back pain. *PM R*. **1**(8): 719–22.
- Freedman DA, Pisani R, Purves R (2007). *Statistics*, 4th edition. W.W. Norton & Company ISBN 978-0-393-92972-0.
- Freyenhagen R, Baron R (2009). The evaluation of neuropathic components in low back pain. *Curr Pain Headache Rep*. **13**(3): 185–90.
- Freyenhagen R, Baron R, Gockel U, Tölle TR (2006). painDETECT: a new screening questionnaire to identify neuropathic components in patients with back pain. *Curr Med Res Opin*. **22**(10): 1911–20.
- Fukui S (1997). Distribution of Referred Pain from the Lumbar Zygapophysial Joints and Dorsal Rami. *The Clinical Journal of Pain*. **13**: 303–307.
- Ghormley RK (1933). Low back pain with special reference to the articular facets, with presentation of an operative procedure. *JAMA*. **101**: 1773–7.
- Gofeld M, Bristow SJ, Chiu S (2012). Ultrasound-guided injection of lumbar zygapophysial joints: an anatomic study with fluoroscopy validation. *Reg Anesth Pain Med*. **37**(2): 228–31.

- Ioppolo F, Rompe JD, Furia JP, Cacchio A (2014). Clinical application of shock wave therapy (SWT) in musculoskeletal disorders. *Eur J Phys Rehabil Med*. **26** [in press].
- Jaalouk DE, Lammerding J (2009). Mechanotransduction gone away. *Nat Rev Mol Cell Biol*. **1**: 63–73.
- Jones TR, James JE, Adams JW, Garcia J, Walker SL, Ellis JP (1989). Lumbar zygapophysial joint meniscoids: evidence of their role in chronic intersegmental hypomobility. *J Manipulative Physiol Ther*. **12**(5): 374–85.
- Khazim R, Zaidan AA, Ravi K, Toma T (2010). Single photon emission computerized tomography (SPECT) scan-positive facet joints and other spinal structures in a hospital-wide population with spinal pain. *Makki D Spine J*. **10**(1): 58–62.
- Kornick CA, Kramarich SS, Lamer TJ, Sitzman BT (2004). Complications of lumbar facet radiofrequency denervation. *Spine*. **29**: 1352–1354.
- Manchikanti L, Boswell MV, Singh V, Pampati V, Damron KS, Beyer CD (2004). Prevalence of facet joint pain in chronic spinal pain of cervical, thoracic, and lumbar regions. *BMC Musculoskelet Disord*. **5**: 15.
- Manchikanti L (2002). Medial Branch Neurotomy – systematic review of the evidence. *Pain Physician*. **5**(4): 405–18.
- Marks R (1989). Distribution of pain provoked from lumbar facet joints and related structures during diagnostic spinal infiltration. *Pain*. **39**: 37–40.
- Mense S, Hoheisel U (2013). Shock wave treatment improves nerve regeneration in the rat. *Muscle Nerve*. **47**(5): 702–10.
- Muffolerro AJ, Nader R, Westmark RM, Nauta HJ, Garges KJ, Hadjipavlou AG (2001). Hematogenous pyogenic facet joint infection of the subaxial cervical spine. A report of two cases and review of the literature. *J Neurosurg Spine*. **95**: 135–138.
- Murata R, Ohtori S, Ochiai N, Takahashi N, Saisu T, Moriya H, Takahashi K, Wada Y (2006). Extracorporeal shockwaves induce the expression of ATF3 and GAP-43 in rat dorsal root ganglion neurons. *Auton Neurosci*. **128**(1–2): 96–100.
- Nedelka T, Nedelka J, Schlenker J, Mazanec R (2011). Neuro-pathic component of chronic low back pain (in Czech). *Neurol. Prax*. **12**: 104–109.
- Nedelka J, Nedelka T (2014). Dynamic Myofascial Treatment (in Czech). *Bolest*. **1**: 22–26.
- Ochiai N, Ohtori S, Sasho T, Nakagawa K, Takahashi K, Takahashi N, Murata R, Takahashi K, Moriya H, Wada Y, Saisu T (2007). Extracorporeal shock wave therapy improves motor dysfunction and pain originating from knee osteoarthritis in rats. *Osteoarthritis Cartilage*. **15**(9): 1093–6.
- Peh WCG (2011). Image-guided facet joint injection. *Biomed Imaging Interv J*. **7**(1).
- Pneumaticos SG, Chatziioannou SN, Hipp JA, Moore WH, Esses SI (2006). Low back pain: prediction of short-term outcome of facet joint injection with bone scintigraphy. *Radiology*. **238**(2): 693–8.
- Qin L, Wang L, Wong MW, Wen C, Wang G, Zhang G, Chan KM, Cheung WH, Leung KS (2010). Osteogenesis induced by extracorporeal shockwave in treatment of delayed osteotendinous junction healing. *J Orthop Res*. **28**(1): 70–6.
- Raj PP, Shah RV, Kay AD, Denaro S, Hoover JM (2004). Bleeding risk in interventional pain practice: Assessment, management, and review of the literature. *Pain Physician*. **7**: 3–52.
- Selby DK, Paris SV (1981). Anatomy of facet joints and its clinical correlation with low back pain. *Contemp Orthop*. **3**: 1097–103.
- Van Zundert J, Vanelderden P, Kessels A, van Kleef M (2012). Radiofrequency treatment of facet-related pain: evidence and controversies. *Curr Pain Headache Rep*. **16**(1): 19–25.
- van der Worp H, van den Akker-Scheek I, van Schie H, Zwerver J (2013). ESWT for tendinopathy: technology and clinical implications. *Knee Surg Sports Traumatol Arthrosc*. **21**(6): 1451–8.
- Wang CJ (2012). Extracorporeal shockwave therapy in musculoskeletal disorders. *J Orthop Surg Res*. **20**: 7–11.
- Wang CJ, Sun YC, Wong T, Hsu SL, Chou WY, Chang HW (2012). Extracorporeal shockwave therapy shows time-dependent chondroprotective effects in osteoarthritis of the knee in rats. *J Surg Res*. **178**(1): 196–205.