

# Complete objective response of oesophageal squamocellular carcinoma to biological treatment

Giuseppe DI BELLA, Mauro MADARENA

1. Fondazione Di Bella, Bologna, Italy
2. "S. Camillo - Forlanini" Hospital, Rome, Italy.

Correspondence to: Giuseppe Di Bella, M.D  
Via Marconi N°51, 40122 Bologna, Italy  
PHONE: ++39 051 239662; 051 230369; - FAX: +39 051 2961238  
E-MAIL: [posta@giuseppedibella.it](mailto:posta@giuseppedibella.it)

Submitted: 2008-11-19 Accepted: 2009-01-22 Published online: 2009-09-12

Key words: **oesophageal carcinoma; remission induction; biological treatment; melatonin; somatostatin**

Neuroendocrinol Lett 2009; 30(3): 312-321 PMID: 19855352 NEL300309C01 © 2009 Neuroendocrinology Letters • [www.nel.edu](http://www.nel.edu)

## Abstract

The synergetic use of Somatostatin, Melatonin, Retinoids, Vitamins C, D<sub>3</sub>, and E, Calcium, sulphated Aminogluco-sides, and minimum doses of cyclophosphamide in a 70-year old male patient with inoperable scarcely differentiated oesophageal carcinoma, has provided, from the beginning of treatment in 1995 to the present date, an excellent quality of life, as well as a cure with functional recovery. This paper discusses the rationale and molecular action mechanisms of the treatment which has a differentiating, apoptotic anti-proliferation effect, preserving and enhancing, unlike chemo- and/or radiotherapy, both the trophic and functional capacity of organs and tissues, and immunity and antitlastic homeostasis. This result confirms the efficacy of this biological multiple treatment (MDB); it is also in line with the positive results already published on the use of MDB in low-grade NHL (66) and in stage 3 or 4 lung carcinomas (53). The MDB, with no need for hospitalisation, no toxicity and without in the least reducing working activity, gradually and slowly reduced, and then eliminated the tumour formation. According to the author, reporting this case is useful in order to call for greater interest in the possibilities offered to oncology by the MDB biological and receptor treatment.

## INTRODUCTION

This case shows complete remission (CR) using biological treatment (MDB) of an oesophageal carcinoma monitored from 1995 to the present date. A list of components of the MDB biological treatment is included, as well as a synthesis of the documentation before and after the MDB treatment.

An extremely synthetic description of the MDB method is given, documenting its scientific basis, molecular biology action mechanisms, clinical response, and favourable toxicology profile.

## Oesophageal carcinoma

The prognosis in patients with oesophageal cancer is unfavourable, with less than 5% surviving longer than 5 years (Harrison). The surgical excision of the whole macroscopically visible neoplastic tissue (total resection) is possible in only 45% of cases and is associated with a relevant percentage of complications and/or mortality.

Long-term survival is achieved only in patients with a tumour involving less than 5 cm of the oesophagus and no obstruction or extra-oesophageal diffusion (T1NoMo). Patients with oesophageal carcinoma seldom meet these criteria; most of them die within ten months of diagnosis. The radiation therapy combination (from 5500 to 6000

**Abbreviations :**

ATRA	– All Trans Retinoic Acid
CCK	– Cholecystokinin
MDB	– Di Bella Method
EGF	– Epidermal Growth Factor
EGFR	– Epidermal Growth Factor Receptor
FGF	– Fibroblastic Growth Factor
G	– Gastrine
GH	– Growth Hormone
GHR	– Growth Hormone Receptor
HGF	– Hepatocyte Growth Factor
IGF1-2	– Insulin-like Growth Factor 1-2
IGFR	– Insulin-like Growth Factor Receptor
MRI	– Magnetic Resonance Imaging
MLT	– Melatonin
NGF	– Nerve Growth Factor
NHL	– Non-Hodgkin's Lymphoma
PDGF	– Platelet-Derived Growth Factor
PET	– Positron Emission Tomography
SST	– Somatostatin
SSTR	– Somatostatin Receptor
TGF	– Transforming Growth Factor
VEGF	– Vascular Endothelial Growth Factor
VIP	– Vasoactive Intestinal Peptide

cGy) with mono or poly-chemotherapy may lead to a noticeable, though temporary, tumour mass reduction, with the downside of substantial toxicity. The randomised clinical studies performed so far, however, do not show the ability of chemo- and/or radiotherapy to significantly increase average survival expectancy.

**CLINICAL CASE****Oesophageal carcinoma (classification: T<sub>4</sub>N<sub>2</sub>M<sub>x</sub>)**

Personal data of the patient: Year of birth: 1924, Sex: M

**ANAMNESIS** — The patient, M.D., aged about 70, started to suffer from dysphagia about three months ago, accompanied by a burning sensation in the retro-sternum region, as well as medium-level pain irradiating throughout the abdominal area, for several minutes and several times during the day. Food refluxes and weight loss (6 kg/3 months), as well as changes in bowel movements – with a tendency to constipation over the last month – were also reported.

**REMOTE ANAMNESIS** – Pleurisy at the age of 10; fracture of the cranial base, right clavicle and right eardrum perforation following a motorcycle accident at the age of 21. Bi-lateral bronchopneumonia at the age of 30, exophthalmus in the left eye caused by hyperthyroidism at 31. Since the age of 50 the patient has been suffering from high blood pressure (180/110 mm/Hg) treated pharmacologically at home.

**INITIAL ROUTINE TESTS:**

**March 2, 1995** – CT ANGIO chest-abdomen scan shows...“wall thickening on the third thoracic oesophagus distal and on the gastric-oesophageal joint with diverticuli. Lymph nodes measuring 1 cm in the pericardial region and in the left gastric area.” Patient

admitted to the III Clinica Chirurgica, Pol. “Umberto I”, Rome. **March 3, 1995** – EGDS performed “... at a 36-cm distance from the top teeth there is a diverticulum with a large neck (biopsy performed) containing food residues...” **March 28, 1995** – histology exam: Scarcely differentiated carcinoma superficially ulcerated. **April 4, 1995** – CT scan (*Fig. 1, Fig. 2*)

**April 19, 1995** – The patient underwent an “exploratory laparotomy” with a view to placing a Port-a-cath which would allow for a continuing perfusion of chemotherapy drugs and also in order to assess the possibility of an endoprosthesis.

The outcome of the operation was palliative and the impossible surgical exeresis of the tumour was ascertained. Report on the exploratory laparotomy:- “..voluminous oesophageal neoplasm ...which also affects the peri-oesophageal tissue and the diaphragm and spreads dropping to the retroperitoneum, to the stomach and pancreas which closely adheres to it. In the mediastinum it is possible to touch and see coarse discharges presumably neoplastic. Many regional and extraregional lymph nodes have increased in volume.” Considering the seriousness of the local, chest-abdominal spread of the disease, the patient's age and general conditions, the decision is taken not to intervene any further.”

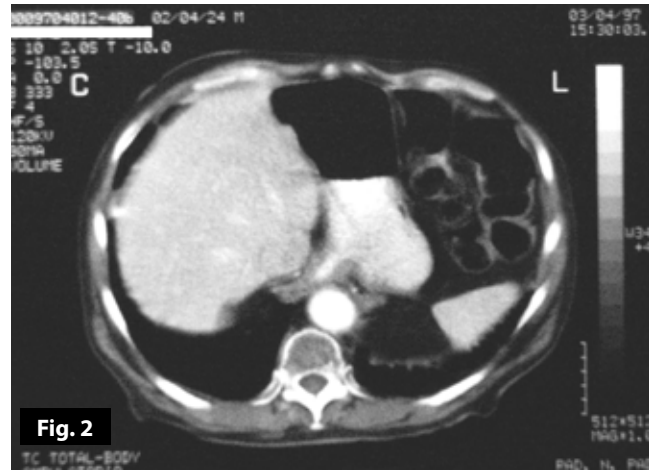
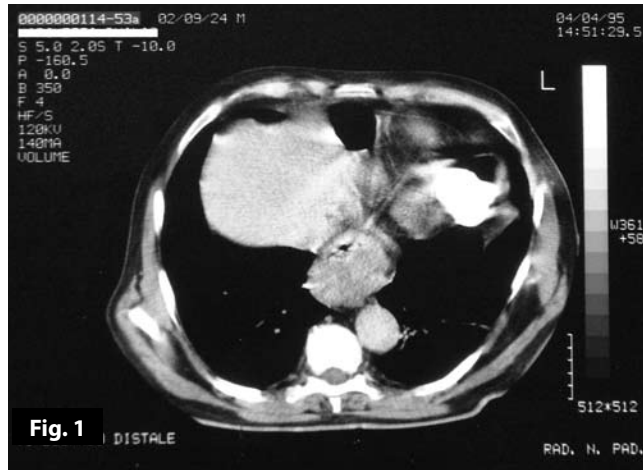
The patient underwent chemotherapy treatment, with a reduction of the assessable mass by about 50% (8 courses of 5 FU + mitomycin – 28 radiotherapy courses).

On October 28, 1995 – the treatment was suspended because of bleeding and melaena; it was not considered possible to repeat the chemotherapy treatments and the patient was discharged with the sole advice of anti-pain and support treatment. Cancer progression.

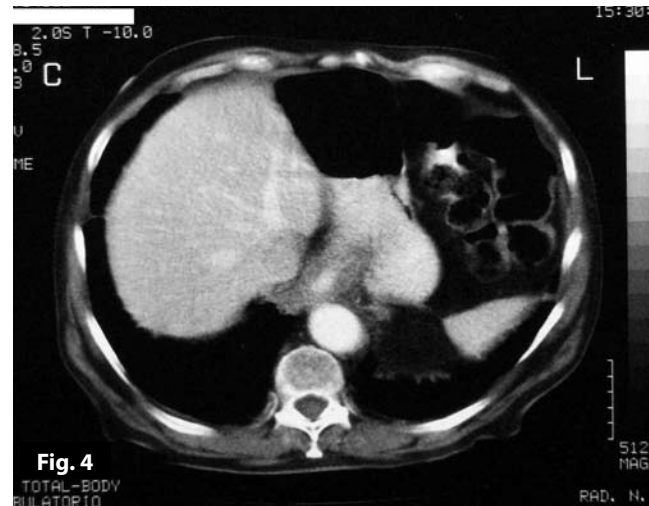
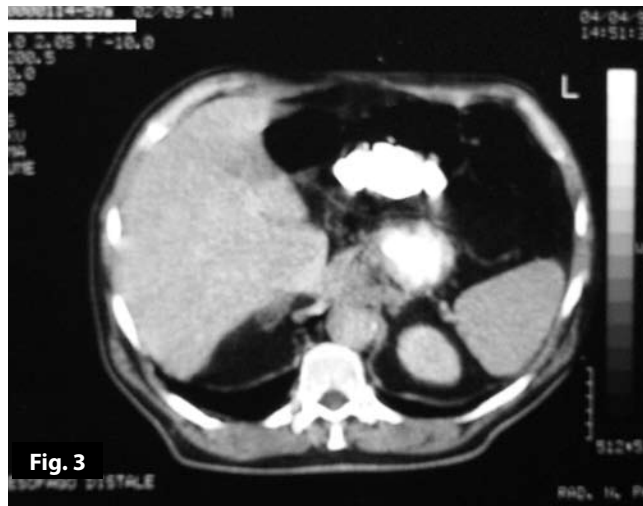
December 1995: cancer progression and start of MDB.

**April 4, 1996**—The patient was admitted because of right basal bronchopneumonia to the “Forlanini” hospital in Rome. Diagnosis of degenerative cardiopathy with minor mitral insufficiency. **May 2, 1996** – The patient was discharged after the necessary treatment. **April 3, 1997** – The CT scan showed an “overall reduction of the thickening on the 3rd oesophageal distal tissue: “... the CT scan of the chest and abdomen performed before and after *iv* iodine contrast medium perfusion, with the volumetric acquisition technique, showed an overall reduction of the irregular thickening of the 3<sup>rd</sup> distal peri-oesophageal tissue, in the supra- and under-cardial region, involving the gastric fundus. The affected area shows a clear enhancement with the iodine contrast medium perfusion...” (*Fig. 3, Fig. 4*)

**October 29, 1997** – **Hospital admission** because of DYSPHAGIA. EGDS + biopsy performed, to assess the possible placing of the prosthesis. REPORT: Negative endoscopic exploration of the proximal oesophagus. On



Figs. 1-2: TC Total Body (1995, Apr. 4) particular.



Figs. 3-4: TC Total Body (1997, Apr. 3) particular.

a supra-cardial level extending below the cardia in the fundus region, an infiltration process is reported with a substantial reduction of the oesophageal lumen and necrotic lesions. Hard consistency of the biopsy sample. The histology exam of the biopsy in the thickened and suspicious supra-cardial area excluded the presence of neoplastic cells. HISTOLOGY: Gastric mucosa with intense acute and chronic inflammation and from fundus ulceration detritus.

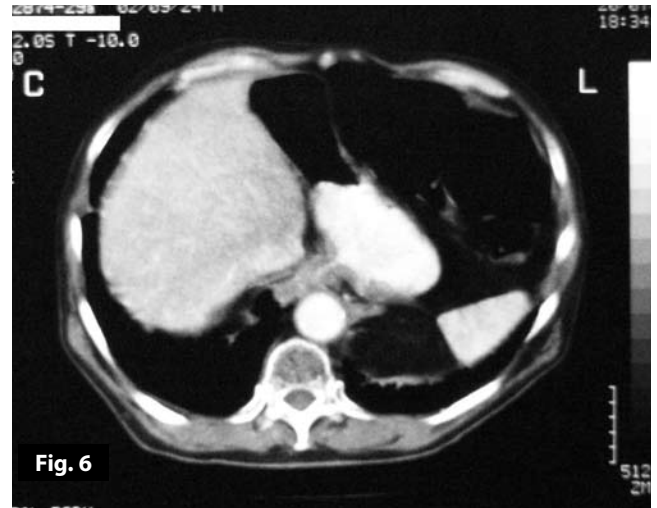
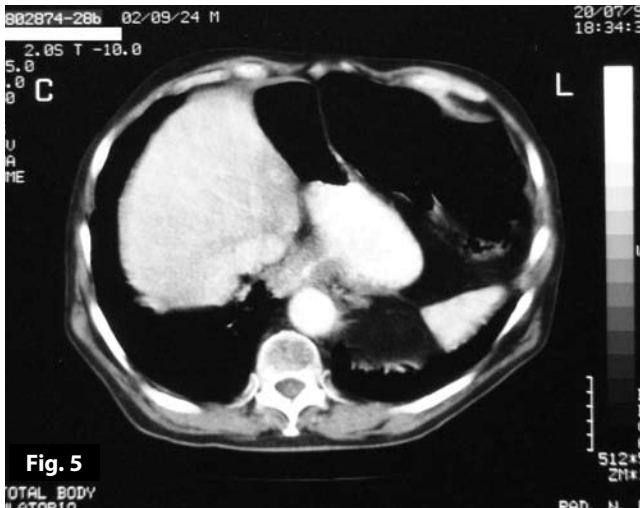**July 20, 1998** – Total Body CT scan performed. CHEST CT SCAN: Exam performed after administering the contrast medium. No clear tomodesitometric alterations of a focal type at the level of the lung parenchyma. Evidence of disventilatory areas in the basal left region; no evidence of clinically relevant lymphadenopathy in the main mediastinum lymph node sites. No pleural effusion. ABDOMEN CT SCAN: The scans performed with volumetric acquisition starting from the third oesophageal distal tissue highlight a thickening of the oesophageal tract examined, with a marked enhancement of the walls, no evidence of the lumen, contact with the wall of the ascending aorta; no evident significant loco-regional lymphadenopathies. (Fig. 5, Fig. 6).

**January 28, 1999** –Total Body CT scan. REPORT: CT CHEST – ABDOMEN AND PELVIS: No signs of tomodesitometric focus lesions. The ventricular system is in axis, not dilated. Parenchyma thickening with slightly blurred margins in the paracardiac rear right locus.

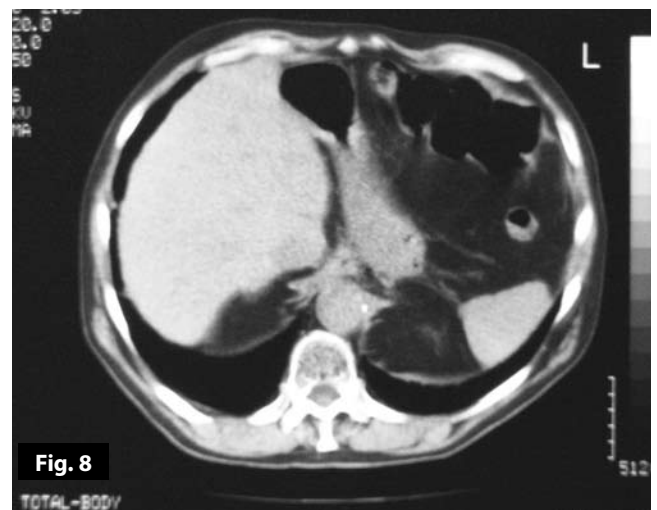
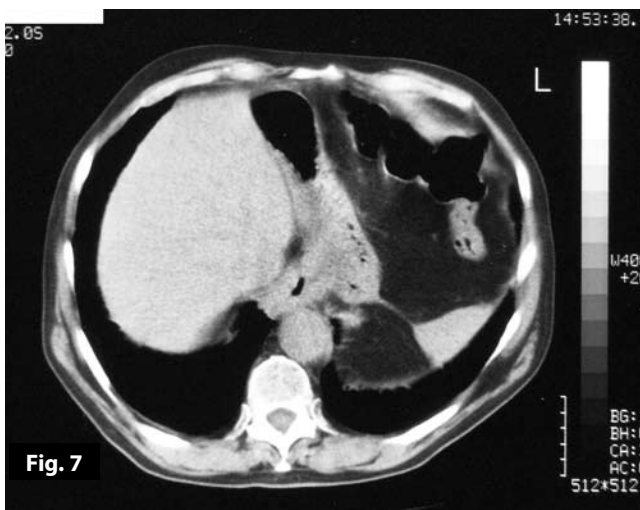
Thickening and lack of homogeneity of the thoracic and trans-diaphragm oesophagus with a strongly blurred and irregular appearance and subsequent reduction of the gut lumen. Increase in density of the perivisceral fat in the tract below the diaphragm. There is evidence of some adenopathies whose Ø is within normal limits in the pre- and retro-carenal azygotic locus.

The study of the liver shows no evidence of tomodesitometric focus lesions in progress. Nothing to report as regards the gallbladder. No significant alterations of the pancreas, in adipose involution. No alterations of the spleen. (Fig. 7, Fig. 8).

**October 1, 2000** – Hospital admission because of MELAENA episodes. Diagnosis: acute haemorrhage and post-haemorrhage acute anaemia. EGDS performed – REPORT: Easy introduction of the endoscopic



Figs. 5-6: TC Total Body (1998, Jul. 20) particular



Figs. 7-8: TC Total Body (1999, Gen. 28) particular

tool. **Negative exploration of the proximal oesophagus.** At the level of the 3rd distal there is narrowing and hypoelasticity of the oesophageal wall across the whole circumference **with no clear infiltration:** it is difficult to proceed and, in the cardial locus on the front wall, a large necrotic lesion of about 2 cm is evident, as already described several times. At the edge of this lesion, only in one point, is a hyperemic mucous area with probable signs of recent bleeding. The gastric cavity is explored, with no evident lesions. Hyperaemia of the duodenal mucosa with discernible contact frailty. There are no signs of bleeding in progress in any part of the explored tract.

#### **PATHOLOGICAL HAEMATO-CHEMICAL VALUES**

RBC 2260000-2900000; Hb 6.6gr% - 9gr%; Hti 20-28%; ESR 50; blood sugar 146; Albuminaemia: 2.95 gr/dl.

The patient underwent blood transfusions (6 units), suspension of oral feeding, treatment with ranitidine *iv* (before) and with omeprazole *po* (after a few days).

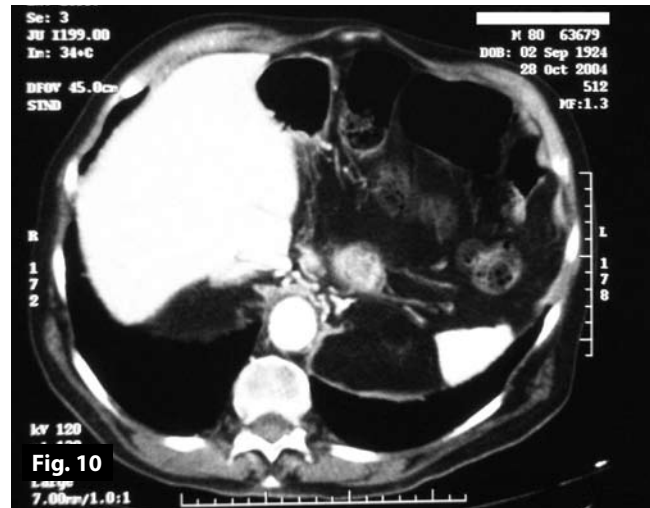
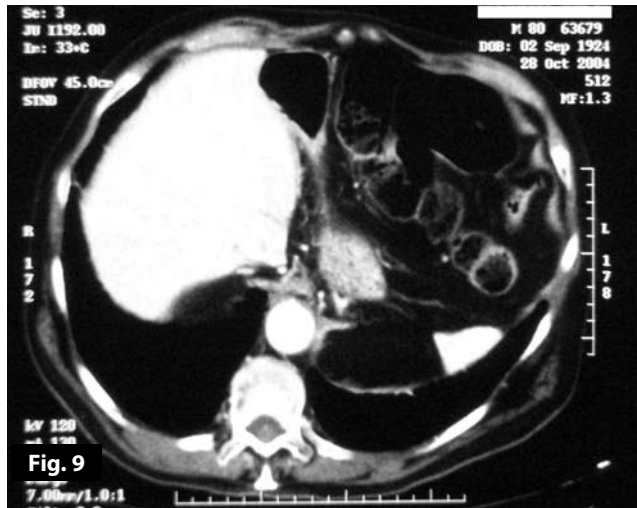
October 9, 2000 - The patient was discharged.

November 15, 2001 - Hospital admission following an epilepsy fit during the night.

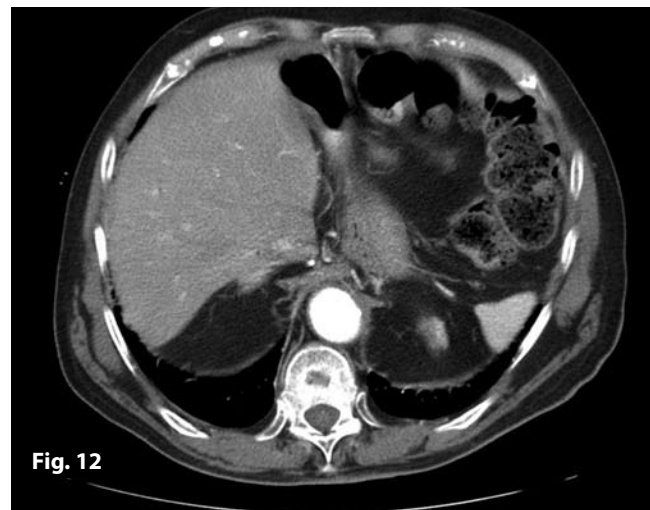
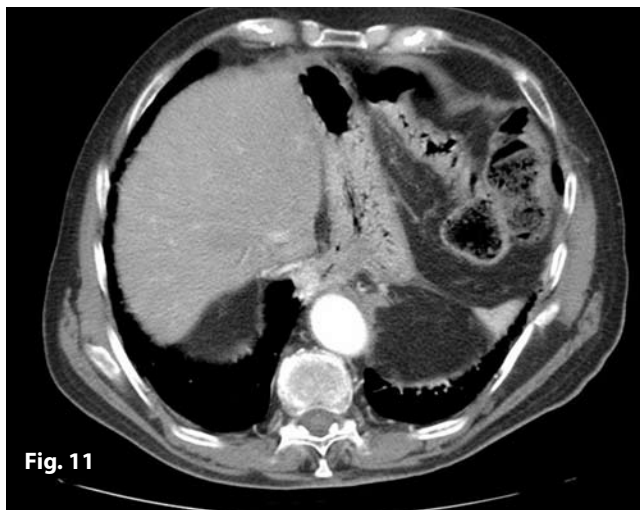
Brain CT scan performed which "... reveals the presence of a small hypo-density area located at the level of the white substance adjacent to the left ventricular crossway, presumably related to outcomes of a lesion on an ischaemic cerebrovascular basis. A small hypo-density area is observed, spreading at the level of the periventricular substance, possibly indicating tissue suffering on a chronic ischaemic cerebrovascular basis. No evidence of haemorrhage injuries."

November 21, 2001 - The patient was discharged.

**October 28, 2004** - Total Body CT scan performed. CHEST: no evidence of nodules and/or lung consolidation areas of a suspicious kind. Pleural left fissure thickening in the basal region with of the left half-diaphragm. No pleural effusion. Fixity with wall concentric thickening of the third distal section of the chest oesophagus and of the oesophageal-gastric joint, essentially unchanged with respect to the previous visual control. No evidence of hilus-mediastinum lymph node tumefaction under the diaphragm. Liver normal in size and



Figs. 9–10: TC Total Body (2004, Oct. 28) particular



Figs. 11–12–13: TC Total Body (2008, Feb. 1) particular

shape, without focal lesions. Biliary tract not dilated. Gallbladder normally distended with normally thick walls. No evident alterations of the spleen, pancreas, adrenal glands or in the right kidney. (Fig. 9, Fig. 10)

**January 17, 2007** – CT Total Body scan performed.

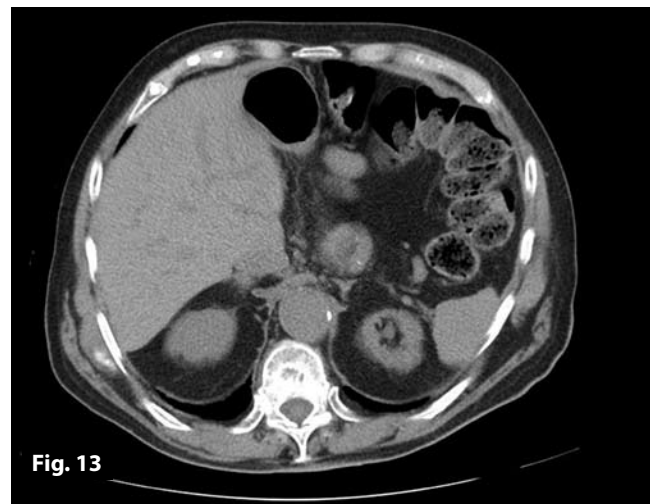
**CHEST:** No evidence of focal alteration of the lung parenchyma. No hilum-mediastinum lymphadenopathies or pleural effusion.

**ABDOMEN AND PELVIS:** Liver size within the limits; parenchyma density with no focal alterations. Biliary tract not dilated; distended gallbladder, with no stones. Portal vein regular in size and patent.

Adrenal glands with regular size and shape. Spleen within the normal limits. Pancreas difficult to define.

Kidneys in locus, reduced cortex-medullary ratio; left kidney cysts, no calicopyelic ectasis.

No evidence of interaorta-caval and lomboortic lymphadenopathies. Bladder symmetrically distended with homogeneously thickened walls (effort bladder?). Hypertrophic prostate not homogeneous in density and with small parenchyma calcifications. No ilium-obturator lymphadenopathies.



**February 1, 2008** – TB complete abdomen CT scan (with/without cm), TB cranial CT scan (with/without cm), TB chest CT scan (with/without cm).

Scan performed before and after contrast medium *iv* injection, using the volumetric multilayer technique.

No alterations of the cerebral parenchyma, with focal characteristics.

Ventricular system in axis with respect to the median line. The cerebral convexity sulci are within the limits. No visible pulmonary parenchyma thickenings or effusions inside the pleura. Basal parenchyma dystelectasias. Centrimetric mediastinum lymph nodes. Enlargement of the ascending aorta (42 mm). Mediastinum organs with regular morphology. No endo-abdominal effusions.

Normal liver in terms of size and structure. No ectasia of the biliary tract inside or outside the liver. Regular portal calibre. No spleen alterations. Normal pancreas in terms of size and structure. Bilateral thinning of the renal parenchyma. Normal elimination through the kidneys of the iodate contrast medium. No pathological lymph nodes with respect to size in the sub-diaphragm loci.

Volumetric increase of the prostate. (*Figs. 11–13*).

The patient is still alive and in good condition, eating without difficulty. The initial treatment has been reduced and the patient is following this pharmacological regime:

*Octreotide Lar* 20 mg – 1 intramuscular injection every 28 days

*Retinoid solutions*: – 1 spoon in the morning on an empty stomach with

*Dihydroxycholesterol* (vit.D<sub>3</sub>) – 9 drops with the retinoids

*Melatonin conjugate* 2mg – 3 tablets after meals, (9 per day)

*Bromocriptine* 2.5 mg – ¼ of a tablet after meals × 3 times a day; as well as:

*Phenobarbital* – ½ tablet (epilepsy fit)

*Enalapril* 20mg – 1 tablet (hypertension)

*Lansoprazole* 30 mg – 1 tablet

*Metoclopramide* 10mg – 1 tablet

*Nitroglycerin* T5 – 1 patch

*Levothyroxine* 100 mg – 1 tablet

## RESULTS

### Therapy and clinical course

The chemoradiotherapy obtained an objective response, though only partial, as regards the voluminous oesophageal neoplasm and peri-oesophageal extension, as well as the diaphragm, retroperitoneum, stomach and pancreas, regional and extra-regional lymph nodes. The local progression then started again and, since it was not possible to proceed with the chemoradiotherapy treatment because of its toxicity and no surgical exeresis was possible, the patient asked to be treated with the Di Bella Method, which involves the synergetic use of molecules with a differentiating, cytostatic, apoptotic, antiangiogenic, antimetastatic action to strengthen immunity and in addition, for apoptotic reasons, minimum doses

(non-cytotoxic, cytolytic and therefore non-mutagenic) of cyclophosphamide. Continuous administration of 100 milligrams per day of cyclophosphamide over a period of approximately 12 months could have proved toxic had it not been for the concomitant administration of MLT, vitamin E, retinoids, and vitamins C and D<sub>3</sub>, which effectively countered toxicity. It did not cause any changes in haemopoiesis or medullar dynamics. The patient followed the therapy at home, with a quality of life which allowed him to gradually restart his working activity in spite of his advanced age.

Drugs administered – components of the prescribed treatment (MDB):

- 1) *Somatostatin* (14 amino acids) (SST), injected under the skin at night over the space of 10 hours with a programmable infusion pump, due to SST short half-life (about 3 minutes) to coincide with the nighttime peak of incretion of GH.
- 2) *Octreotide*, similar to somatostatin (eight amino acids) and lag time formulation, 30 mg intra-muscular every 25 days, for complete receptor and temporal saturation, with the same anti-proliferative and pro-apoptotic objective as the somatostatin.
- 3) *Bromocriptine* 2.5 mg 1½ tablet morning and evening to inhibit prolactin, a powerful and ubiquitous mitogenic hormone.
- 4) *Cabergoline* 1½ tablet twice a week, to reinforce the bromocriptine effects; cabergoline also has a markedly longer half-life.
- 5) Vitamin solution, according to Prof. Di Bella's formula:
 

<i>Beta carotene</i>	2 g
<i>Palmitate axerophthol</i>	0.5 g
<i>All-trans retinoic acid</i>	0.5 g
<i>Alpha-tocopherol</i>	1000 g

 One medium spoonful (100 mg × Kg of body weight), at least 15 minutes before eating, 3 times a day
- 6) *Dihydroxycholesterol* (vitamin D<sub>3</sub> synthesis): 10 drops in the same spoon along with the vitamin compounds (i.e. 30 drops per day)
- 7) *Chemically complexed Melatonin with adenosine* (by means of a hydrogen link) and glycine (according to Prof. Di Bella's formula: 12% melatonin, 51% adenosine, and 37% glycine) 2 mg tablet, 10 per day
- 8) *Calcium* 1 g, 2 times a day with the ascorbic acid
- 9) *Ascorbic Acid* 2 g, along with the calcium in a glass of water, 2 times a day with meals
- 10) *Glucosamine sulfate + Chondroitin sulfate* 1500 mg, 3 times a day
- 11) *Cyclophosphamide* tablets 50 mg, one tablet twice a day;

## DISCUSSION

The biological neuro-immuno-endocrine therapy designed by Prof. Luigi Di Bella (MDB) slowly and gradually obtained a complete objective response, without toxicity, by means of a receptorial, differentiating, apoptotic antiproliferative and antiangiogenic action whose criteria, aims and mechanisms are totally different from the usual cytolytic treatment (the method has thus proved its ability to replace surgery, radiotherapy and chemotherapy, which are known to be unable to eradicate solid tumours). In this case the neoplasm was widely spread outside the oesophagus, with voluminous adenopathies disseminated in the mediastinum and abdominal region; it also extended to the peri-oesophageal, as well as to diaphragm, retro-peritoneum, stomach and pancreas area; a surgical solution was thus excluded. The objective response to the MDB extended to the complete healing of the oesophageal lesion and of its branches.

### Rationale of the Therapy

In pretumoural and tumoural stages of the epithelial cells in general and of the airways-digestive tract in particular (Griffin *et al.* 1987), liposoluble epithelioprotective vitamins play an important therapeutic role (Dong *et al.* 2008, Launoy *et al.* 1998). This effect is decidedly increased by the MDB formulation and doses, in which the antioxidant effect of vitamin E preserves the retinoids from oxidative degradation, prolonging their half-life and efficacy. Dispersion of the solution to its molecular state increases its bioavailability. The high surface tension forms a stable and adherent protective layer on the epithelial surface. Betacarotene, Palmitate axerophthol, All-trans retinoic acid, Alpha-tocopherol-acetate and Dihydrotachysterol intervene on the trophism, functionality and regulation of cell growth in general and on epithelial cells most of all. Their effect, as in the case presented here, is enhanced by the direct contact with the mucosa during transit through the digestive tract.

The loss of differentiation and proliferation, even if to different extents, are common denominators of all neoplasms. The ubiquitous receptor expression of prolactin (Ben-Jonathan *et al.* 2002; Hooghe *et al.* 1998) and GH (De Souza *et al.* 1974, Lincoln *et al.* 1998) are one of the confirmations of the direct and generalized mitostimulating role of this molecule.

Cellular proliferation is highly dependent on prolactin and GH, both being powerful growth factors, and on GH-dependent mitogenic molecules which are positively regulated by it, such as EGF, FGF, HGF, IGF1-2, NGF PDGF, VEGF, and TGF, in addition to growth factors produced by the gastrointestinal tract such as VIP, CCK, and G. Both physiological as well as neoplastic cellular proliferation take place by means of these same molecules, which the neoplastic cells use to an expo-

stantial extent compared to healthy ones. Biological antidotes of GH, such as somatostatin and similar compounds, reduce not only the expression and transcription of highly mitogenic growth factors, such as IGF1-2 (Cascinu *et al.* 2001; Kath & Höffken 2000; Schally *et al.* 2001), EGF (Szepesházi *et al.* 1999), VEGF (Mentlein *et al.* 2001), but extend their negative regulation to the respective receptors with evident anti-proliferative and anti-angiogenic effects (Albini *et al.* 1999; Barnett 2003; Barrie *et al.* 1993; Gruszka *et al.* 2001; Jia *et al.* 2003).

The extent of the GH-IGF1 axis influence on neoplastic biological development is worth noting. The IGFs respond mitogenically to IGF. The suppressive effect of SST and its analogues on the serum levels of IGF1 is both direct, by inhibiting the IGF1 gene, as well as indirect by suppressing GH and thus its hepatic induction of IGF1. Angiogenesis is essential to neoplastic progression. Angiogenesis is in turn regulated by the fall of monocytes, interleukin 8, and by such growth factors as VEGF, TGF, IGF1, FGF, HGF, and PDGF. Each of these factors is negatively regulated by somatostatin and its analogues (Albini *et al.* 1999; Barrie *et al.* 1993; Cascinu *et al.* 2001; Florio *et al.* 2003; Held-Feindt *et al.* 1999; Jia *et al.* 2003; Turner *et al.* 2000; Vidal *et al.* 2000; Watson *et al.* 2001; Wiedermann 1993).

The inhibition of angiogenesis induced by SST is synergistically enhanced by:

*MLT* (Di Bella & Gualano 2006; Di Bella *et al.* 1979; Lissoni *et al.* 2001),  
*retinoids* (Kini *et al.* 2001; Lubin *et al.* 2008; Majewski *et al.* 1994; McMillan *et al.* 1990; Muller *et al.* 1997; Roth *et al.* 1999),  
*vitamin D<sub>3</sub>* (Kisker *et al.* 2003; Mantell *et al.* 2000; Meggouh *et al.* 1990),  
*vitamin E* (Neuzil *et al.* 2002, Odeleye *et al.* 1992a; Shklar & Schwartz 1996; Tang & Meydani 2001),  
*vitamin C* (Ashino *et al.* 2003),  
*prolactin inhibitors* (Turner *et al.* 2000), and  
*components of the extra-cellular matrix* (Liu *et al.* 1998; Ozerdem *et al.* 2004; Wang *et al.* 1996).

Likewise, the cytostatic, anti-proliferative, and antimetastatic effect of somatostatin is effectively synergized by MDB's other components:

*Retinoids* (Hashimoto *et al.* 2003; Khuri *et al.* 2001; Lotan 1997; Onogi *et al.* 1998; Piedrafita & Pfahl 1997; Shimizu *et al.* 2004; Wang *et al.* 1999)  
*MLT* (Jatoi & Thomas 2002; Kvetnoy & Levin 1986; Maestroni *et al.* 1996)  
*Vitamin D<sub>3</sub>* (Barroga *et al.* 2000; Giovannucci *et al.* 2006; Jensen *et al.* 2001)  
*Cabergoline and Bromocriptine* (prolactin inhibitors) (Ben-Jonathan *et al.* 2002; Gruszka *et al.* 2001)  
*Glucosamine sulphate, Galactosamine sulphate, components of the extra-cellular matrix* (Batra *et al.* 1997; Kidd 2000; Liu *et al.* 2005; Mikami *et al.* 2001; Pumphrey *et al.* 2002)

Vitamin E (Malafa *et al.* 2002; Neuzil *et al.* 2002; Odeleye *et al.* 1992; Turley *et al.* 1995)

Vitamin C (Cameron *et al.* 1979; Head 1998, Murata *et al.* 1982)

The causal relationship between GH's receptor expression and tumor induction and progression has been shown (Lincoln *et al.* 1998), histochemically demonstrating markedly higher concentrations of GHR in tumor tissues compared to physiological tissues, thus showing the powerful mitogenic role of GH with proliferative indices depending on dose. This is direct, via receptors, as well as indirect, by inducing the GH-dependent hepatic expression of IGF1. The GH-IGF1 axis has a decisive role in the biological behavior of many neoplasms. In a very high percentage of neoplastic cells, IGF1 receptors have been identified which respond mitogenically to the Ligand. Somatostatin exerts an antiproliferative effect both directly, by inhibiting the IGF1 gene's expression, as well as indirectly, by suppressing GH, which IGF1's secretion depends on (Schally *et al.* 2001).

Somatostatin's inhibiting activity on EGF, another powerful mitogenic growth factor, with multiple mechanisms, has also been thoroughly documented:

- depending on the dosage, inhibition of tyrosine phosphorylation induced by the activation of EGFR by EGF (Mishima *et al.* 1999);
- reduction of EGFR in tumor cells (Szepesházi *et al.* 1999);
- reduction of EGF's expression (Israel *et al.* 2000);
- reduction of EGF's plasma concentration (Cascinu *et al.* 2001).

Mitogens produced by the gastrointestinal tract such as VIP, CCK, and G are strongly inhibited by somatostatin and/or octreotide (Kath & Höffken 2000).

The efficacy of somatostatin and/or octreotide (Jin *et al.* 2008) is enhanced by a factorial synergic mechanism with MDB's other components (Kapil *et al.* 1993). The literature thus confirms the differentiating anti-neoplastic, anti-proliferative, anti-angiogenic, and anti-metastatic action mechanisms of all MDB components. In the case described here the haematochemical tests did not show any damage, but rather a progressive reduction of prolactin, IGF1, and maintenance of low levels of GH.

The objective result, in the absence of toxicity, through the slow and gradual reduction – achieving complete disappearance – of the extensive initial neoplastic lesions and of the adenopathies, associated with the blocking of any loco-regional progression or dissemination of the metastasis, highlights the effectiveness of this multiple therapy and is in line with the results already published about the use of this method (Todisco *et al.* 2001) in low-grade LNH and lung carcinoma stages 3 and 4 (Norsa *et al.* 2007). The MDB method requires no hospitalisation or even day-hospital

admission and is not toxic. The treatment resulted in the recovery of oesophageal function, trophism and functionality of organs and tissues; after thirteen years, this allowed a physiological and active quality of life until the age of 84.

It is reasonable to conclude, therefore, that the early application of this method as the front-line treatment, in a body not debilitated by the toxic, mutagenic and immunodepressive effects of chemo-radiotherapy, could achieve markedly more rapid results. It is useful to report this case in order to encourage greater interest, study and in-depth analysis of the possibilities offered to oncology by the immunoneuroendocrine, biological and receptorial MDB therapy.

#### REFERENCES

- 1 Albini A, Florio T, Giunciuglio D, *et al.* (1999). Somatostatin controls Kaposi's sarcoma tumor growth through inhibition of angiogenesis. *FASEB J.* **13**(6): 647–655.
- 2 Ashino H, Shimamura M, Nakajima H, *et al.* (2003). Novel function of ascorbic acid as an angiostatic factor. *Angiogenesis.* **6**(4): 259–269.
- 3 Barnett P (2003). Somatostatin and somatostatin receptor physiology. *Endocrine.* **20**(3): 255–264.
- 4 Barrie R, Woltering EA, Hajarizadeh H (1993). Inhibition of angiogenesis by somatostatin and somatostatin-like compounds is structurally dependent. *J Surg Res.* **55**(4): 446–450.
- 5 Barroga EF, Kadosawa T, Okumura M (2000). Inhibitory effects of 22-oxa-calcitriol and all-trans retinoic acid on the growth of a canine osteosarcoma derived cell-line in vivo and its pulmonary metastasis in vivo. *Res Vet Sci.* **68**(1): 79–87.
- 6 Batra RK, Olsen JC, Hoganson DK (1997). Retroviral gene transfer is inhibited by chondroitin sulfate proteoglycans/glycosaminoglycans in malignant pleural effusions. *J Biol Chem.* **272**(18): 11736–43.
- 7 Ben-Jonathan N, Liby K, McFarland M (2002). Prolactin as an autocrine/paracrine growth factor in human cancer. *Trends Endocrinol Metab.* **13**(6):245–250.
- 8 Cameron E, Pauling L, Leibovitz B (1979). Ascorbic acid and cancer: a review. *Cancer Res.* **39**(3): 663–681.
- 9 Cascinu S, Del Ferro E, Ligi M, Staccioli, *et al.* (2001). Inhibition of vascular endothelial growth factor by octreotide in colorectal cancer patients. *Cancer Invest.* **19**(1): 8–12.
- 10 De Souza I, Morgan L, Lewis UL (1974). Growth-hormone dependence among human breast cancers. *Lancet.* **2**(7874):182–184.
- 11 Di Bella L, Gualano L (2006). Key aspects of melatonin physiology: thirty years of research. *Neuro Endocrinol Lett.* **27**(4): 425–432.
- 12 Di Bella L, Rossi MT, Scalera G (1979). Perspectives in pineal functions. *Prog Brain Res.* **52**: 475–478.
- 13 Dong LM, Kristal AR, Peters U (2008). Dietary supplement use and risk of neoplastic progression in esophageal adenocarcinoma: a prospective study. *Nutr Cancer.* Jan-Feb; **60**(1):39–48
- 14 Florio T, Morini M, Villa V, *et al.* (2003). Somatostatin inhibits tumor angiogenesis and growth via somatostatin receptor-3-mediated regulation of endothelial nitric oxide synthase and mitogen-activated protein kinase activities. *Endocrinology.* **144**(4): 1574–1584.
- 15 Giovannucci E, Liu Y, Willett WC (2006). Cancer incidence and mortality and vitamin D in black and white male health professionals. *Cancer Epidemiol Biomarkers Prev.* Dec; **15**(12): 2467–72. Epub Nov 28.
- 16 Griffin M, Sweeney EC (1987). The relationship of endocrine cells, dysplasia and carcinoembryonic antigen in Barrett's mucosa to adenocarcinoma of the oesophagus. *Histopathology.* Jan; **11**(1): 53–62.



- 17 Gruszka A, Pawlikowski M, Kunert-Radek J (2001). Anti-tumoral action of octreotide and bromocriptine on the experimental rat prolactinoma: anti-proliferative and pro-apoptotic effects. *Neuro Endocrinol Lett.* **22**(5): 343–348.
- 18 Hashimoto Y, Shimada Y, Itami A (2003). Growth inhibition through activation of peroxisome proliferator-activated receptor gamma in human oesophageal squamous cell carcinoma. *Eur J Cancer.* Oct; **39**(15): 2239–46.
- 19 Head KA (1998). Ascorbic acid in the prevention and treatment of cancer. *Altern Med Rev.* **3**(3): 174–186.
- 20 Held-Feindt J, Krisch B, Mentlein R (1999). Molecular analysis of the somatostatin receptor subtype 2 in human glioma cells. *Brain Res Mol Brain Res.* **64**(1): 101–7.
- 21 Hooghe R, Merchav S, Gaidano G (1998). A role for growth hormone and prolactin in leukaemia and lymphoma? *Cell Mol Life Sci.* **54**(10): 1095–1101.
- 22 Israel K, Yu W, Sanders BG, Kline K (2000). Vitamin E succinate induces apoptosis in human prostate cancer cells: role for Fas in vitamin E succinate-triggered apoptosis. *Nutr Cancer.* **36**(1): 90–100.
- 23 Jatoi A & Thomas CR Jr (2002). Esophageal cancer and the esophagus: challenges and potential strategies for selective cytoprotection of the tumor-bearing organ during cancer treatment. *Semin Radiat Oncol.* Jan; **12**(1 Suppl 1): 62–7.
- 24 Jensen SS, Madsen MW, Lukas J, Binderup L, Bartek J (2001). Inhibitory effects of 1alpha, 25-dihydroxyvitamin D(3) on the G(1)-S phase-controlling machinery. *Mol Endocrinol.* **15**(8): 1370–1380.
- 25 Jia WD, Xu GL, Xu RN, *et al.* (2003). Octreotide acts as an anti-tumor angiogenesis compound and suppresses tumor growth in nude mice bearing human hepatocellular carcinoma xenografts. *J Cancer Res Clin Oncol.* **129**(6): 327–334.
- 26 Jin Z, Mori Y, Hamilton JP (2008). Hypermethylation of the somatostatin promoter is a common, early event in human esophageal carcinogenesis. *Cancer.* Jan 1; **112**(1): 43–9.
- 27 Kapil U, Srivastav M, Nayar D (1993). Vitamin 'A' and oesophageal cancer. *Trop Gastroenterol.* Jul–Sep; **14**(3): 87–90.
- 28 Kath R & Höffken K (2000). The significance of somatostatin analogues in the antiproliferative treatment of carcinomas. *Recent Results Cancer Res.* **153**: 23–43.
- 29 Khuri FR, Kim ES, Lee JJ (2001). The impact of smoking status, disease stage, and index tumor site on second primary tumor incidence and tumor recurrence in the head and neck retinoid chemoprevention trial. *Cancer Epidemiol Biomarkers Prev.* 2001 Aug; **10**(8): 823–9.
- 30 Kidd PM (2000). The use of mushroom glucans and proteoglycans in cancer treatment. *Altern Med Rev.* Feb; **5**(1): 4–27. Review.
- 31 Kini AR, Peterson LA, Tallman MS, Lingen MW (2001). Angiogenesis in acute promyelocytic leukemia: induction by vascular endothelial growth factor and inhibition by all-trans retinoic acid. *Blood.* **97**(12): 3919–3924.
- 32 Kisker O, Onizuka S, Becker CM, Fannon M, Flynn E, D'Amato R, *et al.* (2003). Vitamin D binding protein-macrophage activating factor (DBP-maf) inhibits angiogenesis and tumor growth in mice. *Neoplasia.* **5**(1): 32–40.
- 33 Kvetnoy IM & Levin IM (1986). Melatonin and tumor growth. (In Russian with English abstract). *Eksp Onkol.* **8**(4): 11–15.
- 34 Launoy G, Milan C, Day NE, Pienkowski MP (1998). Diet and squamous-cell cancer of the oesophagus: a French multicentre case-control study. *Int J Cancer.* Mar 30; **76**(1): 7–12.
- 35 Lincoln DT, Sinowatz F, Temmim-Baker L, *et al.* (1998). Growth hormone receptor expression in the nucleus and cytoplasm of normal and neoplastic cells. *Histochem Cell Biol.* **109**(2): 141–159.
- 36 Lissoni P, Rovelli F, Malugani F, Bucovec R, Conti A, Maestroni GJ (2001). Anti-angiogenic activity of melatonin in advanced cancer patients. *Neuro Endocrinol Lett.* **22**(1): 45–47.
- 37 Liu G, Wu M, Levi G (1998). Inhibition of cancer cell growth by all-trans retinoic acid and its analog N-(4-hydroxyphenyl) retinamide: a possible mechanism of action via regulation of retinoid receptors expression. *Int J Cancer.* Oct 5; **78**(2): 248–54.
- 38 Liu Y, Yang H, Otaka K, Takatsuki H, Sakanishi A (2005). Effects of vascular endothelial growth factor (VEGF) and chondroitin sulfate A on human monocytic THP-1 cell migration. *Colloids Surf B Biointerfaces.* **43**(3–4): 216–220.
- 39 Lotan R (1997). Retinoids and chemoprevention of aerodigestive tract cancers. *Cancer Metastasis Rev.* Sep–Dec; **16**(3–4): 349–56.
- 40 Lubin JH, Virtamo J, Weinstein SJ (2008). Cigarette smoking and cancer: intensity patterns in the alpha-tocopherol, beta-carotene cancer prevention study in Finnish men. *Am J Epidemiol.* Apr 15; **167**(8): 970–5. Epub 2008 Feb 3.
- 41 Maestroni GJ, Hertens E, Galli P, Conti A, Pedrinis E (1996). Melatonin-induced T-helper cell hematopoietic cytokines resembling both interleukin-4 and dymorphin. *J Pineal Res.* **21**(3): 131–9.
- 42 Majewski S, Szmurlo A, Marczak M, Jablonska S, Bollag W (1994). Synergistic effect of retinoids and interferon alpha on tumor-induced angiogenesis: anti-angiogenic effect on HPV-harboring tumor-cell lines. *Int J Cancer.* **57**(1): 81–85.
- 43 Malafa MP, Fokum FD, Smith L, Louis A (2002). Inhibition of angiogenesis and promotion of melanoma dormancy by vitamin E succinate. *Ann Surg Oncol.* **9**(10): 1023–1032.
- 44 Mantell DJ, Owens PE, Bundred NJ, Mawer EB, Canfield AE (2000). 1 alpha, 25-dihydroxyvitamin D(3) inhibits angiogenesis in vitro and in vivo. *Circ Res.* **87**(3): 214–220.
- 45 McMillan K, Perepelitsyn I, Wang Z, Shapshay SM (1999). Tumor growth inhibition and regression induced by photothermal vascular targeting and angiogenesis inhibitor retinoic acid. *Cancer Lett.* **137**(1): 35–44.
- 46 Meggouh F, Lointier P, Pezet D (1990). Evidence of 1,25-dihydroxyvitamin D3-receptors in human digestive mucosa and carcinoma tissue biopsies taken at different levels of the digestive tract, in 152 patients. *J Steroid Biochem.* Jun; **36** (1–2): 143–7.
- 47 Mentlein R, Eichler O, Forstreuter F, Held-Feindt J (2001). Somatostatin inhibits the production of vascular endothelial growth factor in human glioma cells. *Int J Cancer.* **92**(4): 545–550.
- 48 Mikami S, Ohashi K, Usui Y, Nemoto T, Katsube K, Yanagishita M, Nakajima M, Nakamura K, Koike M (2001). Loss of syndecan-1 and increased expression of heparanase in invasive esophageal carcinomas. *Jpn J Cancer Res.* Oct; **92**(10): 1062–73.
- 49 Mishima M, Yano T, Jimbo H, Yano N, Morita Y, Yoshikawa H, *et al.* (1999). Inhibition of human endometrial cancer cell growth in vitro and in vivo by somatostatin analog RC-160. *Am J Obstet Gynecol.* **181**(3): 583–590.
- 50 Muller A, Nakagawa H, Rustgi AK (1997). Retinoic acid and N-(4-hydroxy-phenyl) retinamide suppress growth of esophageal squamous carcinoma cell lines. *Cancer Lett.* Feb 26; **113**(1–2): 95–101.
- 51 Murata A, Morishige F, Yamaguchi H (1982). Prolongation of survival times of terminal cancer patients by administration of large doses of ascorbate. *Int J Vitam Nutr Res Suppl.* **23**: 103–113.
- 52 Neuzil J, Kagedal K, Andera L, Weber C, Brunk UT (2002). Vitamin E analogs: a new class of multiple action agents with anti-neoplastic and anti-atherogenic activity. *Apoptosis.* **7**(2): 179–87.
- 53 Norsa A. and Martino V (2007). Somatostatin, Retinoidi, Melatonin, Vitamin D, Bromocriptine, and Cyclophosphamide in Chemotherapy-Pretreated Patients with Advanced Lung Adenocarcinoma and Low Performance Status. *Cancer Biotherapy & Radiopharmaceuticals.* **22** (1): 50–5.
- 54 Odeleye OE, Eskelson CD, Mufti SI, Watson RR (1992a). Vitamin E inhibition of lipid peroxidation and ethanol-mediated promotion of esophageal tumorigenesis. *Nutr Cancer.* **17**(3): 223–34.
- 55 Odeleye OE, Eskelson CD, Mufti SI, Watson RR (1992). Vitamin E protection against nitrosamine-induced esophageal tumor incidence in mice immunocompromised by retroviral infection. *Carcinogenesis.* Oct; **13**(10): 1811–6.
- 56 Onogi N, Okuno M, Matsushima-Nishiwaki R, Fukutomi Y, Moriwaki H, Muto Y, *et al.* (1998). Antiproliferative effect of carotenoids on human colon cancer cells without conversion to retinoic acid. *Nutr Cancer.* **32**(1): 20–24.
- 57 Ozerdem U, Stallcup WB (2004). Pathological angiogenesis is reduced by targeting pericytes via the NG2 proteoglycan. *Angiogenesis.* **7**(3): 269–276.

- 58 Piedrafita FJ & Pfahl M (1997). Retinoid-induced apoptosis and Sp1 cleavage occur independently of transcription and require caspase activation. *Mol Cell Biol.* **17**(11): 6348–58.
- 59 Pumphrey CY, Theus AM, Li S, Parrish RS, Sanderson RD (2002). Neoglycans, carbodiimide-modified glycosaminoglycans: a new class of anticancer agents that inhibit cancer cell proliferation and induce apoptosis. *Cancer Res.* **62**(13): 3722–8.
- 60 Roth AD, Morant R, Alberto P (1999). High dose etretinate and interferon-alpha – a phase I study in squamous cell carcinomas and transitional cell carcinomas. *Acta Oncol.* **38**(5): 613–7.
- 61 Schally AV, Comaru-Schally AM, Nagy A, Kovacs M, Szepeshazi K, Plonowski A, *et al.* (2001). Hypothalamic hormones and cancer. *Front Neuroendocrinol.* **22**(4): 248–291.
- 62 Shimizu M, Suzui M, Deguchi A (2004). Effects of acyclic retinoid on growth, cell cycle control, epidermal growth factor receptor signaling, and gene expression in human squamous cell carcinoma cells. *Clin Cancer Res.* Feb 1; **10**(3): 1130–40.
- 63 Shklar G & Schwartz JL (1996). Vitamin E inhibits experimental carcinogenesis and tumour angiogenesis. *Eur J Cancer B Oral Oncol.* **32B**(2): 114–119.
- 64 Szepesházi K, Halmos G, Schally AV, Arencibia JM, Groot K, Vadillo-Buenfil M, *et al.* (1999). Growth inhibition of experimental pancreatic cancers and sustained reduction in epidermal growth factor receptors during therapy with. *J Cancer Res Clin Oncol.* Aug-Sep; **125**(8–9): 444–52.
- 65 Tang FY & Meydani M (2001). Green tea catechins and vitamin E inhibit angiogenesis of human microvascular endothelial cells through suppression of IL-8 production. *Nutr Cancer.* **41**(1–2): 119–125.
- 66 Todisco M, Casaccia P, Rossi N (2001). Cyclophosphamide plus somatostatine, bromocriptin, retinoids, melatonin and ACTH in the treatment of low-grade none-Hodgkin's lymphomas at advanced stage: results of a phase II trial. *Cancer Biother Radiopharm.* **16**(2):171-7
- 67 Turley JM, Funakoshi S, Ruscetti FW, Kasper J, Murphy WJ, Longo DL, *et al.* (1995). Growth inhibition and apoptosis of RL human B lymphoma cells by vitamin E succinate and retinoic acid: role for transforming growth factor beta. *Cell Growth Differ.* **6**(6): 655–663.
- 68 Turner HE, Nagy Z, Gatter KC, Esiri MM, Harris AL, Wass JA (2000). Angiogenesis in pituitary adenomas – relationship to endocrine function, treatment and outcome. *J Endocrinol.* **165**(2): 475–481.
- 69 Vidal S, Oliveira MC, Kovacs K, Scheithauer BW, Lloyd R (2000). Immunolocalization of vascular endothelial growth factor in the GH3 cell line. *Cell Tissue Res.* **300**(1): 83–88.
- 70 Wang C, Tammi M, Guo H, Tammi R, Hyaluronan (1996). Distribution in the normal epithelium of esophagus, stomach, and colon and their cancers. *Am J Pathol.* Jun; **148**(6): 1861–9.
- 71 Wang ZH, Yam HF, Or PC, Yang L (1999). Effects of all-trans-retinoic acid on human esophageal carcinoma cells and their nuclear matrices. *Anticancer Res.* Jan-Feb; **19**(1A): 563–8.
- 72 Watson JC, Balster DA, Gebhardt BM, O'Dorisio TM, O'Dorisio MS, Espenan GD, *et al.* (2001). Growing vascular endothelial cells express somatostatin subtype 2 receptors. *Br J Cancer.* **85**(2): 266–272.
- 73 Wiedermann CJ, Reinisch N, Braunsteiner H (1993). Stimulation of monocyte chemotaxis by human growth hormone and its deactivation by somatostatin. *Blood.* **82**(3): 954–960.