

# Combination of voxel based morphometry and diffusion tensor imaging in patients with Alzheimer's disease

Ibrahim IBRAHIM<sup>1,2,3</sup>, Jiri HORACEK<sup>4</sup>, Ales BARTOS<sup>4,5</sup>, Milan HAJEK<sup>1</sup>, Daniela RIPOVA<sup>4</sup>, Martin BRUNOVSKY<sup>4</sup>, Jaroslav TINTERA<sup>1,2</sup>

1. Department of Diagnostic and Interventional Radiology, Institute for Clinical and Experimental Medicine, MR Unit, Prague, Czech Republic
2. Center of Neuropsychiatric Studies, Prague, Czech Republic
3. 2nd Faculty of Medicine, Charles University, Prague, Czech Republic
4. Prague Psychiatric Centre, Prague, Czech Republic
5. 3rd Faculty of Medicine, Charles University, University Hospital Kralovske Vinohrady, Department of Neurology, Prague, Czech Republic

*Correspondence to:* Ibrahim IBRAHIM, MSc.  
Department of Diagnostic and Interventional Radiology  
Institute for Clinical and Experimental Medicine, MR Unit  
Videnska 1958/9, 14021, Prague, Czech Republic  
TEL.:+420236055348, EMAIL: ibib@medicon.cz

*Submitted:* 2008-12-23 *Accepted:* 2009-01-27 *Published online:* 2009-02-28

*Key words:* **Alzheimer's disease; voxel-based morphometry; diffusion tensor imaging; MRI; white matter; grey matter; fractional anisotropy; age**

Neuroendocrinol Lett 2009; **30**(1):39-45 PMID: 19300399 NEL300109A05 © 2008 Neuroendocrinology Letters • [www.nel.edu](http://www.nel.edu)

## Abstract

**OBJECTIVE:** The aim of the study was to assess structural changes in gray matter (GM) volume and fractional anisotropy (FA) in patients with Alzheimer's disease (AD) compared to control subjects using Voxel-Based Morphometry (VBM). Fractional anisotropy in the corpus callosum of both groups was also calculated using ROI analysis.

**METHODS:** Twenty-one patients and twenty-three control subjects underwent MRI examination using T1-weighted 3D MPRAGE sequence and diffusion spin-echo echo-planar imaging sequence in six directions. Structural MRI analyses for GM volume and FA were performed using an optimized VBM protocol implemented in SPM5. The influence of age and Mini-Mental State Examination (MMSE) was dealt with multiple regression analysis either for the whole group or for AD patients and controls separately.

**RESULTS:** Patients showed significant reduction of GM volume mainly in the temporal lobes. In AD patients, no correlation was observed between GM volume and age or MMSE. FA was reduced in AD patients mainly in frontal and temporal lobes. In both groups no correlation was found between FA and age or MMSE. Patients with AD showed a significant decrease in FA and an increase in mean diffusivity ( $p < 0.0001$ ) in the corpus callosum.

**CONCLUSIONS:** In patients with AD we observed a significant reduction in FA values and GM volume; however, no correlation with age and MMSE was proven for both FA and GM for AD patients. This finding supports the hypothesis that morphological changes in patients with AD are not a continuous aging related process but represent qualitative changes.

#### Abbreviation and units:

|              |  |
|--------------|--|
| NINCDS-ADRDA | – National Institute of Neurological and Communicative Disorders and Stroke/ Alzheimer's Disease and Related Disorders Association |
| VBM          | – Voxel-Based Morphometry  |
| DTI          | – Diffusion Tensor Imaging   |
| MRI          | – Magnetic Resonance Imaging   |
| AD           | – Alzheimer's Disease  |
| MMSE         | – Mini-Mental State Examination  |
| DW           | – Diffusion Weighted   |
| FA           | – Fractional Anisotropy  |
| ROI          | – Region of Interest   |
| MD           | – Mean Diffusivity ( $10^{-3} \text{ mm}^2 / \text{s}$ )   |

## INTRODUCTION

With the increasing age of the population, Alzheimer's disease (AD) has become an important public health problem. Alzheimer's disease is a neurodegenerative disorder that is characterized by general brain atrophy with progressive executive dysfunction, and global cognitive impairment (Bäckman *et al.* 2005). Many studies have shown that functional and structural damage in patients with AD are caused by the accumulation of  $\beta$ -amyloid protein and intraneuronal neurofibrillary tangles in the brain resulting in neural death or neural network dysfunction (Xie and Tanzi, 2006; Small, 2008). Stress (Esch *et al.* 2002) and the presence of mercury, aluminum and other metals in the brain may also play a role in the pathogenesis of AD (Mutter *et al.* 2004; Domingo, 2006).

Voxel-based morphometry (VBM), a method based on either structural or functional magnetic resonance imaging (MRI) examination data to evaluate brain differences between two groups, as well as diffusion tensor imaging (DTI) have become useful tools in research and clinical practice for the assessment of neurological diseases such as AD and other dementia (Good *et al.* 2001; Chua *et al.* 2008; Snook *et al.* 2007).

Although AD is assumed to mainly affect gray matter (GM), scores of studies using whole brain VBM analysis and other techniques show changes in both gray and white matter (WM) in patients with AD (Xie *et al.* 2006; Baron *et al.* 2001). The characteristic brain features of AD on MRI are widespread brain atrophy, ventricular enlargement, sulcal widening and increased cerebrospinal fluid (CSF) volume (Smith, 2002; Lehericy *et al.* 2007; Matsumae *et al.* 1996). Studies of patients with AD compared to control subjects showed a reduction of GM volume in the temporal and prefrontal cortices, insula, basal forebrain and precuneus (Apostolova *et al.* 2007; Xie *et al.* 2006). VBM analysis of FA in the whole brain also showed regions of abnormalities with lower FA in patients with AD in the WM within the corpus callosum, superior longitudinal fasciculi, internal capsules, and cerebral peduncles (Naggara *et al.* 2006; Xie *et al.* 2006).

The aim of this study was to assess changes in gray matter volume and values of FA in patients with AD

compared to control subjects using optimized VBM analysis. Furthermore, in both groups we evaluated fractional anisotropy of the corpus callosum (CC) using ROI analysis to determine relationships between FA and age or MMSE.

## METHODS

### Subjects

Twenty-one patients with AD (11 women and 9 men, mean age (mean  $\pm$  SD)  $73.67 \pm 7.58$  years; range 58–81 years) according to the National Institute of Neurological and Communicative Diseases and Stroke/Alzheimer's Disease and Related Disorders Association (NINCDS-ADRDA) criteria (McKhann *et al.* 1984) and twenty-three control subjects (18 women and 5 men; mean age  $66.70 \pm 5.82$  years; range 60–80 years) underwent MRI and DTI examinations. Control subjects did not have cognitive complaints. The study was approved by the Czech Ethics Committee of the Prague Psychiatric Centre and all patients and control subjects gave written informed consent to participate in the study.

### MRI Acquisition

MRI examinations were performed on a 1.5T Siemens Vision MR scanner with a standard head coil using the following protocol: 1) T1-weighted (T1W) 3D magnetization prepared rapid acquisition gradient echo (MPRAGE) with these parameters: voxel size of  $1 \times 1 \times 1$  mm, 160 sagittal slices, echo time (TE) of 7 ms, repetition time (TR) of 2010 ms, flip angle of  $10^\circ$ , and field of view (FOV) of 256 mm. 2) Diffusion weighted images (DWI) using spin-echo echo-planar imaging (SE-EPI) sequence with the following parameters: TR = 6 s, TE = 110 ms, voxel size of  $2.5 \times 2.5 \times 2.5$  mm, 27 axial slices, 3 averages, FOV = 320 mm, 6 diffusion directions, and two b-values: 0, 1000 s /  $\text{mm}^2$ .

### Neurological demographic data

Cognitive status in all subjects was evaluated using MMSE. The MMSE scores of the patients with AD were  $15.60 \pm 7.20$  (mean  $\pm$  SD) and in the control subjects were  $29.13 \pm 0.99$ . The educational levels of the AD patients were  $13.10 \pm 2.95$  years, and in the control group were  $14.22 \pm 2.36$  years. There were significant differences in MMSE scores ( $p < 0.001$ ) and age ( $p < 0.002$ ) between patients and control subjects. Therefore, age was used as a covariate for all analyses. Table 1 shows participant demographic data (age, MMSE and education level).

### VBM analysis

Data were analyzed using SPM5 with protocol implemented of optimized VBM (<http://www.fil.ion.ucl.ac.uk/spm/software/spm5>). Briefly, each 3D volume of T1W images was segmented into GM, WM, and cerebrospinal fluid. Spatial normalization parameters were estimated by matching GM tissue with the standard

**Table 1.** Participant demographics data (age, MMSE and education level). SD: Standard deviation; ns: not significant

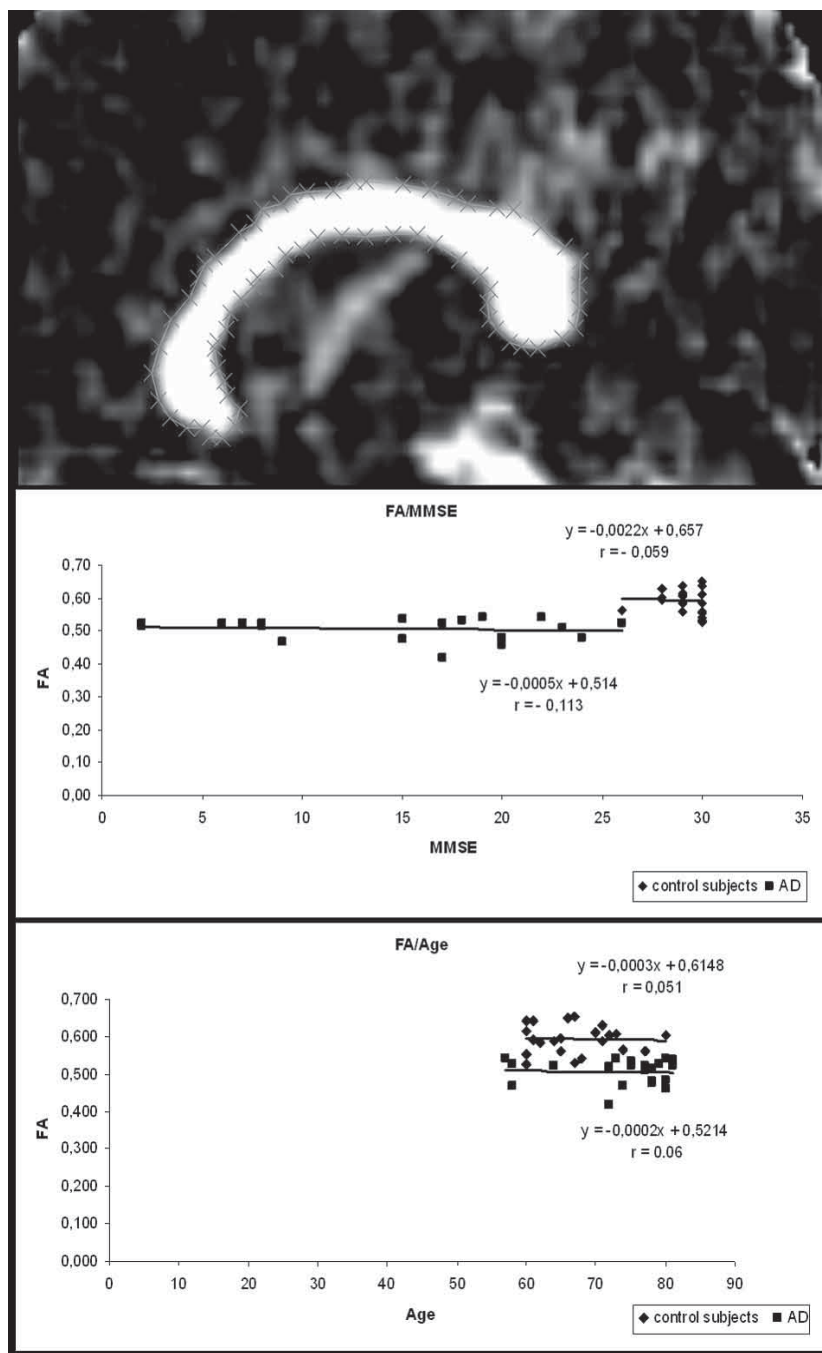
|                                   | AD patients (n = 21) | Controls (n = 23) | p-value |
|-----------------------------------|----------------------|-------------------|---------|
| Age, years (mean ± SD)            | 73.67 ± 7.58         | 66.70 ± 5.82      | < 0.002 |
| MMSE (± SD)                       | 15.60 ± 7.20         | 29.13 ± 0.99      | < 0.001 |
| Education level, years(mean ± SD) | 13.10 ± 2.95         | 14.22 ± 2.36      | ns      |

GM template provided by SPM5. The normalization parameters were applied to the original T1W images. Optimally normalized T1W images were then segmented into GM, WM, and CSF segments. In order to restore tissue volumes modified during normalization processing, Jacobian modulation was applied to normalize GM and WM segments. Modulated GM and WM images were smoothed with a 10 mm full width at half maximum (FWHM) kernel. To avoid potential bias from the normalization process, anatomical, grey and white matter templates-referred to a stereotactic space – Montreal Neurological Institute (MNI) were created, including all T1WI.

The diffusion-weighted (DW) images were first realigned for motion correction using SPM5. Then for each subject, all DW and non-DW (b0) images were registered to the b0 image and normalized to the T2-weighted image template in stereotactic space (MNI). The diffusion tensors for each voxel in the brain tissue were estimated using MedINRIA (Asclepios Research Project – INRIA Sophia Antipolis, <http://www-sop.inria.fr/asclepios/software/MedINRIA>). A threshold of FA > 0.2 was selected and FA images were calculated. The T2-weighted image template from the MNI was used to determine normalization parameters subsequently applied, using affine transformation to the FA images. Normalized FA images were then smoothed with a 10 mm kernel. A white matter mask derived from normalized WM image was used to restrict the FA analysis to the white matter.

#### Statistical analyses

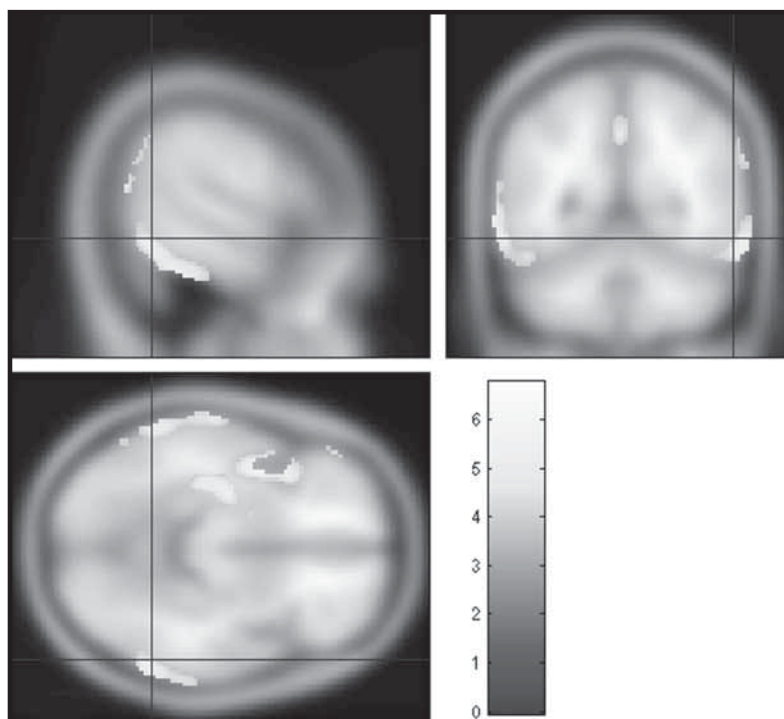
The modulated, normalized, segmented, and smoothed GM, WM and FA data were statistically tested by the use of SPM5 employing a general linear model (GLM), using t-test with



**Figure 1.** The ROI selected of the corpus callosum in the midsagittal slice of the FA image (above). Scatterplots show correlations between fractional anisotropy (FA) and Mini-Mental State Examination (MMSE) scores (middle) and age (bottom).

**Table 2.** Regions of significantly reduced gray matter volume in patients with AD compared to control subjects. BA : Brodmann area; R = right, L = left, p-value < 0.005 with the FDR corrected.

| Brain regions                   | Side (L, R) | Talairach space X, Y, Z (mm) | Cluster size > 50 voxels | p-value < 0.005 (FDR cor) | T-value |
|---------------------------------|-------------|------------------------------|--------------------------|---------------------------|---------|
| Middle Temporal Gyrus, BA 21    | L           | -66 -38 0                    | 3765                     | 0.001                     | 6.76    |
| Fusiform Gyrus, BA 36           | L           | -46 -40 -26                  | < 50                     | 0.001                     | 6.51    |
| Hippocampus                     | L           | -30 -14 -16                  | < 50                     | 0.001                     | 6.20    |
| Insula, BA 13                   | L           | -44 4 -4                     | 2270                     | 0.001                     | 6.08    |
| Anterior lobe, Culmen of vermis | R           | 52 -40 -28                   |                          | 0.001                     | 5.75    |
| Inferior Temporal Gyrus, BA 20  | R           | 62 -50 -16                   | 1076                     | 0.001                     | 5.87    |
| Inferior Temporal Gyrus, BA 20  | R           | 70 -22 -20                   | < 50                     | 0.001                     | 5.29    |
| Cuneus, BA 19                   | R           | 24 -86 38                    | < 50                     | 0.002                     | 4.74    |
| Superior Parietal Lobule, BA 7  | R           | 26 -72 46                    | 63                       | 0.001                     | 4.96    |
| Middle Temporal Gyrus, BA 19    | R           | 56 -68 16                    |                          | 0.004                     | 3.99    |
| Angular Gyrus, BA 39            | R           | 52 -66 36                    | 185                      | 0.001                     | 4.88    |
| Supramarginal Gyrus, BA 40      | R           | 62 -54 30                    | < 50                     | 0.002                     | 4.51    |
| Superior Temporal Gyrus, BA 38  | R           | 32 12 -22                    | < 50                     | 0.002                     | 4.38    |
| Middle Frontal Gyrus, BA 46     | L           | -56 28 18                    | 73                       | 0.002                     | 4.76    |
| Insula, BA 13                   | R           | 44 -4 0                      | 57                       | 0.002                     | 4.70    |

**Figure 2.** Regions of significantly reduced gray matter volume in patients with AD compared with control subjects in the temporal lobes, insulae, right parietal lobe and right cuneus.

age as the nuisance covariate. The influence of age and MMSE was treated in multiple regression analysis for either the whole group or for AD patients and controls separately. Voxel level inferences were used at  $p$ -value < 0.005 with the false discovery rate (FDR) correction, and clusters containing at least 50 contiguous voxels were reported.

The region of interest (ROI) of the corpus callosum was manually selected (the boundaries of the CC were outlined) in the midsagittal

slice for each normalized FA image of AD and control subjects (Figure 1). The FA was then calculated in MedINRIA. For evaluating MMSE scores' differences between both groups, a paired t-test was used ( $p < 0.001$ ).

## RESULTS

### *Gray matter volume*

Patients with AD showed a significant reduction of GM volume compared to control subjects mainly in the temporal lobes and sub-lobar regions (insulae). However, reductions were also observed in the left middle frontal lobe, right cuneus, right culmen of vermis and right parietal lobe (for details see Table 2, Figure 2).

A negative correlation between GM volume and age was observed in control subjects in the superior temporal gyri (BA 38, 42, 22), middle temporal gyri (BA 21), left transverse temporal gyrus (BA 42), inferior frontal gyri (BA 47), left middle frontal gyri (BA 10), right precentral gyrus (BA6), right rectal and orbital gyrus (BA 11), occipital lobes (cuneus and lingual gyrus, BA 18, 19), left limbic lobe (uncus, BA 20), parietal lobes (BA 40, 43) and the right culmen of vermis. However, no correlation was observed between GM volume and

**Table 3.** Regions of significantly reduced FA in patients with AD compared to control subjects. *p*-value < 0.005 with the FDR corrected; R = right, L = left

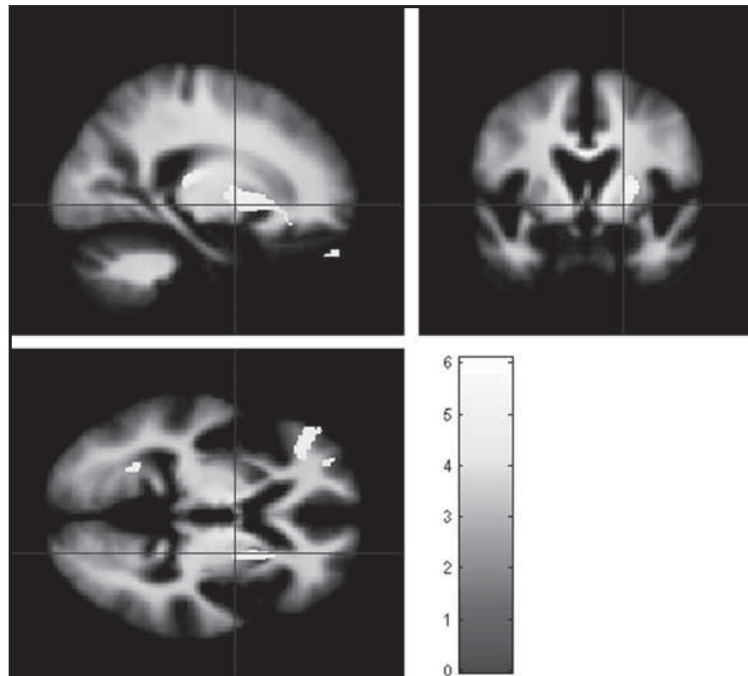
| Brain regions                              | Side (L, R) | Talairach space X, Y, Z (mm) | Cluster size > 50 voxels | <i>p</i> -value < 0.005 (FDR cor) | T-value |
|--|-------------|------------------------------|--------------------------|-----------------------------------|---------|
| Superior Temporal Gyrus                    | R           | 40 -46 15                    | 298                      | 0.002                             | 6.09    |
| Sub-Lobar Extra-Nuclear, CC                | L           | -8 -17 14                    | 1964                     | 0.002                             | 5.71    |
| Inter-Hemispheric, Sub-Lobar Extra-Nuclear | L           | -1 -16 9                     | < 50                     | 0.002                             | 5.60    |
| Sub-Lobar Extra-Nuclear, Insula            | R           | 26 -28 10                    | < 50                     | 0.002                             | 5.32    |
| Sub-Lobar Extra-Nuclear                    | R           | 25 -1 9                      | 1186                     | 0.002                             | 5.56    |
| Frontal Lobe (Sub-Gyral)                   | R           | 20 27 -9                     | < 50                     | 0.004                             | 4.31    |
| Frontal Lobe (Sub-Gyral)                   | R           | 19 19 -5                     | < 50                     | 0.004                             | 4.30    |
| Superior Frontal Gyrus                     | L           | -6 57 19                     | 332                      | 0.002                             | 5.48    |
| Rectal Gyrus, inter-Hemispheric            | R           | 5 49 -23                     | 215                      | 0.002                             | 5.25    |
| Middle Frontal Gyrus                       | L           | -44 38 -4                    | 382                      | 0.002                             | 5.21    |
| Temporal Lobe (Sub-Gyral)                  | R           | 39 -26 -10                   | 121                      | 0.002                             | 5.14    |
| Occipital Lobe (Lingual Gyrus)             | L           | -25 -56 1                    | 189                      | 0.002                             | 5.10    |
| Middle Frontal Gyrus                       | R           | 30 54 19                     | 56                       | 0.002                             | 5.10    |
| Frontal Lobe (Sub-Gyral)                   | R           | 41 9 14                      | 316                      | 0.002                             | 5.02    |
| Fusiform Gyrus                             | L           | -43 -29 -20                  | 147                      | 0.002                             | 4.98    |
| Frontal Lobe (Sub Gyral)                   | L           | -44 13 14                    | 280                      | 0.002                             | 4.85    |
| Insula                                     | R           | 46 -26 19                    | 237                      | 0.003                             | 4.70    |
| Middle Frontal Gyrus                       | L           | -29 49 -3                    | 70                       | 0.004                             | 4.30    |
| Superior Frontal Gyrus                     | L           | -20 36 31                    | 56                       | 0.004                             | 4.22    |

MMSE in control subjects. In the AD group we did not find any correlation between GM volume and age or MMSE.

#### *Fractional anisotropy*

Compared to control subjects, the FA value in patients with AD was significantly reduced in the frontal lobes, sub-lobar regions extra-nuclear WM, CC, left occipital lobe, right insula and temporal lobes (for details see Table 3, Figure 3). Despite this fact, our results did not confirm any significant correlation between FA changes and age or MMSE in the control subjects or patients with AD (Figure 1).

Patients with AD showed a decline in FA ( $p < 0.0001$ ) and an increase in mean diffusivity (MD) values compared to control subjects using ROI analysis in the corpus callosum. The mean value of FA in the CC was 0.51 (ranges 0.42–0.54) in patients with AD, whereas in control subjects it was 0.59 (ranges 0.53–0.65). The mean value of MD was  $1.26$  (ranges  $1.10$ – $1.58$ )  $\times 10^{-3}$   $\text{mm}^2 / \text{s}$  in patients with AD and  $1.03$



**Figure 3.** Regions of significantly reduced FA values in patient with AD compared to control subjects. The color coding represents T-values.

(ranges  $0.93$ – $1.17$ )  $\times 10^{-3}$   $\text{mm}^2 / \text{s}$  in the control subjects. There was no significant correlation found between the FA and age in either the control subjects ( $r = -0.05$ ) or patients with AD ( $r = -0.06$ ) by using ROI analysis in the CC.

## DISCUSSION

Our data confirmed previous findings that the progressive cognitive impairment in Alzheimer's disease is a consequence of general brain atrophy (Xanthakos, 1996). The present optimized VBM showed GM volume reduction in patients with AD compared to control subjects in the temporal lobes that are consistent with previous VBM findings in AD patients (Xie *et al.* 2006; Baron *et al.* 2001; Busatto *et al.* 2003; Karas *et al.* 2003; Frisoni *et al.* 2002). In accordance with previous findings, our study also showed GM volume atrophy in AD patients in both insulae, left middle frontal gyrus (Frisoni *et al.* 2002), and parieto-occipital regions (right angular gyrus, right supramarginal gyrus and right cuneus) (Kinkingnéhun *et al.* 2008). The present study further confirmed previous studies that did not find any significant GM volume reduction in control subjects compared to AD patients (Karas *et al.* 2003).

Several studies showed significant negative correlations between global GM volume and age in healthy controls (Abe *et al.* 2008; Smith *et al.* 2007; Tisserand *et al.* 2004). Our study showed GM volume reduction with age in healthy controls in the temporal and frontal lobes which are in agreement with previous VBM findings in control subjects (Abe *et al.* 2008; Smith *et al.* 2007; Alexander *et al.* 2006; Good *et al.* 2001). The present findings confirmed that continuous physiological atrophy of GM only in the control subjects proceeded with age. However, **the morphological changes in patients with AD are not a continuous physiological process related to aging but represent qualitative changes in the brain in patients with AD.**

The FA value reductions in patients with AD in the frontal and temporal lobes (Table 3, Figure 3) were consistent with previous FA findings in AD (Teipel *et al.* 2007; Medina *et al.* 2006; Li *et al.* 2008). The FA decline in the mentioned lobes is a demonstration of changes in WM tracts and may reflect executive dysfunction and memory decline in patients with AD. The FA decline in the sub-lobar extra-nuclear WM in patients is consistent with previous findings in AD patients (Medina *et al.* 2006). Our findings (FA decline) in the frontal and temporal lobes of patients can be also supported by previous DTI studies in AD (Naggara *et al.* 2006; Bozzali *et al.* 2002; Duan *et al.* 2006). The absence of significant correlation between FA and MMSE in patients with AD is in accordance with several previous studies (Naggara *et al.* 2006; Takahashi *et al.* 2002; Bozzali *et al.* 2001).

The corpus callosum is the massive and most important commissural bundle that connects both hemispheres and plays a very important role in the interhemispheric communication of the brain. Therefore, the abnormalities in FA values of the corpus callosum may reflect the integrity of WM tracts, resulting in cognitive dysfunction in patients with AD. The FA decline and increase in MD values in patients with AD in the corpus callosum are consistent with previous studies that demonstrated

changes in FA and MD values in patients with AD (Li *et al.* 2008; Bozzali *et al.* 2002; Thomann *et al.* 2006). The absence of correlations between FA and MMSE in control subjects ( $r = 0.059$ ) and in AD patients ( $r = 0.113$ ) in the corpus callosum [Figure 1] is in accordance with the previous findings in patients with AD (Naggara *et al.* 2006; Takahashi *et al.* 2002).

Previous studies (Ota *et al.* 2006; Stadlbauer *et al.* 2008; Grieve *et al.* 2007; Salat *et al.* 2005) demonstrated FA decline with age in the corpus callosum. Conversely, the present study did not confirm correlations between FA and age in the CC in either the controls or patients, although a trend for negative correlation was observed. The different findings may be attributed to two reasons: firstly, in contrast to the above studies where studied groups included subjects of a wide age range (Ota *et al.* 2006; Stadlbauer *et al.* 2008; Grieve *et al.* 2007; Salat *et al.* 2005) no younger subjects (below 58 years of age) were present in our study. Secondly, the placement and the size of the volume of interest differed between the above-mentioned studies and our study. Many authors used a small sphere for ROIs analysis in the genu and splenium of the corpus callosum (Salat *et al.* 2005; Duan *et al.* 2006), and then calculated FA in each region separately. In the present study, the boundaries of the corpus callosum were manually outlined in the midsagittal slice as ROIs. This indicates that the FA/age dependence may be different for particular areas in the CC. However, this finding remains to be investigated using detailed spatial analysis of the corpus callosum.

## CONCLUSION

We observed significant changes in GM volume and FA values in patients with AD compared to control subjects. The absence of correlation of GM volume with age in patients confirmed that AD is not a continuous progression of morphological changes with age but represents qualitative changes in GM brain structures.

## Acknowledgements

This work was supported by grants IGA 1A8600 and NR-8792-3 from the Internal Grant Agency of the Ministry of Health, Czech Republic and projects MZ0PCP2005, MZ0IKEM2005 and 1M0517 from the Ministry of Education, Youth and Sports, Czech Republic.

## REFERENCES

- 1 Abe O, Yamasue H, Aoki S, Suga M, Yamada H, Kasai K, Masutani Y, Kato N, Kato N, Ohtomo K (2008). Aging in the CNS: comparison of gray/white matter volume and diffusion tensor data. *Neurobiol Aging*. **29**(1): 102–16.
- 2 Alexander GE, Chen K, Merkle TL, Reiman EM, Caselli RJ, Ashenbrenner M, Santerre-Lemmon L, Lewis DJ, Pietrini P, Teipel SJ, Hampel H, Rapoport SI, Moeller JR (2006). Regional network of magnetic resonance imaging gray matter volume in healthy aging. *Neuroreport*. **17**(10): 951–6.

- 3 Apostolova LG, Steiner CA, Akopyan GG, Dutton RA, Hayashi KM, Toga AW, Cummings JL, Thompson PM (2007). Three-dimensional gray matter atrophy mapping in mild cognitive impairment and mild Alzheimer disease. *Arch Neurol*. **64**(10): 1489–95.
- 4 Bäckman L, Jones S, Berger AK, Laukka EJ, Small BJ (2005). Cognitive impairment in preclinical Alzheimer's disease: a meta-analysis. *Neuropsychology*. **19**(4): 520–31.
- 5 Baron JC, Chételat G, Desgranges B, Perchet G, Landeau B, de la Sayette V, Eustache F. (2001) In vivo mapping of gray matter loss with voxel-based morphometry in mild Alzheimer's disease. *Neuroimage*. **14**(2): 298–309.
- 6 Bozzali M, Falini A, Franceschi M, Cercignani M, Zuffi M, Scotti G, Comi G, Filippi M (2002). White matter damage in Alzheimer's disease assessed in vivo using diffusion tensor magnetic resonance imaging. *J Neurol Neurosurg Psychiatry*. **72**(6): 742–6.
- 7 Bozzali M, Franceschi M, Falini A, Pontesilli S, Cercignani M, Magnani G, Scotti G, Comi G, Filippi M (2001). Quantification of tissue damage in AD using diffusion tensor and magnetization transfer MRI. *Neurology*. **57**(6): 1135–7.
- 8 Busatto GF, Garrido GE, Almeida OP, Castro CC, Camargo CH, Cid CG, Buchpiguel CA, Furuie S, Bottino CM (2003). A voxel-based morphometry study of temporal lobe gray matter reductions in Alzheimer's disease. *Neurobiol Aging*. **24**(2): 221–31.
- 9 Chua TC, Wen W, Slavin MJ, Sachdev PS (2008). Diffusion tensor imaging in mild cognitive impairment and Alzheimer's disease: a review. *Curr Opin Neurol*. **21**(1): 83–92.
- 10 Domingo JL (2006). Aluminum and other metals in Alzheimer's disease: a review of potential therapy with chelating agents. *J Alzheimers Dis*. Nov; **10**(2-3): 331–41.
- 11 Duan JH, Wang HQ, Xu J, Lin X, Chen SQ, Kang Z, Yao ZB (2006). White matter damage of patients with Alzheimer's disease correlated with the decreased cognitive function. *Surg Radiol Anat*. **28**(2): 150–6.
- 12 Esch T, Stefano GB, Fricchione GL, Benson H (2002). The role of stress in neurodegenerative diseases and mental disorders. *Neuro Endocrinol Lett*. **23**(3): 199–208.
- 13 Frisoni GB, Testa C, Zorzan A, Sabattoli F, Beltramello A, Soininen H, Laakso MP (2002). Detection of grey matter loss in mild Alzheimer's disease with voxel based morphometry. *J Neurol Neurosurg Psychiatry*. **73**(6): 657–64.
- 14 Good CD, Johnsrude IS, Ashburner J, Henson RN, Friston KJ, Frackowiak RS (2001). A voxel-based morphometric study of ageing in 465 normal adult human brains. *Neuroimage*. **14**(1 Pt 1): 21–36.
- 15 Grieve SM, Williams LM, Paul RH, Clark CR, Gordon E (2007). Cognitive aging, executive function, and fractional anisotropy: a diffusion tensor MR imaging study. *AJNR Am J Neuroradiol*. **28**(2): 226–35.
- 16 Karas GB, Burton EJ, Rombouts SA, van Schijndel RA, O'Brien JT, Scheltens P, McKeith IG, Williams D, Ballard C, Barkhof F (2003). A comprehensive study of gray matter loss in patients with Alzheimer's disease using optimized voxel-based morphometry. *Neuroimage*. **18**(4): 895–907.
- 17 Kinkingnehun S, Sarazin M, Lehericy S, Guichart-Gomez E, Hergueta T, Dubois B (2008). VBM anticipates the rate of progression of Alzheimer disease: a 3-year longitudinal study. *Neurology*. **70**(23): 2201–11.
- 18 Lehericy S, Marjanska M, Mesrob L, Sarazin M, Kinkingnehun S (2007). Magnetic resonance imaging of Alzheimer's disease. *Eur Radiol*. **17**(2): 347–62.
- 19 Li S, Pu F, Shi F, Xie S, Wang Y, Jiang T (2008). Regional white matter decreases in Alzheimer's disease using optimized voxel-based morphometry. *Acta Radiol*. **49**(1): 84–90.
- 20 Matsumae M, Kikinis R, Mórocz I, Lorenzo AV, Albert MS, Black PM, Jolesz FA (1996). Intracranial compartment volumes in patients with enlarged ventricles assessed by magnetic resonance-based image processing. *J Neurosurg*. **84**(6): 972–81.
- 21 McKhann G, Drachman D, Folstein M, Katzman R, Price D, Stadlan EM (1984). Clinical diagnosis of Alzheimer's disease: report of the NINCDS-ADRDA Work Group under the auspices of Department of Health and Human Services Task Force on Alzheimer's Disease. *Neurology*. **34**(7): 939–44.
- 22 Medina D, DeToledo-Morrell L, Urresta F, Gabrieli JD, Moseley M, Fleischman D, Bennett DA, Leurgans S, Turner DA, Stebbins GT (2006). White matter changes in mild cognitive impairment and AD: A diffusion tensor imaging study. *Neurobiol Aging*. **27**(5): 663–72.
- 23 Mutter J, Naumann J, Sadaghiani C, Schneider R, Walach H (2004). Alzheimer disease: mercury as pathogenetic factor and apolipoprotein E as a moderator. *Neuro Endocrinol Lett*. Oct; **25**(5): 331–9. Review
- 24 Naggara O, Oppenheim C, Rieu D, Raoux N, Rodrigo S, Dalla Barba G, Meder JF (2006). Diffusion tensor imaging in early Alzheimer's disease. *Psychiatry Res*. **146**(3): 243–9.
- 25 Ota M, Obata T, Akine Y, Ito H, Ikehira H, Asada T, Suhara T (2006). Age-related degeneration of corpus callosum measured with diffusion tensor imaging. *Neuroimage*. **31**(4): 1445–52.
- 26 Salat DH, Tuch DS, Greve DN, van der Kouwe AJ, Hevelone ND, Zaleta AK, Rosen BR, Fischl B, Corkin S, Rosas HD, Dale AM (2005). Age-related alterations in white matter microstructure measured by diffusion tensor imaging. *Neurobiol Aging*. **26**(8): 1215–27.
- 27 Small DH (2008). Network dysfunction in Alzheimer's disease: does synaptic scaling drive disease progression? *Trends Mol Med*. **14**(3): 103–8.
- 28 Smith AD (2002). Imaging the progression of Alzheimer pathology through the brain. *Proc Natl Acad Sci U S A*. **99**(7): 4135–7.
- 29 Smith CD, Chebrolu H, Wekstein DR, Schmitt FA, Markesbery WR (2007). Age and gender effects on human brain anatomy: a voxel-based morphometric study in healthy elderly. *Neurobiol Aging*. **28**(7): 1075–87.
- 30 Snook L, Plewes C, Beaulieu C (2007). Voxel based versus region of interest analysis in diffusion tensor imaging of neurodevelopment. *Neuroimage*. **34**(1): 243–52.
- 31 Stadlbauer A, Salomonowitz E, Strunk G, Hammen T, Ganslandt O (2008). Age-related degradation in the central nervous system: assessment with diffusion-tensor imaging and quantitative fiber tracking. *Radiology*. **247**(1): 179–88.
- 32 Takahashi S, Yonezawa H, Takahashi J, Kudo M, Inoue T, Tohgi H (2002). Selective reduction of diffusion anisotropy in white matter of Alzheimer disease. brains measured by 3.0 Tesla magnetic resonance imaging. *Neurosci Lett*. **332**(1): 45–8.
- 33 Teipel SJ, Stahl R, Dietrich O, Schoenberg SO, Perneczky R, Bokde AL, Reiser MF, Möller HJ, Hampel H (2007). Multivariate network analysis of fiber tract integrity in Alzheimer's disease. *Neuroimage*. **34**(3): 985–95.
- 34 Thomann PA, Wustenberg T, Pantel J, Essig M, Schroder J (2006). Structural changes of the corpus callosum in mild cognitive impairment and Alzheimer's disease. (*Dement Geriatr Cogn Disord*. **21**(4): 215–20.
- 35 Tisserand DJ, van Boxtel MP, Pruessner JC, Hofman P, Evans AC, Jolles J (2004). A voxel-based morphometric study to determine individual differences in gray matter density associated with age and cognitive change over time. *Cereb Cortex*. **14**(9): 966–73.
- 36 Xanthakos S, Krishnan KR, Kim DM, Charles HC (1996). Magnetic resonance imaging of Alzheimer's disease. *Prog Neuropsychopharmacol Biol Psychiatry*. May; **20**(4): 597–626.
- 37 Xie S, Xiao JX, Gong GL, Zang YF, Wang YH, Wu HK, Jiang XX (2006). Voxel-based detection of white matter abnormalities in mild Alzheimer disease. *Neurology*. **27**; **66**(12): 1845–9.
- 38 Xie Z, Tanzi RE (2006). Alzheimer's disease and post-operative cognitive dysfunction. *Exp Gerontol*. **41**(4):346–59.