

# The analysis of CD34 antigen immunoreactivity level in invasive ductal breast cancer with respect to the presence of lymph node metastases

Tadeusz J. POPIELA<sup>1</sup>, Jerzy SIKORA<sup>2</sup>, Marek KLIMEK<sup>3</sup>, Pawel BASTA<sup>4</sup>, Tomasz NIEMIEC<sup>2</sup>, Jan DOBROGOWSKI<sup>5</sup>, Agnieszka KOTLARZ<sup>6</sup>, Lucyna RUDNICKA-SOSIN<sup>6</sup>, Magdalena DUTSCH-WICHEREK<sup>\*4</sup>

1. 1<sup>st</sup> General Surgery Department of the Jagiellonian University, 40 Kopernik Str, 31-501 Krakow, Poland
2. Department of Gynecology and Obstetrics of the Medical University, Katowice, Poland;
3. Department of Gynecology and Infertility, Jagiellonian University, Krakow, Poland
4. Department of Gynecology, Obstetrics and Oncology of the Jagiellonian University, Krakow, Poland
5. Department of Anesthesiology and Intensive Care Unit of the Jagiellonian University, Krakow, Poland
6. Department of Pathomorphology of the Jagiellonian University, Krakow, Poland

*Correspondence to:* Magdalena Dutsch-Wicherek, MD, PhD.  
Gynecology and Obstetrics Department of the Jagiellonian University,  
23 Kopernik Street 30-501 Krakow Poland,  
TEL: +48 12 4248584; FAX: +48 12 4248584,  
E-MAIL: mowicher@cyf-kr.edu.pl

*Submitted:* 2008-03-28 *Accepted:* 2008-06-20 *Published online:* 2008-08-30

*Key words:* CD34; MVD; invasive ductal breast cancer

Neuroendocrinol Lett 2008; 29(4):443-446 PMID: 18766141 NEL290408A22 © 2008 Neuroendocrinology Letters • www.nel.edu

## Abstract

**BACKGROUND:** Angiogenesis is a basic process that enables neoplasms to thrive. Microvessel density (MVD) evaluation is an accepted parameter for assessing the angiogenesis process within a tumor. The aim of the present study has been to assess the number of microcapillaries in both invasive ductal breast cancer with the presence of metastases in regional lymph nodes and in invasive ductal breast cancer without such metastases.

**METHODS:** The CD34 antigen immunoreactivity level was assessed by immunohistochemistry in both types of invasive ductal breast cancer. Tissue samples were obtained from 40 patients and were divided into two groups according to whether or not there were lymph node metastases.

**RESULTS:** The patients with lymph node metastases exhibited statistically significantly higher numbers of stained microcapillaries than the patients who did not have lymph node metastases.

**CONCLUSION:** Thus the number of stained microcapillaries as evaluated by using the CD34 immunoreactivity level seems to be a useful predictor for the development of local lymph node metastases in female invasive ductal breast cancer.

## INTRODUCTION

Angiogenesis is a basic process that enables neoplasms to thrive [1]. Microvessel density (MVD) evaluation is an accepted parameter for assessing the angiogenesis process within a tumor. MVD can be immunohistochemically evaluated by using anti-CD34 antibodies. The CD34 antigen is a membrane glycoprotein expressed by myeloid precursor cells and by small vessel endothelial cells [2]. In ductal *in situ* breast carcinoma a correlation has been found between MVD and local tumor invasion [3]. Normal glandular breast tissue is typified by lower MVD than DCIS whereas invasive ductal breast cancer is typified by higher MVD than DCIS [4]. A connection between the CD34 immunoreactivity level and a poor prognosis for a case has been established [5]. The presence of lymph node metastases is also a poor prognostic factor. The evaluation of MVD using the CD34 antigen immunoreactivity level in male breast cancer has not revealed any relationship between MVD and the presence of local lymph node metastases [6]. Such a relationship has, however, been demonstrated in both uterine cervical carcinoma and laryngeal cancer [7, 8].

The aim of the present study has been to assess the number of microcapillaries in invasive ductal breast cancer with the presence of metastases in regional lymph nodes and in invasive ductal breast cancer where there are no such metastases.

## MATERIAL AND METHODS

### 2.1. The subjects

The informed consent of each patient for the use of placental tissue was obtained. Additionally, the approval of the Ethical Committee of the Jagiellonian University in Krakow (KBET/379/13/2003) was granted for this re-

search program. The patients in this study were randomly selected. The surgically removed material was evaluated to determine the histological type and metastases of the lymph nodes using histological methods in the Department of Pathomorphology of the Jagiellonian University. We assessed the total immunoreactivity of the CD34 antigen level in 40 breast cancer tissue specimens. The women from whom the specimens were obtained ranged in age from 44 to 68 years (mean age, 49 years). All the women had undergone mastectomies with axillary lymphadenectomies in the 1st Department of General Surgery of the Jagiellonian University. Invasive carcinoma was a dominant component in each case. The surgically removed material was fixed in a 10% buffered formalin. The tissue was then embedded in paraffin and stained with hematoxylin and eosin. Each specimen was inspected in order to measure tumor size and a number of lymph nodes was obtained for further study. Microscopic examination was performed to identify the histological type and grade of invasive carcinoma, the presence of vessel invasion, and tumor metastases to the lymph nodes. Histological grades of invasive carcinoma were diagnosed according to the Bloom and Richardson classification modified by Elston and Ellis and recommended by the National Coordinating Group for Breast Pathology [9].

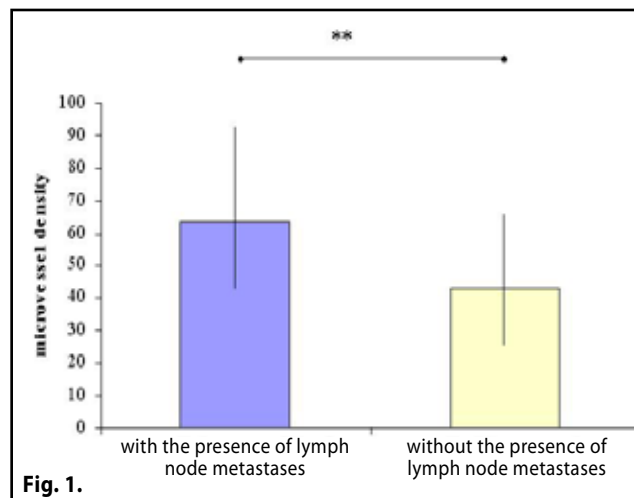
### 2.2. Immunohistochemical staining and analysis of CD34 antigen level.

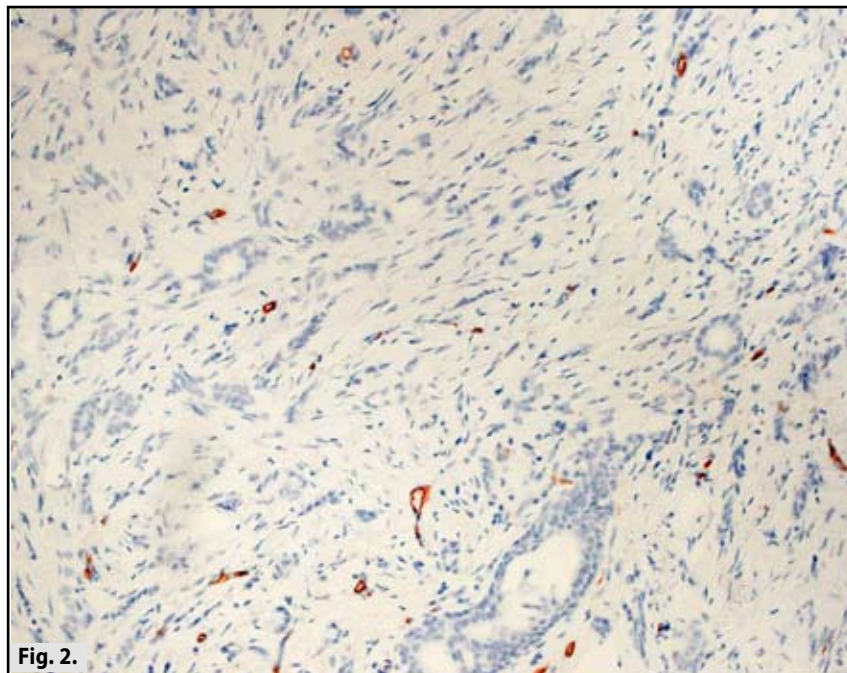
Immunohistochemistry was carried out in paraffin-embedded specimens of representative malignant tumor tissue fixed in a 10% butter formalin. For the purpose of endothelial cell visualization, anti-CD-34 monoclonal antibodies (DAKO) at 1:25 dilution were added and incubated for 30 minutes at room temperature. Microscopic analysis of immunohistochemically stained tissue specimens was performed by light microscope. At 40x magnification, the tumor regions with the highest

**Table 1.** The number of stained microcapillaries relevant to histological grades according to Bloom and Richardson classification in 40 patients with invasive ductal breast cancer.

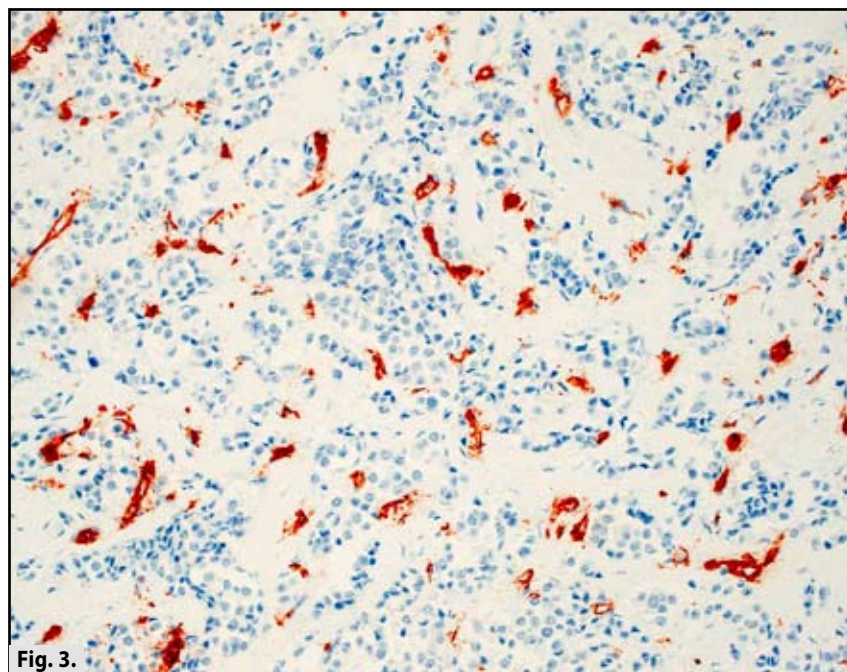
	G1 (n=10)	G2 (n=15)	G3 (n=15)
Average number of microcapillaries	63.1	59.93	57.26
Standard deviation	33.26	25.85	37.09

**Figure 1.** The number of stained microcapillaries in the patients with and without the presence of lymph node metastases (\*\* p<0.05).





**Figure 2.** Immunoreactivity of the CD34 antigen level in invasive ductal breast cancer without lymph node metastases



**Figure 3.** Immunoreactivity of the CD34 antigen level in invasive ductal breast cancer with lymph node metastases

numbers of stained microcapillaries were chosen. Each time the number of microcapillaries in 10 randomly chosen fields was evaluated. Every stained endothelial cell or group of cells separated from adjacent tumor cells or elements of soft tissue was treated as a separate, single vessel; however, the existence (or absence) of an aperture in the examined capillary was not considered.

### 2.3 Statistical analysis

The distribution of variables in the study groups of women checked with the use of the Shapiro-Wilk test showed that all of them were different from normal. Therefore, nonparametric testing was employed. The statistical significance between the groups was determined by the Kruskal-Wallis analysis of variance (ANOVA) test. The Mann-Whitney U test was then used as applicable.

## RESULTS

The presence of the CD34 antigen was identified in all tissue samples derived from patients with invasive ductal breast cancer. The patients were divided into two main groups according to whether or not they suffered from lymph node metastases. The patients with lymph node metastases had statistically significantly lower breast cancer cell differentiation according to the Bloom scale when compared to those patients without metastases ( $p=0.03$ ). We did not observe any statistically significant differences in clinical parameters (average age, body mass index, etc.) among the groups examined, and this fact enabled us to compare the CD34 immunoreactivity level in the groups.

The number of stained microcapillaries was analyzed with respect to histological grades according to the Bloom and Richardson classification, and no statistically significant differences were observed between the analyzed subgroups (G1,G2,G3) of patients (Table 1).

Statistically significantly higher numbers of stained microcapillaries were observed in patients with lymph node metastases when compared to the numbers in patients without metastases ( $p=0.02$ ) (Figure 1).

## DISCUSSION

In our study, the patients with the presence of lymph node metastases exhibited statistically significantly higher numbers of stained microcapillaries than the patients without lymph node metastases (Figure 2, Figure 3). The relationship between the presence of lymph node metastases and an increase in MVD within the tumor has been confirmed in cervical, laryngeal, and gastric cancers [7,8,10]. No relationship between the presence of lymph node metastases and an increase in MVD has been established in cases of male breast cancer [6]. In female invasive ductal breast cancer, however, an increase in MVD has been correlated with a poor prognosis [11], and this would seem to confirm the results obtained in the present study. *Bono et al.* have observed that an increase in lymphatic vessel density in the tumor microenvironment correlates with breast cancer progression [5]. The absence of the CD44 antigen that typifies the increase in microvessel density in tumor cells has also been found in cases with lymph node metastases [12]. Similarly, microvessel quantity by factor VIII-related antigen staining has been shown to be higher in cases with lymph node metastases than those without [11].

The present study has had certain apparent limitations. First, the limited number of patients included did not allow us to evaluate the influence of other factors on prognosis. Second, the immunohistochemistry technique introduced a degree of subjectivity. We reduced

the impact of these problems by comparing the patients on whom one of two types of surgical procedures were performed, and the patients in each group did not differ with respect to clinical parameters. The possibility of subjectivity entering into the immunohistochemistry assessment was diminished by having two independent pathologists evaluate the tissue slides.

## CONCLUSION

The number of stained microcapillaries as evaluated by the CD34 immunoreactivity level seems to be a useful predictor for the development of local lymph node metastases in female invasive ductal breast cancer.

## Acknowledgments

We wish to thank Professor W. Nowak. We would also like to thank Professor A. Basta for his advice, helpful discussions, and friendly words of support. This work was supported by Polish Ministry of Science, Grant Number N403 032 31/2079.

## REFERENCES

- 1 Folkman J. Seminars in Medicine of the Beth Israel Hospital, Boston. Clinical applications of research on angiogenesis. *N Engl J Med* 1995; **333**(26): 1757–1763.
- 2 Kuzu I, Bicknell R., Harris AL, Jones M, Gatter KC, Mason DY. Heterogeneity of vascular endothelial cells with relevance to diagnosis of vascular tumours. *J Clin Pathol* 1992; **45**(2): 143–148.
- 3 Teo NB, Shoker BS, Jarvis C, Martin L, Sloane JP, Holcombe C. Vascular density and phenotype around ductal carcinoma in situ (DCIS) of the breast. *Br J Cancer* 2002; **86**(6): 905–911.
- 4 Teo NB, Shoker BS, Jarvis C, Martin L, Sloane JP, Holcombe C. Angiogenesis and invasive recurrence in ductal carcinoma in situ of the breast; *Eur J Cancer* 2003; **39**(1): 38–44.
- 5 Bono P, Wasenius V, Heikkilä P, Lundin J, Jackson D G, Joensuu H. High LYVE-1-Positive Lymphatic Vessel Numbers Are Associated with Poor Outcome in Breast Cancer. *Clin Cancer Res* 2004; **10**(21): 7144–7149.
- 6 Frangou EM, Lawson J, Kanthan R. Angiogenesis in male breast cancer. *World J Surg Oncol* 2005; **3**(1): 16.
- 7 Vieira SC, Silva BB, Pinto GA, Vassallo J, Moraes NG, Santana JO, Santos LG, Carvasan GA, Zeferino LC. CD34 as a marker for evaluating angiogenesis in cervical cancer. *Pathol Res Pract* 2005; **201**(4): 313–318.
- 8 Gryczynski M, Papierz W, Niewiadomska H, Kobos J, Pietruszewska W. Evaluation of CD44 adhesion molecule, nm 23 gene product expression and intensity of angiogenesis in patients with laryngeal cancer. *Otolaryngol Pol* 2000; **54**(6): 669–674.
- 9 Bloom HJ, Richardson WW. Histological grading and prognosis in breast cancer; a study of 1409 cases of which 359 have been followed for 15 years. *Br J Cancer* 1957; **11**(3): 359–377.
- 10 Wang L, Zhang LH, Li YL, Li YL, Liu Z. Expression of MMP-9 and MMP-9 mRNA in gastric carcinoma and its correlation with angiogenesis. *Zhonghua Yi Xue Za Zhi* 2003; **83**(9): 782–786.
- 11 Bosari S, Lee AK, Delellis RA, Wiley BD, Heatley GJ, Silverman ML. Microvessel quantitation and prognosis in invasive breast carcinoma. *Hum Pathol* 1992; **23**(7): 755–761.
- 12 Gong Y, Sun X, Huo L, Wiley EL, Rao MS. Expression of cell adhesion molecules, CD44s and E-cadherin, and microvessel density in invasive micropapillary carcinoma of the breast. *Histopathology* 2005; **46**(1): 24–30.