

Lateral sinus thrombosis and intracranial hypertension associated with primary hypothyroidism

Qin CHEN, Zhi-Ping YAO, Dong ZHOU, Hong-Bo ZHENG and Hui-Fang SHANG*

Department of Neurology, West China Hospital, Sichuan University, 610041, Chengdu, SiChuan, China.

Correspondence to: Hui-Fang Shang, M.D. Department of Neurology, West China Hospital, Sichuan University, 610041, Chengdu, SiChuan, China.
TEL: 0086-02881812682, FAX: 0086-02885422549
EMAIL: hfshang@yahoo.com

Submitted: 2007-03-02 *Accepted:* 2007-10-30 *Published online:* 2008-02-22

Key words: **cerebral venous sinus thrombosis (CVT); hypothyroidism; intracranial hypertension; Digital subtraction angiography (DSA)**

Neuroendocrinol Lett 2008;29(1):41-43 PMID: 18283254 NEL290108C03 © 2008 Neuroendocrinology Letters • www.nel.edu

Abstract

Several cases of hypothyroidism have been reported to develop idiopathic intracranial hypertension not directly precisely linked with cerebral venous sinus thrombosis (CVT). A 31-year-old Chinese woman presented with bilateral blurred vision and paroxysmal amaurosis for about 6 months without headache. Neurological examination revealed normal expect for the sixth cranial nerve palsy and bilateral papilledema. Laboratory tests showed pronounced hypothyroidism and greatly increased serum triglyceride. Cerebral spinal fluid showed the increased opening and closing pressure. Digital subtraction angiography (DSA) disclosed a filling defect in the adjunction of bilateral transverse sinuses and sigmoid sinuses. Her symptoms gradually improved with levothyroxine, mannitol and anticoagulants treatment. In presenting the rare case of lateral sinus thrombosis associated with primary hypothyroidism, we wish to alert physicians that patients presenting with papilledema and hypothyroidism may require investigations of DSA for CVT, even in the absence of headache.

Abbreviations:

CVT - Cerebral venous sinus thrombosis
DSA - Digital subtraction angiography
LST - lateral sinus thrombosis
TSH - thyrotropic-stimulating hormone
T3 - triiodothyronine,
T4 - tetraiodothyronine
fT4 - free triiodothyronine
fT4 - free tetraiodothyronine
PT - prothrombin time
APTT - activated partial thromboplastin time,
CSF - Cerebrospinal fluid

headache and intracranial hypertension. CVT is often associated with systemic diseases such as hemotologic disorders, autoimmunologic disorders, coagulopathies, infectious diseases, systemic inflammatory diseases, oral contraceptives and dehydration, and with local lesions such as tumors, infections and trauma or with pregnancy (Stam 2005). Among CVT, thrombosis of the lateral sinus thrombosis (LST) is usually secondary to local processes including otitis media and mastoiditis (Manolidis et al. 2005).

Thyroid hormone has been studied in cardiovascular disease but rarely in cerebrovascular disease. A hypercoagulable state has been demonstrated in patients with hypothyroidism in several studies (Alturfan et al. 2006, Erem 2006). Recently,

INTRODUCTION

Cerebral venous sinus thrombosis (CVT) is an infrequent but potentially fatal condition, presenting variant clinical manifestations, mostly with

acute ischemic stroke has been documented to be associated with hypothyroidism (Sun et al. 2006). However, to our knowledge, the association of hypothyroidism and CVT has not been reported before. Here, we describe, a patient of LST associated with primary hypothyroidism, whose symptoms of intracranial hypertension improved with thyroxine substitution and anti-coagulant therapy.

CASE

A 31-year-old Chinese woman presented with about 6 months of bilateral blurred vision and paroxysmal amaurosis lasting less than 1 minute without headache, nausea or vomiting. The patient did not complain of amenorrhea, galactorrhea, polydipsia, polyuria or pretibial edema. Five years before admission, she underwent Iodine-131 ablation treatment because of hyperthyroidism, and in the following three years, the annual investigation of thyroid function was within normal limit. She denied any family history of hyperthyroidism or thrombosis diseases.

On examination, she was alert and cooperative. Her temperature was 37°C, pulse 80 beats /min, and supine blood pressure 124/78 mmHg. Vision acuities were 12/20 OD and OS. Visual fields were intact. The fundoscopic examination revealed bilateral papilledema without hemorrhage or exudates. Neurological examination revealed normal except for the sixth cranial nerve palsy. There was neither thyromegaly nor myxedema. Laboratory tests showed markedly abnormal thyroid function: thyrotropic-stimulating hormone (TSH) 39.510 mu/L (reference: 0.3-5.0), triiodothyronine (T3) 0.76nmol/L (reference 1.30-3.10), tetraiodothyronine (T4) 37.44nmol/L (reference 68-172), free triiodothyronine (fT3) 1.25pmol/L (reference 3.6-7.5) and free tetraiodothyronine (fT4) 5.03 pmol/L (reference 13.0-23.0). Hematological and coagulation indices including platelet count, prothrombin time (PT), activated partial thromboplastin time (APTT) and fibrinogen were normal. Serum triglyceride level of 7.91mmol/L was greatly above normal (0.25–1.83mmol/L). Lumbar puncture revealed that opening pressure was more than 25cm of water. Cerebrospinal fluid (CSF) tests demonstrated cell count and protein within normal and absence of oligoclonal bands.

Brain MRI scan without contrast revealed normal. Digital subtraction angiography (DSA) disclosed a filling defect in the adjunction of bilateral transverse sinuses and sigmoid sinuses (Figure 1). Other investigations excluded infectious disease, malignances and cardiac diseases. Diagnosis of lateral sinus thrombosis, primary hypothyroidism, intracranial hypertension and hypertriglyceridemia were made. The frequency and duration of the paroxysmal amaurosis gradually decreased with levothyroxine (Euthyrox 50 ug/day), mannitol and anticoagulants (Nadroparin Calcium, 0.4ml iH q12h) treatment for 14 days. Her vision acuities turned to

be normal and paroxysmal amaurosis disappeared with Warfarin (2.5mg/day) replacing Nadroparin Calcium treatment for six months under monitoring the International Normalized Ratio (INR, between 2–3).

DISCUSSION

To our knowledge, this is the first reported case of bilateral LST and intracranial hypertension associated with primary hypothyroidism, supported by DSA and laboratory tests. However, the association between LST formation and hypothyroidism is poorly understood.

In our patient, with MRI and blood tests, we excluded otitis media and mastoiditis which is the most common cause of LST (Manolidis et al. 2005), as well as mass brain lesions and other systematic diseases such as anemia. Based on the constellation of symptoms and findings, we suspected that LST in the present patient is likely to be associated with the homeostasis changes induced by primary hypothyroidism.

The influence of hypothyroidism on homeostasis is complex and still not very well understood. Previous reports have demonstrated that hypothyroidism was associated with the progression of atherosclerosis and thrombotic tendency by both autoimmune mechanism and thyroid dysfunction (Marongiu et al. 1992, Marongiu et al. 2004, Squizzato et al. 2005). More recently, a hypercoagulable state, which might represent a risk factor for thromboembolic disease, has been highlighted in patients with hypothyroidism (Alturfan et al. 2006, Erem 2006, Guldiken et al. 2005). High procoagulant factors, such as decreased von Willbrand factor, increased tissue factor, increased activated factor VII and PAI-1, as well as increased plasma homocysteine (Alturfan et al. 2006, Erem 2006, Marongiu et al. 1992, Muller et al. 2001), may cause a net effect of a hypercoagulable state, which can directly influence the progression of thrombosis. Furthermore, hypercholesterolemia, hypertriglyceridemia and hypertension, the common complications of hypothyroidism also play roles in the development of thrombosis formation (Marongiu et al. 2004). In present patient, we suggest that both the hypercoagulable state and hypertriglyceridemia may have contributed to the development of the LST, while more cases needed in the future study.

However, Elevated CSF protein resulting from hypothyroidism was reported to cause intracranial hypertension (Frost et al. 2004). However, no elevated CSF protein level was found in our patient. On the other hand, idiopathic intracranial hypertension, which was excluded in the patient by DSA, has been reported to concur with primary hypothyroidism (Adams et al. 1994, Giuseffi et al. 1991, Radhakrishnan et al. 1986). Since magnetic resonance venography (MRV) and DSA investigation were not preformed in these reports, the frequency of sinus thrombosis as the cause of the intracranial hypertension associated with primary hypothyroidism may have been underestimated.

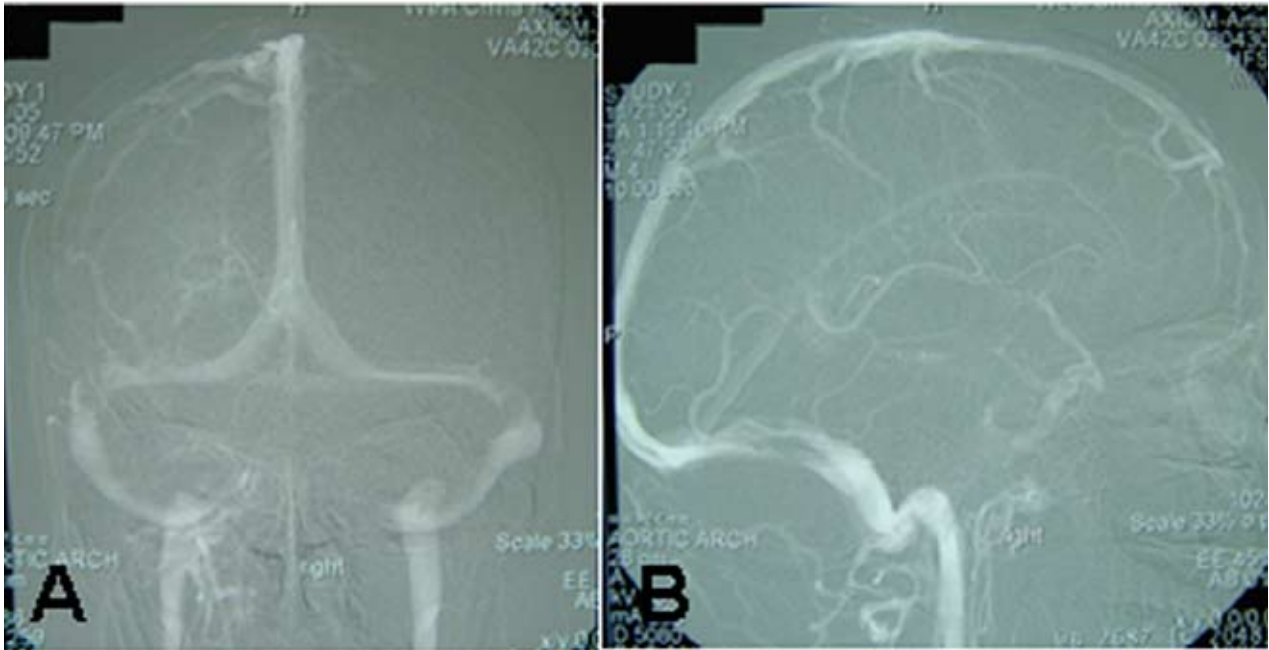


Figure 1: A filling defect in the adjunction of bilateral transverse sinuses and sigmoid sinuses were disclosed by DSA.

In presenting the rare case of LST associated with primary hypothyroidism, physicians should be aware of LST in patients of hypothyroidism with symptoms of intracranial hypertension. Investigations of MRV, especially DSA may be necessary in such patients because the need of treatment, which will affect significantly the prognosis. Prompt treatment with intravenous heparin and levothyroxine is potentially effective. In addition, further studies of the possible association of thyroid hormone and CVT are warranted.

REFERENCE

- Adams C, Dean HJ, Israels SJ, Patton A, Fewer DH, (1994). Primary hypothyroidism with intracranial hypertension and pituitary hyperplasia. *Pediatr Neurol.* **10**: 166–168.
- Alturfan AA, Alturfan EE, Dariyerli N, Zengin E, Aytac E, Yigit G, et al., (2006). Investigation of tissue factor and other hemostatic profiles in experimental hypothyroidism. *Endocrine.* **30**: 63–67.
- Erem C, (2006). Blood coagulation, fibrinolytic activity and lipid profile in subclinical thyroid disease: subclinical hyperthyroidism increases plasma factor X activity. *Clin Endocrinol (Oxf).* **64**: 323–329.
- Frost N, Lee MS, Sweeney P, (2004). Myxedema, papilledema, and elevated CSF protein. *Neurology.* **63**: 754–755.
- Giuseffi V, Wall M, Siegel PZ, Rojas PB, (1991). Symptoms and disease associations in idiopathic intracranial hypertension (pseudotumor cerebri): a case-control study. *Neurology.* **41**: 239–244.
- Guldiken S, Demir M, Turgut B, Altun BU, Arikan E, Kara M, (2005). Global fibrinolytic capacity in patients with subclinical hypothyroidism. *Endocr J.* **52**: 363–367.
- Manolidis S, Kutz JW, (2005). Diagnosis and management of lateral sinus thrombosis. *Otol Neurotol.* **26**: 1045–1051.
- Marongiu F, Biondi G, Conti M, Murtas ML, Mameli G, Sorano GG, et al., (1992). Is a hypercoagulable state present in hypothyroidism? *Thromb Haemost.* **67**: 729.
- Marongiu F, Cauli C, Mariotti S, (2004). Thyroid, hemostasis and thrombosis. *J Endocrinol Invest.* **27**: 1065–1071.
- Muller B, Tsakiris DA, Roth CB, Guglielmetti M, Staub JJ, Marbet GA, (2001). Haemostatic profile in hypothyroidism as potential risk factor for vascular or thrombotic disease. *Eur J Clin Invest.* **31**: 131–137.
- Radhakrishnan K, Sridharan R, Ashok PP, Mousa ME, (1986). Pseudotumor cerebri: incidence and pattern in North-Eastern Libya. *Eur Neurol.* **25**: 117–124.
- Squizzato A, Gerdes VE, Brandjes DP, Buller HR, Stam J, (2005). Thyroid diseases and cerebrovascular disease. *Stroke.* **36**: 2302–2310.
- Stam J, (2005). Thrombosis of the cerebral veins and sinuses. *N Engl J Med.* **352**: 1791–1798.
- Sun MY, Chen TC, Lee YL, (2006). Hypothyroidism and cerebral infarction: a case report and literature review. *Acta Neurol Taiwan.* **15**: 197–200.