

# Early effects of treatment on regional cerebral blood flow in first episode schizophrenia patients, evaluated with <sup>99</sup>Tc-ECD-SPECT

Brigita Novak<sup>1</sup>, Metka Milcinski<sup>2</sup>, Marko Grmek<sup>2</sup> & Margareta Kocmur<sup>1</sup>

<sup>1</sup> University Psychiatric Hospital, Ljubljana, Slovenia.

<sup>2</sup> Department of Nuclear Medicine, University Medical Centre, Ljubljana, Slovenia.

*Correspondence to:* Prof Margareta Kocmur, MD, PhD  
University Psychiatric Hospital,  
Studenec 48, 1260 Ljubljana - Polje, SI-SLOVENIA.  
PHONE: +386-1-5222469; FAX: +386-1-2302899;  
EMAIL: [marga.kocmur@psih-klinika.si](mailto:marga.kocmur@psih-klinika.si)

*Submitted:* October 14, 2005

*Accepted:* October 25, 2005

*Key words:* **regional cerebral brain perfusion; schizophrenia; brain single-photon emission tomography; bicisate; antipsychotic therapy**

Neuroendocrinol Lett 2005; **26**(6):685-689 PMID: 16380684 NEL260605A28 © Neuroendocrinology Letters [www.nel.edu](http://www.nel.edu)

## Abstract

**OBJECTIVES:** Altered regional cerebral blood flow (r-CBF) is mentioned as one of possible etiological factors or as a consequence of schizophrenia. Perfusion scintigraphic brain studies with SPECT (Single Photon Emission Computed Tomography) and PET (Positron Emission Tomography) can detect areas of the brain with altered perfusion during the disease. Conflicting data exist on follow-up after treatment. The aim of our study was to evaluate r-CBF in acute first-episode schizophrenia and early effect of antipsychotic drugs on r-CBF.

**DESIGN AND SETTING:** Clinical criteria for schizophrenia were met according to International Classification of Diseases – 10<sup>th</sup> Edition (ICD-10). Psychic status and severity of the disease in each patient were evaluated with psychiatric interview, Positive and Negative Syndrome Scale (PANSS) and Clinical Global Impression (CGI) on the same day as the scintigraphic study. Brain perfusion SPECT was performed 20 minutes after <sup>99m</sup>Tc-ECD application. R-CBF was measured in 9 first-episode schizophrenic male patients 2–7 (median 6) days after the beginning of antipsychotic treatment and 8–15 (median 9) weeks later. Semiquantitative analysis of r-CBF was performed with cerebellum as the reference region. R-CBF was evaluated for 12 regions in each study.

**RESULTS:** Decrease in perfusion in comparison to cerebellum was detected in left (90 %) and right (93 %) frontal lobes. Increase in perfusion between the first (t1) and the second (t2) investigation was significant (p<0.05) for both frontal regions (left 94 %, right 97 %). Significant decrease in PANSS (p<0.05) and CGI (p<0.001) scores was noted and correlated well with the increase of r-CBF.

**CONCLUSIONS:** Our findings implicate that patients with first-episode schizophrenia have significant left hypoperfusion relative to the right in dorsolateral frontal lobes. Increased blood flow was observed bilaterally in dorsolateral frontal lobes after 10 weeks of antipsychotic medication. Significant amelioration of r-CBF correlated with clinical improvement.

#### Abbreviations and units:

<b>99mTc</b>	- technetium
<b>CGI</b>	- Clinical Global Impression
<b>ECD</b>	- ethyl cysteinate dimer
<b>ICD-10</b>	- International Classification of Diseases – 10th Edition
<b>MBq</b>	- Mega Becquerel
<b>PANSS</b>	- Positive and Negative Syndrome Scale
<b>PET</b>	- Positron Emission Tomography
<b>r-CBF</b>	- regional cerebral blood flow
<b>ROI</b>	- region of interest
<b>SPECT</b>	- Single Photon Emission Computed Tomography

## Introduction

Schizophrenia is among the most severe and debilitating of psychiatric disorders. Diagnosis is currently by criterion-based systems, including positive (eg, hallucinations and delusions) and negative (eg, avolition and alogia) symptoms.

Etiology of schizophrenia is still unknown. Perfusion scintigraphic brain studies with SPECT and PET are providing further insights into the pathophysiological mechanisms. Impairment of frontal r-CBF [14,35,18,4,19] as well as increased frontal r-CBF were found [5,7,33]. Studies showed also abnormalities in temporal lobes [5,23], parietal lobes [7] and in the basal ganglia [32]. The discrepancies among the studies have been attributed also to the differences in duration of illness, medication status, methods of brain imaging and symptom profile.

Antipsychotic drug treatment is known to influence both cerebral perfusion and metabolism [35,11], but studies show inconsistent results.

Aim of this study was to evaluate regional cerebral blood flow (r-CBF) in acute first-episode schizophrenia and early effect of antipsychotic drugs on r-CBF.

## Patients and methods

### *Patient selection*

The study protocol was approved by Slovenian ethical committee. Informed consent was obtained from each patient prior to his inclusion into the study.

Clinical criteria for schizophrenia were met according to International Classification of Diseases – 10th Edition (ICD-10) [36]. Patients with schizophreniform disorders, schizoaffective disorders and bipolar mood disorders were excluded from the study. Further exclusion criteria were organic brain disorders, age <18 or >55, a general neurological or medical disease, history of severe head trauma, drug/alcohol abuse, prior treatment with psychoactive substances and severe agitation. Only male patients were included because of potential pregnancy of female patients.

Psychopathological status and severity of disease in each patient were evaluated with PANSS (Positive and Negative Syndrome Scale), [15] and CGI scale (Clinical Global Impression), [22] on the same day as the scintigraphic study. PANSS has 30 items on a scale from 1–7 points (normal to extremely abnormal), with subscores for 7 positive, 7 negative and 16 global psychopatho-

logical symptoms. CGI assesses the severity of disease on a scale from 1–7 points (absence to maximum).

Nine inpatients met the inclusion criteria. Age of patients was 20–53 years (median 30). Duration of disease before the first evaluation was 2–3650 days (median 60).

The first series of examination was performed as soon after admission as possible, 2–7 days (median 6) after the beginning of antipsychotic treatment. Three patients were treated with olanzapin (Zyprexa), 3 with risperidon (Risperdal) and 3 with fluphenazin (Moditen). The follow-up series were performed on 7 patients 8–15 (median 9) weeks after the first examination. The same therapy was continued.

### *Scintigraphic acquisition and data analysis*

Scintigraphic protocol for first and follow-up investigation was the same.

Patient received 600 MBq of 99mTc ethyl cysteinate dimer (ECD) 10 min after vein cannulation. At the time of tracer injection patients were lying comfortably with their eyes closed in a semi-darkened room with environmental noise kept to a minimum. Data acquisition started 20 min after that on double-head gamma camera (Siemens Multispect II) equipped with low energy fan-beam collimator. The camera was aligned parallel to orbitomeatal line. Acquisition parameters were 180 (2 x 90) frames, 20 sec. per frame, 128 x 128 matrix, 1.23 zoom, 360° rotation. Reconstruction was performed using a Butterworth filter of 7th order with a cut-off frequency of 0.45. Chang [6] attenuation correction was applied.

Commercial software (Icon II) was used for analysis. Thickness of brain slices was 7.8 mm, intensity threshold was set at 45%.

The cerebellum was used as the reference area for relative uptake calculation of the next brain regions: frontal lobe 1 (F1) = dorsolateral part of the right and left frontal lobe in the fronto-occipital line in the same level as the basal ganglia; frontal lobe 2 (F2) = dorsolateral part of the right and left frontal lobe 16 mm above the F1; temporal lobe 1 (T1) = anterior part of the right and left temporal lobe; temporal lobe 2 (T2) = postero-superior part of the right and left temporal lobe; temporal lobe 3 (T3) = postero-inferior part of the right and left temporal lobe; temporal lobe 4 (TL) = lateral part of the right and left temporal lobe.

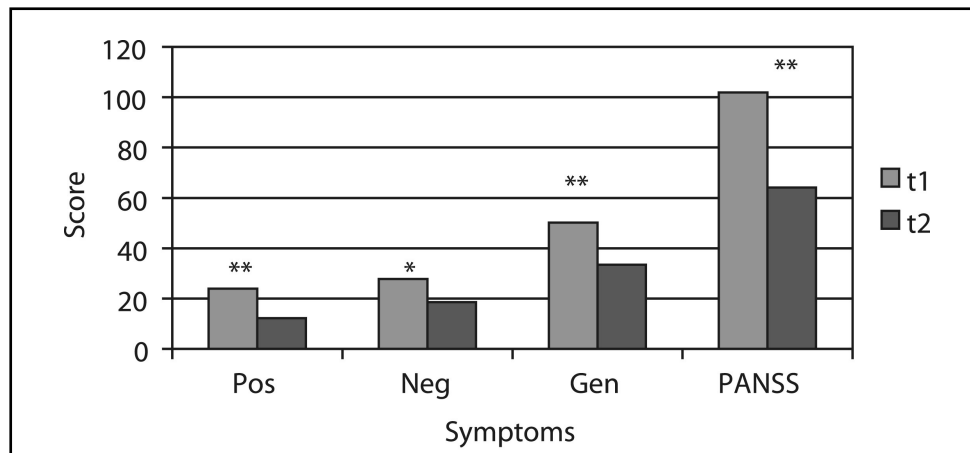
### *Statistical analysis*

Mean values, standard deviation and t test were calculated when appropriate.  $P < 0.05$  was considered statistically significant.

## Results

### *PANSS scores*

Clinical improvement was noted in all patients after antipsychotic treatment. The sum score of negative symptoms evaluated with PANSS reduced significantly ( $p < 0.05$ ) while the sum scores of positive and general



**Figure 1.** PANSS scores at the beginning of antipsychotic treatment (t1) and 10 weeks later (t2) in patients with first episode schizophrenia  
PANSS: Positive and Negative Syndrome Scale; Pos: positive symptoms in PANSS; Neg: negative symptoms in PANSS; Gen: general symptoms in PANSS. \*  $p < 0.05$ ; \*\*  $p < 0.005$ .

**Table 1.** Regional cerebral blood flow (r-CBF) at the beginning of antipsychotic treatment (t1) and 10 weeks later (t2) in patients with first episode schizophrenia

ROI	t1 mean $\pm$ S.D.	t2 mean $\pm$ S.D.	p value
RF1	95.6 $\pm$ 4.3	95.1 $\pm$ 5.2	0.48
LF1	94.3 $\pm$ 4.2	93.1 $\pm$ 7.1	0.639
<b>RF2</b>	<b>93.4 <math>\pm</math> 4.6</b>	<b>96.9 <math>\pm</math> 5.8</b>	<b>0.023*</b>
<b>LF2</b>	<b>90.1 <math>\pm</math> 4.4</b>	<b>94.1 <math>\pm</math> 5.2</b>	<b>0.015*</b>
RTL	88.8 $\pm$ 3.1	88.9 $\pm$ 3.3	0.366
LTL	90.2 $\pm$ 3.2	88.4 $\pm$ 5.9	0.645
RT1	88.0 $\pm$ 6.4	87.9 $\pm$ 8.0	0.756
LT1	87.0 $\pm$ 7.0	85.9 $\pm$ 5.6	0.483
RT2	81.2 $\pm$ 3.8	83.1 $\pm$ 2.9	0.164
RT3	88.4 $\pm$ 3.9	87.4 $\pm$ 3.7	0.642
LT2	81.9 $\pm$ 2.9	81.6 $\pm$ 5.0	0.075
LT3	90.7 $\pm$ 3.2	88.0 $\pm$ 6.1	0.541

ROI: region of interest; R: right; L: left; F1: frontal lobe, horizontal slice through basal ganglia; F2: frontal lobe 16 mm above the F1; TL: lateral part of temporal lobe; T1: anterior part of temporal lobe; T2: postero-superior part of temporal lobe; T3: postero-inferior part of temporal lobe. \*  $p < 0.05$ .

psychopathological symptoms reduced very significantly ( $p < 0.005$ ) (Figure 1).

#### *r-CBF scores*

Decrease in perfusion was detected in left (90 %) and right (93 %) dorsolateral frontal lobes on the first series of examination, with left hypoperfusion relative to the right. Increased blood flow was observed bilaterally in dorsolateral frontal lobes after 10 weeks of medication. Increase in perfusion between the first (t1) and the second (t2) investigation was significant ( $p < 0.05$ ) for both frontal regions (left 94 %, right 97 %) (Table 1).

## Discussion

### *PANSS scores in schizophrenic patients before and after antipsychotic treatment*

Clinical improvement was noted after antipsychotic treatment with lower scores on PANSS scale in all

patients. Reduction of positive and global psychopathological symptoms was noted as well as reduction of negative symptoms. No significant correlations were observed between psychopathological symptoms in PANSS sub-scores and regional abnormalities of r-CBF.

### *R-CBF in drug naive schizophrenic patients*

Various r-CBF patterns have been described in schizophrenic patients and were attributed to different factors, one of them the medication status of the patients [10]. However, even in studies of r-CBF in drug naive patients, different changes in r-CBF were described [37]. Sabri et al. [29] detected both frontal hypo- and hyperperfusion in drug naive schizophrenic patients with left side lateralization. Temporal, predominantly left side hypoperfusion was also described in schizophrenic patients before therapy [28].

Results of our study in drug-naïve schizophrenics – hypo-perfusion of upper left dorsolateral frontal lobe relative to the right side – are in concordance with some studies that also showed hypofrontality in acute, first episode, drug naïve schizophrenic patients [3,1,2,30,11]. However, some studies found increased frontal r-CBF [5,7,33,34] or found no significant change in r-CBF in frontal lobes [13,12,9,10,26]. Studies with PET allowed investigation of cerebral blood flow in more details and evaluated perfusion separately for positive or negative symptoms [20,25]; or assess cognitive impairment of brain and attribute lower cerebral regional flow to dysfunctional circuits [1]. Schizophrenic patients with predominantly negative symptoms have greater metabolic abnormalities than patients with predominantly positive symptoms [25]. The small number of patients in our study did not allow us to separate the ones with positive and negative symptoms.

#### *R-CBF in schizophrenic patients after therapy*

Reversal of perfusion abnormalities was seen in our patients after 10 weeks of treatment with antipsychotic drugs. Hypoperfusion of upper left dorsolateral frontal lobe relative to the right side was no more statistically significant. Increase of blood flow was observed bilaterally in frontal lobes. Clinical improvement was noted with lower scores on PANSS scale.

The data regarding the effects of antipsychotic medication on r-CBF or metabolism are not yet clear. Various functional imaging studies have examined the relationship between antipsychotic medication status and brain metabolism or blood flow in subjects with schizophrenia [8]. The results of these investigations have been somewhat variable, with the most consistent finding being that of increased metabolism in the basal ganglia during the medicated versus non-medicated state [21]. Although one study [16] found lower prefrontal and higher thalamic and cerebellar r-CBF in both drug-naïve and chronically ill patients with schizophrenia, suggesting that these effects were not related to chronicity of illness and were not a consequence of treatment with medication.

#### *Methodological considerations*

No morphologic imaging to detect possible anatomic abnormalities in brain was used in our study. In studies where comparative radiological methods, CT and MRI [29,24,31] were used and comparison to normal data base was used, morphological abnormalities in patients were predominantly seen in left temporal regions with concomitant lower perfusion; in frontal lobes, perfusion was either lower or higher also without concomitant anatomical changes.

In our study, patients were not compared to control population: r-CBF was compared in two consecutive occasions in each patient. We presume that the anatomical situation between both examinations did not change. Furthermore, the known underestimation of high flow and overestimation of low flow with both Tc-99m labelled HMPAO and ECD could lead to further

underestimation of less pronounced flow abnormalities in drug-naïve patients [17]. This does not apply for PET; but PET is not available in our country yet, so we had to use SPECT for cerebral blood flow evaluation.

#### *Data Acquisition, Processing and Analysis*

Possible patient's anxiety and irritation as the reason for nonhomogenous brain perfusion was minimized using quiet room, where patients were relaxed as possible for 10–15 minutes before tracer application, after insertion of intravenous infusion system. They were later accompanied to the acquisition room, and allowed enough time to get familiar with the surrounding; no sedation for acquisition was used. Only once the acquisition had to be repeated because of the patient's movement during acquisition. All other acquisitions were possible after careful explanation of procedure, without patient sedation.

Standard processing was used and Chang attenuation correction was used to optimize technical quality of the studies. The semiquantitative method of blood flow evaluation with SPECT is widely used; cerebellum or average count density of a single slice are the two most common methods. In our study, ROI to cerebellum ratio was used for relative blood flow quantification. Automatic or manual ROI delineation is possible. In the study of Sabri et al. [29], 98 ROI-s were drawn manually and good interobserver repeatability was demonstrated. Such data analysis allows detecting subtle changes in small brain areas. It was used also in some other studies. The method used for ROI delineation in our analysis is more robust, but due to the automatic processing no interobserver variability can be induced. The drawback is that the subtle changes can be missed due to the average count density calculation, as the ROI-s include also subcortical structures.

In conclusion, the major findings of our study are as follows. (1) The upper left dorsolateral frontal lobe was the major site of hypoperfusion in first-episode schizophrenic patients. (2) Increase of blood flow was observed bilaterally in frontal lobes after 10 weeks of drug medication. (3) The severity of psychopathology significantly correlated with cerebral perfusion.

#### **Acknowledgements**

This study was partially funded with a grant from Slovenian research agency (L3-1408-1620-99).

#### REFERENCES

- 1 Andreasen NC, O'Leary DS, Flaum M, Nopoulos P, Watkins GL, Boles Ponto LL, et al. »Hypofrontality« in schizophrenia: distributed dysfunctional circuits in neuroleptic naïve patients. *Lancet* 1997; **349**(9067):1730–34.
- 2 Andreasen NC, Rezai K, Alliger R, Swayze VW 2nd, Flaum M, Kirchner P, et al. Hypofrontality in neuroleptic-naïve patients and in patients with chronic schizophrenia: Assessment with xenon 133 single-photon emission computed tomography and the Tower of London. *Arch Gen Psychiatry* 1992; **49**(12):943–58.

- 3 Buchsbaum MS, Haier RJ, Potkin SG, Nuechterlein K, Bracha HS, Katz M, et al. Frontostriatal disorder of cerebral metabolism in never-medicated schizophrenics. *Arch Gen Psychiatry* 1992; **49**(12):935–42.
- 4 Buchsbaum MS, Ingvar DH, Kessler R, Waters RN, Cappelletti J, van Kammen DP, et al. Cerebral glucography with positron tomography. Use in normal subjects and in patients with schizophrenia. *Arch Gen Psychiatry* 1982; **39**(3): 251–9.
- 5 Catafau AM, Parellada E, Lomeña FJ, Bernardo M, Pavia J, Ros D, et al. Prefrontal and temporal blood flow in schizophrenia: resting and activation technetium-99m-HMPAO-SPECT patterns in young neuroleptic-naive patients with acute disease. *J Nucl Med* 1994; **35**(6):935–41.
- 6 Chang LT. A method for attenuation correction in radionuclide computed tomography. *IEEE Transactions on Nuclear Science* 1978; **25**:638–43.
- 7 Cleghorn JM, Garnett ES, Nahmias C, Firnau G, Brown GM, Kaplan R, et al. Increased frontal and reduced parietal glucose metabolism in acute untreated schizophrenia. *Psychiatry Res* 1989; **28**(2):119–33.
- 8 De Lisi LE, Holcomb HH, Cohen RM, Pickar D, Carpenter W, Marilisa JM, et al. Positron emission tomography in schizophrenic patients with and without neuroleptic medication. *J Cereb Blood Flow Metab* 1985; **5**(2):201–6.
- 9 Early TS, Reiman EM, Raichle ME, Spitznagel EL. Left globus pallidus abnormality in never-medicated patients with schizophrenia. *Proc Natl Acad Sci USA* 1987; **84**:561–3.
- 10 Ebmeier KP, Blackwood DHR, Murray C, Souza v, Walker M, Dougall N, et al. Single-photon emission computed tomography with 99mTc-exametazime in unmedicated schizophrenic patients. *Biol Psychiatry* 1993; **33**(7):487–95.
- 11 Erkwoh R, Sabri O, Steinmeyer EM, Bull U, Sass H. Psychopathological and SPECT findings in never-treated schizophrenia. *Acta Psychiatr Scand* 1997; **96**:51–7.
- 12 Gur RC, Gur RE. Hypofrontality in schizophrenia: RIP. *Lancet* 1995; **345**(8962):1383–84.
- 13 Gur RE, Skolnick BE, Gur RC, Caroff S, Rieger W, Obrist WD, et al. Brain function in psychiatric disorders: I. Regional cerebral blood flow in medicated schizophrenics. *Arch Gen Psychiatry* 1983; **40**(11):1250–54.
- 14 Ingvar DH, Franzen G. Abnormalities of cerebral blood flow distribution in patients with chronic schizophrenia. *Acta Psychiatr Scand* 1974; **50**(4):425–62.
- 15 Kay SR, Fiszbein A, Opler LA. The Positive and Negative Syndrome Scale (PANSS) for schizophrenia. *Schizophr Bull* 1987; **13**:261–76.
- 16 Kim JJ, Mohamed S, Andreasen NC, O'Leary DS, Watkins GL, Boles Ponto, et al. Regional neural dysfunction in chronic schizophrenia studied with positron emission tomography. *Am J Psychiatry* 2000; **157**(4):542–8.
- 17 Koyama M, Kawashima R, Ito H, Ono S, Sato K, Goto R, et al. SPECT imaging of normal subjects with technetium-99m-HMPAO and technetium-99m-ECD. *J Nucl Med* 1997; **38**(4):587–92.
- 18 Lewis SW, Ford RA, Syed GM, Reveley AM, Toone BU. A controlled study of Tc-99m-HMPAO single-photon emission imaging in chronic schizophrenia. *Psychol Med* 1992; **22**(1):27–35.
- 19 Li X, Tang J, Wu Z, Zhao G, Liu C, George MS. SPECT study of Chinese schizophrenic patients suggests that cerebral hypoperfusion and laterality exist in different ethnic groups. *World J Biol Psychiatry*. 2005; **6**(2):98–106.
- 20 Liddle PF, Friston KJ, Frith CD, Hirsch SR, Jones T, Frackowiak RS. Patterns of cerebral blood flow in schizophrenia. *Br J Psychiatry* 1992; **160**:179–86.
- 21 Miller DD, Andreasen NC, O'Leary DS, Watkins GL, Boles Ponto, Hichwa RD, et al. Comparison of the effects of risperidone and haloperidol on regional cerebral blood flow in schizophrenia. *Biol Psychiatry* 2001; **49**(8):704–15.
- 22 National Institute of Mental Health. CGI: Clinical Global Impression. In: Guy W, Bonato RR, eds. *Manual for the ECDEU Assessment Battery*. 2. Rev ed. Chevy Chase, Md: National Institute of Mental Health, 1970:12–1 – 12–6.
- 23 Paulman RG, Devous MD, Gregory RR, Herman JH, Jennings L, Bonte FJ, et al. Hypofrontality and cognitive impairment in schizophrenia: dynamic single-photon tomography and neuropsychological assessment of schizophrenic brain function. *Biol Psychiatry* 1990; **27**:377–99.
- 24 Pearlson GD, Marsh L. Magnetic resonance imaging in psychiatry. In: Oldham JM, Riba MB, Tasman A, eds. *American Psychiatric Press Review of Psychiatry*. Washington, DC: American Psychiatric Press, volume 12, 1993: 347–81.
- 25 Potkin SG, Alva G, Fleming K, Anand R, Keator d, Carreon D, et al. A PET study of the pathophysiology of negative symptoms in schizophrenia. *Am J Psychiatry* 2002; **159**(2):227–37.
- 26 Rubin P, Holm S, Friberg L, Videbech P, Andersen HS, Bendtsen BB, et al. Altered modulation of prefrontal and subcortical brain activity in newly diagnosed schizophrenia and schizophreniform disorder. A regional cerebral blood flow study. *Arch Gen Psychiatry* 1991; **48**(11):987–95.
- 27 Rubin P, Holm S, Madsen PL, Friberg L, Videbech P, Andersen HS, et al. Regional cerebral blood flow distribution in newly diagnosed schizophrenia and schizophreniform disorder. *Psychiatry Res* 1994; **53**(1):57–75.
- 28 Russell JM, Early TS, Patterson JC, Martin JL, Villanueva-Meyer J, McGee MD, et al. Temporal lobe perfusion asymmetries in schizophrenia. *J Nucl Med* 1997; **38**(4):607–12.
- 29 Sabri O, Erkwoh R, Schreckenberger M, Cremerius U, Schulz G, Dickmann C, et al. Regional cerebral blood flow and negative/positive symptoms in 24 drug-naive, schizophrenic patients during the acute phase and after treatment. *J Nucl Med* 1997; **38**(2):181–88.
- 30 Scottish Schizophrenia Research Group. Regional cerebral blood flow in first-episode schizophrenia patients before and after antipsychotic drug treatment. *Acta Psychiatr Scand* 1998; **97**:440–9.
- 31 Shenton ME, Dickey CC, Frumin M, McCarley RW. A review of MRI findings in schizophrenia. *Schizophr Res* 2001; **49**:1–52.
- 32 Sheppard G, Gruzeliier J, Manchanda R, Hirsch CR, Wise R, Frackowiak R, et al. <sup>15</sup>O positron emission tomographic scanning in predominantly never-treated acute schizophrenic patients. *Lancet* 1983; **31**(8365–66):1448–52.
- 33 Szechtman H, Nahmias C, Garnett S, Firnau G, Brown GM, Kaplan RD, Cleghorn JM. Effect of neuroleptics on altered cerebral glucose metabolism in schizophrenia. *Arch Gen Psychiatry* 1988; **45**:523–32.
- 34 Volkow ND, Brodie JD, Wolf AP, Angrist B, Russel J, Cancro R. Brain metabolism in patients with schizophrenia before and after acute neuroleptic administration. *J Neurol Neurosurg Psychiatry* 1986; **49**:1199–202.
- 35 Wolkin A, Jaeger J, Brodie JD, Wolf AP, Fowler J, Rotrosen J, et al. Persistence of cerebral metabolic abnormalities in chronic schizophrenia as determined by positron emission tomography. *Am J Psychiatry* 1985; **142**(5):564–71.
- 36 World Health Organization. *The ICD-10 Classification of Mental and Behavioral Disorders: Diagnostic Criteria for Research*. World Health Organization 1993, Geneva.
- 37 Yildiz A, Eryilmaz M, Gungor F, Erkilic M, Karayalcin B. Regional cerebral blood flow in schizophrenia before and after neuroleptic medication. *Nucl Med Commun* 2000; **12**:1113–8.