

Treatment of autoimmune ovarian damage in adolescent girls

H. Mlčochová¹, J. Hořejší¹, J. Martínek², R. Vetešnicková-Koubová¹ & M. Halaška¹

¹ Department of Pediatric and Adolescent Gynaecology, 2nd Medical Faculty,

² Institute of Histology and Embryology, 1st Medical Faculty
Charles University Prague, CZECH REPUBLIC

Correspondence to: Hana Mlčochová, M.D.
Department of Pediatric and Adolescent Gynaecology, 2nd Medical Faculty,
Charles University Prague and Teaching Hospital Motol in Prague
VÚvalu 84, 156 09 Prague, CZECH REPUBLIC
PHONE: +420 224438200
FAX: +420 224438220
EMAIL: hana.mlcochova@seznam.cz

Submitted: July 29, 2004

Accepted: September 3, 2004

Key words: Autoimmune ovarian damage; antiovarian autoantibodies; adolescent; menstrual cycle disorders; hormonal replacement therapy

Neuroendocrinol Lett 2005; 26(2):131-135 PMID: 15855884 NEL260205A05 © Neuroendocrinology Letters www.nel.edu

Abstract

INTRODUCTION: To investigate levels of antiovarian autoantibodies in girls and young women with disturbances of menstrual cycle before and during treatment with hormonal therapy. To explain morphological changes in ovarian structure in these patients.

MATERIAL AND METHODS: Studied group included 39 patients. 18 patients were treated for primary amenorrhoea, 21 for menstrual cycle disorders. Patients included in the study were repeatedly examined at the beginning of the study and after six months during which they were treated by estrogen and gestagen. In all patients we have tested FSH, LH and FSH/LH ratio, presence of antiovarian antibodies. Results were compared with those obtained in control women. 21 antiovarian antibodies positive patients were indicated for laparoscopic biopsy. Biopsic sample was examined using light and electron microscopy.

RESULTS: Our treatment with hormonal therapy lead to the reduction of ovarian antigens. In 85% of the cases marked decrease of antiovarian autoantibodies levels was observed, while in 28% of the cases the levels were undetectable. From morphological changes of the biopsic sample enhanced atresia of follicles at different developmental stages was frequently observed. It evoked marked reduction of follicular apparatus up to its complete disappearing.

CONCLUSION: The results of our study and mapping of the antiovarian antibodies positivity support our hypothesis that the antiovarian antibodies positivity corresponds with the clinical symptoms. Appropriate treatment with hormonal replacement therapy minimizes ovarian destruction, preserves ovarian hormonal functions and saves healthy ovarian tissue necessary for future fertility.

Study supported by grant Czech Ministry of Health No NH/7663-3.

Abbreviations and symbols:

POF	premature ovarian failure
FSH	follicle stimulating hormone
LH	luteinizing hormone
EM	electromicroscope
AOA	antiovarian autoantibodies
ELISA	enzyme linked immunosorbent assay
HLA	human leukocyte antigens
CD 4+ and CD8+	T cells
21-OH	21-hydroxylase
17-alpha-OH	17-alpha-hydroxylase
cytochrome P450	side-chain cleavage enzyme
OSA	oligomenorrhea/secondary amenorrhea patients
PA	primary amenorrhea patients
OO	ooplasm
ZP	zona pellucida
MG	membrana granulosa
TI	theca interna cells
LC	luteal cells
Mg	milligram

Introduction

Menopause usually occurs approximately at the age of 50. Premature ovarian failure (POF) is a disorder defined as a pathologic termination of menstrual cycle after puberty and before the age of 40 [1]. Frequency of this disorder is approximately 1%. Hormonal levels show hypergonadotrophic hypoestrism (FSH more than 40 IU/l). The onset of the disease may be very slow. Menarche and regular menstrual cycles may be followed by menstrual cycle disorders – oligomenorrhoea or secondary amenorrhoea. Sterility or infertility at the reproductive age could be manifestations of the early stage of the disease. One of the possible causes of premature ovarian failure could be an autoimmune process beginning at any time during the reproductive period.

Autoimmune damage of the ovarian hormonal production places this disease between the autoimmune endocrinopathies, characterized by direct destruction of the target cells, such as thyroiditis, insulin dependent diabetes and Addison's disease. Animal models proved that the manifestation of the disease is preceded by complex process that is influenced by genetic, immunologic and environmental factors.

The first stage of the disease is triggered by local tissular changes, caused by external antigens (viruses, bacteria) or by the change of intrinsic antigens caused by toxins or drugs. Another possible cause may be the increased metabolism of the ovarian tissue or cumulation of several causes [10].

Autoimmune diseases affect primarily genetically predetermined individuals (with specific HLA class II. alleles). Manifestation of the disease is influenced by external factors like stress, diet, infection etc. Individuals prone to develop an autoimmune disease usually show simultaneous presence of the primary disease with other autoimmune processes. The presence of other autoantibodies both organ specific (against adrenal gland, thyroid gland, isles of Langerhans) and non-specific (against phospholipids, nuclei or smooth muscle) could be also demonstrated. Association of several endocrinopathies is frequently observed. We differen-

tiate two main types: polyglandular syndrome I. and II. POF is associated with polyglandular syndrome I in 12–17%, and with polyglandular syndrome II in 3,5–3,6% of the cases [2]. It has been proved [3] that in the case of POF are thyroideopathies (Hashimoto's thyroiditis in 15–37%, Graves-Basedow's disease in 7–18%) the most frequent co morbidities [8]. On the other hand 30% of the patients with manifest autoimmune thyroiditis are later diagnosed with ovarian dysfunction.

Addison's disease and POF have common target antigen – cells producing steroids. Some patients diagnosed with autoimmune ovarian dysfunction also develop manifest autoimmune adrenal gland dysfunction. Those patients produce antibodies against cells producing steroids. Indirect immunofluorescence, ELISA and Western blott methods proved that those antibodies are produced against 21-hydroxylase (21-OH), 17-alpha hydroxylase (17-alpha-OH) a cytochrome P450 (side-chain cleavage enzyme) [4].

Positivity of the antibodies against cells producing steroids in the early phase of the disease is associated, in experimental model, with the autoimmune oophoritis. Macroscopic cysts are present in 50% of the cases. The cysts are probably caused by the effect of increased gonadotrophin levels. Microscopic evaluation proved mononuclear infiltration in close proximity to follicles. This infiltration was associated mainly with larger follicles. Infiltrating cells were identified as T and B lymphocytes and plasma cells. It is then a very complex process influenced not only by autoantibodies but also by immunoreactive cells and many cytokines [5].

The objective of our study was to determine the occurrence of the organ specific antibodies against ovarian tissue in patients with dysfunctions of the menstrual cycle in comparison to the population of healthy females. Antibodies against germ cells and steroid producing cells were investigated. Some of the antiovarian antibodies positive patients were indicated for laparoscopic biopsy of the ovarian tissue because of heavy menstrual cycle disturbances [6]. Immunohistochemical examination of the sample documented the morphological changes. Control examination of the antiovarian antibodies levels was performed six months after the beginning of the treatment. The results of this study stress the importance of early detection of antiovarian antibodies. If followed by early treatment, it can postpone the premature ovarian failure. Treatment with hormonal replacement therapy confine development of follicles in ovarium and this process decreases the number of target antigens and is reflected in the decline of antiovarian antibodies levels.

Patients and methods

Patients included in the study were examined and followed up in outpatient clinic of the Department of Pediatric and Adolescent Gynaecology 2nd Medical Faculty Charles University and Teaching Hospital Motol in Prague. The group consists of 39 patients, aged 17 to 32 years (21.87±4.27). The examined group was

subdivided into two subgroups: 18 patients with primary amenorrhoea (PA) and 21 with menstrual cycle disorders ranging from oligomenorrhoea to secondary amenorrhoea (OSA). Patients were followed up and examined repeatedly at the beginning of the study and after six months. All patients were screened for: gonadotropin levels (FSH, LH, FSH/LH ratio) and the presence of antiovarian antibodies (against ooplasm -OO, zona pellucida - ZP, membrana granulosa cells - MG, theca folliculi interna cells - TI and luteal cells - LC). 21 antiovarian antibodies positive patients were indicated for laparoscopic biopsy. Bioptic samples were examined using light and electron microscopy.

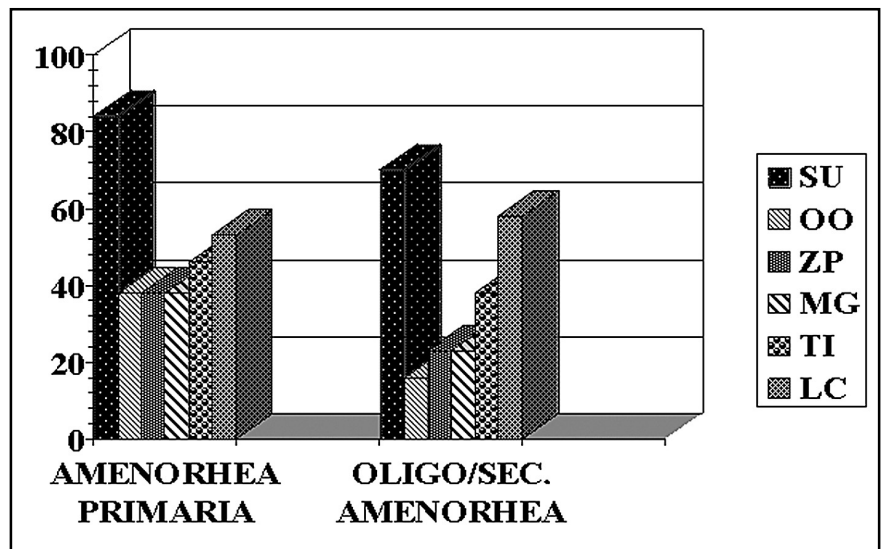
After determination of the levels of gonadotropins and prevalence of antiovarian autoantibodies, the majority of the patients were cured with estradiolum hemihydrate (Estrofem 1-2 mg) every other day followed in the second cycle phase by medroxyprogesteronum acetate (Provera 10 mg) every other day.

In the control group, we used blood samples of 41 healthy women (aged 32±6.7), who were blood donors and had no gynaecological problems.

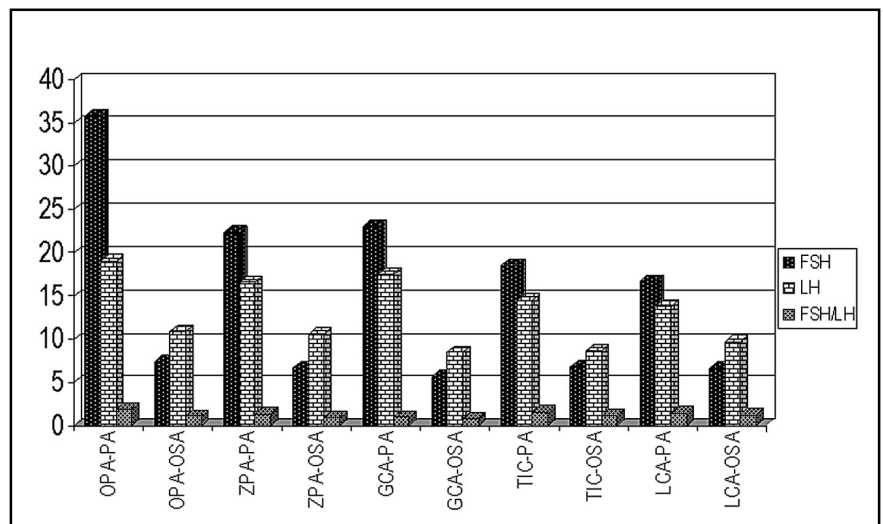
Prevalence of antiovarian antibodies was studied using indirect immunofluorescence. Ovaries of sexually mature rats were used as target organs. The ELISA method was used for determination of antibodies of ooplasm, zona pellucida, membrana granulosa cells, theca folliculi interna cells and luteal cells.

Bioptic samples were processed by standard methods. After morphological microscopic examination at the electron microscope level, the sample was incubated with monoclonal antibodies tinted mostly by fluoroscianate. Samples were then examined in the immunofluorescent microscope.

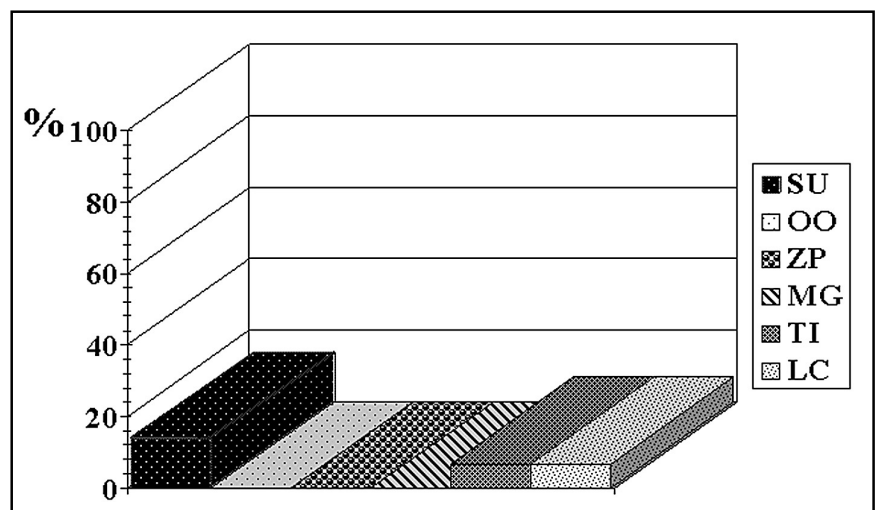
Measurements of plasma luteinizing hormone and plasma follicle-



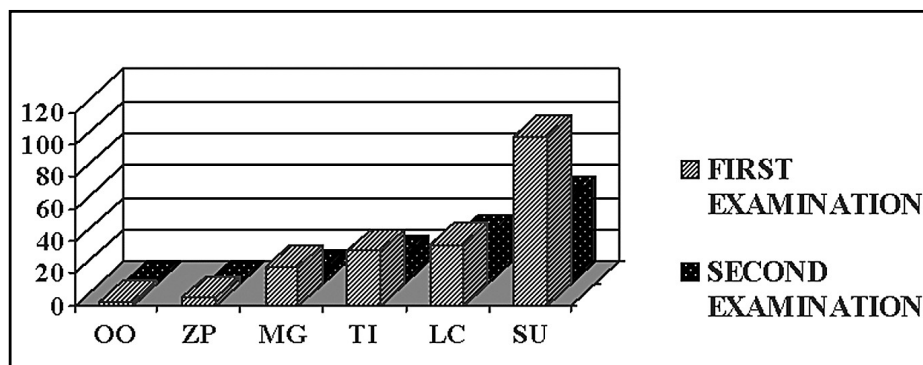
Graph 1. PREVALENCE OF AOA IN PA AND OSA PATIENTS. OO ooplasm, ZP zona pellucida, MG membrana granulosa, TI theca interna, LB luteal cells



Graph 2. HORMONAL LEVELS OF FSH, LH AND FSH/LH RATIO IN PA AND OSA PATIENTS



Graph 3. PREVALENCE OF AOA IN CONTROL GROUP OO ooplasm, ZP zona pellucida, MG membrana granulosa, TI theca interna, LB luteal cells



Graph 4. COMPARISON OF PREVALENCE OF AOA IN FIRST AND SECOND EXAMINATION (results of Mecnamar's test)
OO ooplasm, ZP zona pellucida, MG membrana granulosa, TI theca interna, LC luteal cells

stimulating hormone levels were examined by standard commercial immunoassays.

All patients or their parents signed an informed consent.

Statistical evaluation, Mecnamar's test was performed (results in graph 3).

Results

Positivity of germ-line cells' antibodies and steroids producing cells' antibodies was determined (graph1) as well as levels of gonadotropins and FSH/LH ratio (graph 2) in both subgroups. In patients with primary amenorrhea the prevalence of antiovarian autoantibodies versus germ-line cells was higher. The patients with menstrual cycle dysfunction had the highest prevalence of antiovarian autoantibodies against steroid-producing cells. In all patients antibodies against luteal cells have the highest prevalence, antibodies against theca folliculi interna cells were less frequent and antibodies against membrana granulosa cells were present only in 35% of the cases. Levels of antibodies were examined after a period of six months. After the determination of the levels of gonadotropins and ovarian hormones, the majority of patients were cured with hormonal replacement therapy in substitution of ovarian function. Then autoimmune response of patients to the ovarian antigen determinants could be evaluated. Nearly complete success of this therapy was reflected in the profile of antiovarian antibodies levels. In 85% of the cases marked decrease was observed, while in 28% of the cases the levels were completely undetectable. Results are summarized in graph 3.

As control group we examined also the incidence of antiovarian antibodies in 41 healthy females. Nine of them had positive antiovarian antibody screens. This surprising finding lead us to closer analysis of the group. Retrospective study of the anamnestic data revealed that one woman had missed abortion in the first trimester and had problems with fertility (positive antibodies against all ovarian structures). 6 women confirmed menstrual cycle disorders (4x irregular cycle, 1x oligomenorrhoea). That was why another

group of 15 healthy young women treated in the out-patient unit of Department of Pediatric and Adolescent gynaecology for problems other than menstrual cycle disorders, were examined for prevalence of antiovarian autoantibodies. In this group only one girl was found to be antiovarian autoantibodies positive, but the reason for this positivity was unidentified (Graph 4).

In bioptic samples of ovarium atresia of follicules at different developmental stages was observed frequently. In the atretic follicles delayed formation of zona pellucida was visible. This finding was supported by positive screening for antizonal antibodies in the sera of the patients. These results corresponded with the morphology of follicular atresia in early stages of differentiation.

Conclusion

Autoimmune processes could be one of the causes of premature ovarian failure. The onset of symptoms is very slow. Menarche and regular cycles change gradually into irregular cycles, oligomenorrhoea and finally into secondary amenorrhoea. This disorder is very serious and can start at any time during the reproductive period and can be the cause of infertility in the affected female.

In our study we explored the incidence of antiovarian antibodies in our patients with menstrual cycle disorders, which was mostly very high when compared with results from the control group of healthy women. When a bioptic sample was taken, we studied the advancement of the autoimmune damage in the ovaries.

The majority of outpatients were, after determination of gonadotrophin (FSH, LH) levels and levels of antiovarian autoantibodies, treated with hormonal replacement therapy. This therapy substituted ovarian function, started artificial cyclic changes of endometrium, characteristic for the postmenarcheal period and enabled us to evaluate the autoimmune response of patients to ovarian antigen determinants. Nearly complete success of this therapeutic scheme was reflected in the levels of antibodies. In 28% of the cases the anti-

bodies after six-months' treatment were undetectable. It seems that the treatment with hormonal replacement therapy, confined to the development of follicles in ovarium, decreases the number of target antigens and this is reflected in the decline of antiovarian antibody levels.

Discussion

We would like to emphasize the fact that antiovarian antibodies may be present even in the healthy population. Retrospective analysis of anamnestic data reveals that the control group women, from whom blood samples were obtained, were not currently treated for gynaecological disorders but they had previous gynaecological problems. This forced us to form a new control group consisting of 15 girls with routine laboratory examinations. In this group we found only one antiovarian antibody positive result, but the reason for this was unidentified. This might explain the data presented in literature where the incidence of antiovarian autoantibodies in the healthy population is about 4,8%.

Evaluation of serum antiovarian antibodies, levels of hypophyseal hormones and bioptic findings enables us to determine, with reasonable accuracy, the actual state of neurohumoral regulation, immune reactions of patients and also estimate the damage to gonads. Significantly higher plasma level of FSH in PA and OSA might be caused by not responding to ovarian follicles; levels of LH were not significantly different. In all bioptic samples of ovarium the stimulation of atretic processes was apparent, leading, in extreme cases, to total deficiency of development of the follicles. Those processes, ending in total vanishing of the ovarian germ line cells, are associated with fibrotisation of the ovarian stroma. Breaking of the phagocytic ovarian barrier explains the possibility of creation of new antigen determinants for immune response and consequently the presence of serum antiovarian antibodies.

The animal models of autoimmune endocrinopathies indicate that the pathogenesis of the autoimmune failure of an endocrine gland is a multistep process, requiring several genetic and environmental abnormalities to come together before full-blown autoimmune endocrinopathy develops [9]. The following phases in the disease process can be discerned. An initial phase of early accumulation of antigen-presenting cells and accessory cells (e.g. subclasses of macrophages) in the endocrine tissue, a later phase of an apparently uncontrolled production of autoreactive T cells and of autoantibodies of the IgG class in the draining lymph nodes and followed by last phase where the target endocrine tissue becomes susceptible for the autoimmune attack by the generated autoreactive T cells and autoantibodies; this finally results in the destruction of the glandular tissue. Patients in this last phase of POF need currently, in vitro fertilization or embryo transfer with donated oocyte which are the best therapeutic options to achieve pregnancy although ovulation induction and immunosuppressive treatment might be used in approved experimental protocols [7]. But for patients

in early phase of autoimmune endocrinopathy, mainly developed in adolescent girls, enzyme linked immunosorbent assay which might be useful in screening symptomatic patients helps us to identify those for whom appropriate treatment may improve future fertility.

Summary

Premature ovarian failure is a very serious disease that can handicap the patient. Results of our study and mapping of antiovarian antibodies in our patients support our conviction that presence of antiovarian antibodies corresponds, sooner or later, with the clinical symptoms. POF can start in such patients at any time of the reproductive period. Appropriate treatment with hormonal replacement therapy as substitution of ovarian function, minimizes ovarian destruction, preserves ovarian hormonal functions and saves healthy ovarian tissue necessary for future fertility of the patient. Our study proves the importance of early diagnosis and treatment of autoimmune ovarian damage that saves patient's fertility.

Study supported by grant Czech Ministry of Health No NH/7663-3.

REFERENCES

- 1 De Moraes-Ruehsen M, Jones GS. Premature ovarian failure. *Fertil Steril* 1967; **18**:440-461.
- 2 Coulam CB, Tung KSK: Autoimmune basis of premature ovarian failure. *Immunol. Alerg Clin North Amer* 1994, p. 739-752.
- 3 Trencle D, Morley JE, Handwerker BS: Polyglandular autoimmune syndromes. *Am J Med* 1984, p. 107-116.
- 4 Chen S, Sawicka J, Bettlerle C, Powell M, Prentice L, et al. Autoantibodies to steroidogenic enzymes in autoimmune polyglandular syndrome, Addison's disease, and premature ovarian failure. *J Clin Endocrinol Metab* 1996, p. 1871-1876.
- 5 Chiauzzi VA, Bussmann L, Calvo JC, Sunblad V, Charreau EK. Circulating immunoglobulins that inhibit the binding of follicle-stimulating hormone to its receptor: a putative diagnostic role in resistant ovary syndrome? *Clin Endocrinol* 2004; p. 46-54.
- 6 Jorgez CJ, Klysiak M, Jamin SP, Behringer RR, Matzuk MM. Granulosa cell-specific inactivation of follistatin causes female fertility defects: *Mol Endocrinol* 2004; **18** (4): 953-67
- 7 LeThiHuong D, Gmpel A, Wechsel B, Pietr JC. Spontaneous pregnancy in a woman with lupus and thyroiditis despite intermittent premature ovarian failure: *Am Rheum Dic* 2004; p. 108-9.
- 8 Kauffman RP, Castracane VD. Premature ovarian failure associated with autoimmune polyglandular syndrome: pathophysiological mechanism and future fertility. *J Womens Health (Lachmt)* 2003; p. 513-20.
- 9 Conway GS, Kalfas G, Patel A, Davres MC, Jacobs HS. Characterisation of idiopathic premature ovarian failure: *Fertil Steril* 1996; p. 337-41.
- 10 Yang G, Schoenfeld D, Penneyl C, Hurtal K, et al. Identification of premature ovarian failure patients with underlying autoimmunity: *J Womens Health Gen Based Med* 2000; p. 275-87.