

# Familial occurrence of myoclonic epilepsy syndrome and acute intermittent porphyria

Pavel Varsik<sup>1</sup>, Darina Buranová<sup>1</sup>, Branislav Kollár<sup>1</sup>, Pavel Traubner<sup>1</sup>, Peter Božek<sup>2</sup> & Miroslav Mikulecký<sup>3</sup>

<sup>1</sup> 1st Department of Neurology Medical School, Comenius University, Bratislava,

<sup>2</sup> Department of Clinical Biochemistry and Haematology, Hospital of Ministry of Interior, Bratislava,

<sup>3</sup> 1st Department of Internal Medicine Medical School, Comenius University, Bratislava,  
SLOVAK REPUBLIC

*Correspondence to:* Professor Pavel Varsik, MD, DrSc.  
1st Dept of Neurology, Medical School, Comenius University,  
Mickiewiczova 13, SK-81369 Bratislava, SLOVAK REPUBLIC  
PHONE: +421-02-57290294  
FAX: +421-02-57290300  
EMAIL: [neurologia@faneba.sk](mailto:neurologia@faneba.sk)

*Submitted:* December 24, 2004

*Accepted:* January 7, 2005

**Key words:** myoclonic epilepsy syndrome; progressive myoclonic epilepsy;  
"Baltic myoclonus"; antiepileptic drugs; acute intermittent porphyria

*Neuroendocrinol Lett 2005; 26(1):7-12 NEL260105A01 Copyright © Neuroendocrinology Letters [www.nel.edu](http://www.nel.edu)*

## Abstract

**OBJECTIVES:** Myoclonic epilepsy (ME) syndrome is not rare in north-eastern Europe; it is also seen in various forms. Familial occurrence of ME syndrome and acute intermittent porphyria (AIP) was observed in three siblings. The following report was aimed the differentiation between co-morbidity of two different disorders or presence the epileptic seizures within the clinical picture of latent AIP.

**MATERIAL AND METHODS:** A case report of three siblings who suffered from seizures, myoclonias, ataxia and minor psychological changes since the age of 8 and 9 years is described in the following report.

**RESULTS:** The clinical picture most resembled that of "Baltic myoclonus" (dentate-rubral degeneration or dyssynergia cerebellaris myoclonica – Ramsay-Hunt syndrome) with epilepsy and/or a benign form of progressive myoclonic epilepsy (PME). The possibility of juvenile myoclonic epilepsy (JME) and other aetiological factors, as less probable causes of ME syndrome, were considered. After 15 years of the treatment by anti-epileptic drugs in all three siblings, AIP was discovered.

**CONCLUSION:** Our interest lies in the differentiation of co-morbidity of two different disorders or presence of epileptic seizures as the clinical picture of latent AIP. We propose that the AIP attacks were caused by long-term administration of anti-epileptic drugs. At the same time we suggest it is a coincidence that the two independent genetic abnormalities coexist in the subjects (benign form of degenerative cerebral disease and AIP).

## Introduction:

Myoclonic epilepsy (ME) syndrome is a well known subtype of generalized epilepsy. It has various forms, and genetic factors play an important role in many of them. In the region of northeastern Europe the most frequent form is known also as "Baltic myoclonus" (Scandinavian – Finnish form of progressive ME) (PME). Some linkage studies identified a marker for juvenile ME (JME) on the short arm of chromosome 6 likewise in one form of PME (Lafora disease), while in another form of PME (Unverricht –Lundborg disease and "Baltic myoclonus") the genetic disturbance in chromosome 21 was confirmed. In both types the genetic transmission is characterised by autosomal recessive inheritance, with high local prevalence in Finland (1 case out of every 20.000 births) [21]. The clinical picture of the fully developed syndrome comprises of asymmetric, arrhythmic myoclonias, sporadic generalized epileptic seizures (absence or tonic-clonic seizure), mild or moderate mental deterioration, clinical neurological symptomatology (cerebellar or pyramidal) and positive familial history. EEG shows generalized spikes-waves (SW) or polyspikes-waves (PSW) activity and bursts with abnormal background activity in PME (Unverricht-Lundborg and Lafora diseases) and typically a normal background activity with 4 to 6 Hz S-W or PS-W ("polyspike") discharges in "Baltic myoclonus" and JME. Usually both types of disease are photosensitive to intermittent light stimulation and eye closure.

The relationship of acute intermittent porphyria (AIP) to genetic factors is a well-known phenomenon. The genetic defect of porphobilinogen deaminase is located on the distal band of chromosome 11q23–11q24 [7]. In the Slovak Republic we have no reliable register of AIP, but according to the data of Swedish and Finnish National register for porphyrias, the prevalence of AIP is 4–5 cases per 100.000 births. The clinical picture of this disease is quite variable and epileptic syndromes are one of the manifestations of the disease [5,13, 17, 20].

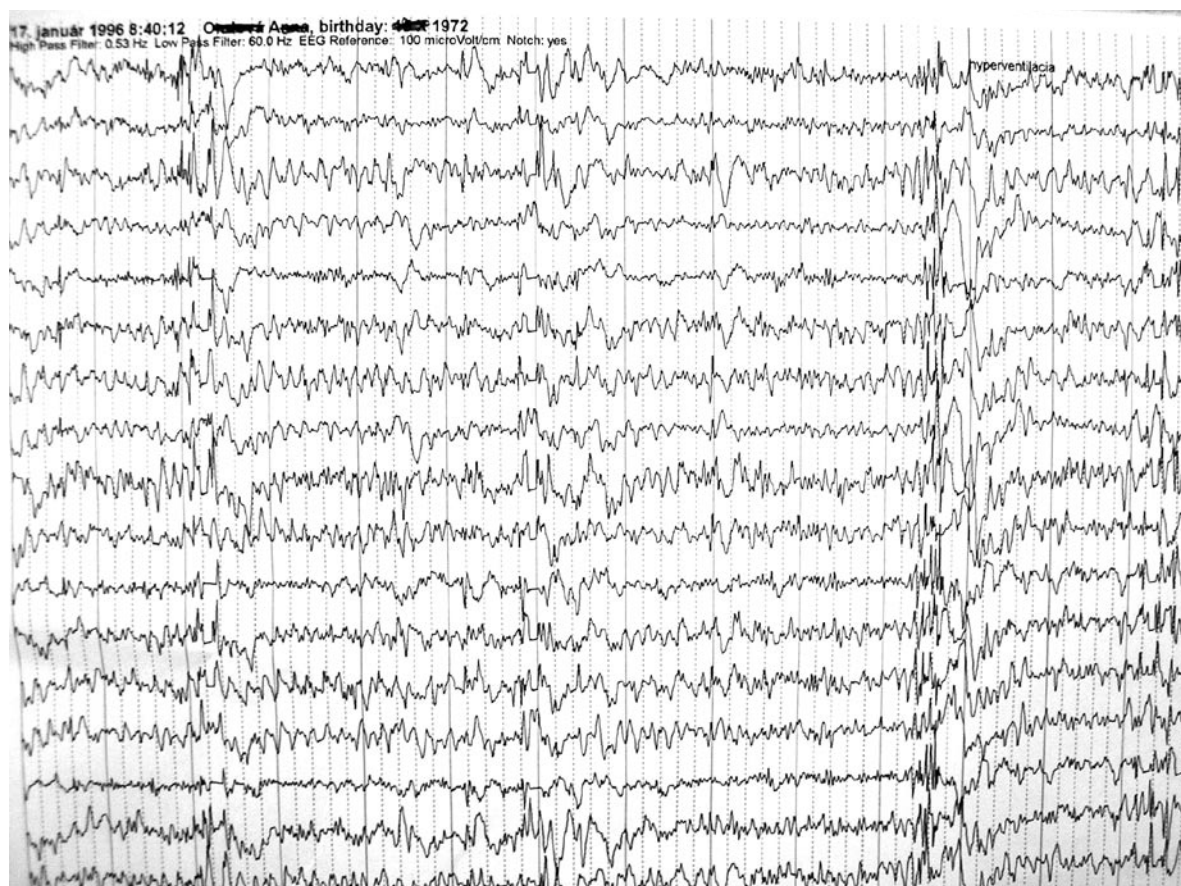The coincidence of both disorders is rare and thus could become a reason for further research.

The aim of this study is to address the following questions:

- 1) is the co-occurrence of two clinical units the accidental coincidence of two independent diseases?
- 2) do these two disorders share a common genetic background?
- 3) is ME syndrome the manifestation of porphyric damage of the brain?

## Material and Methods:

The patient is a 33-year-old woman (A.O.) from eastern Slovakia, who presented 9 years ago, after parturition, and was admitted to our department. She presented with manifestations of familial myoclonic epilepsy (which occurred at the age of eight years) and her two siblings – sister and brother – also suffered from



**Fig. 1:** Electroencephalographic record of the patient A. O. during the admission to hospital showed the bursts of complex activity with 4 to 6 Hz sharp waves and normal background activity.

the same disorder. The cause of her admission to hospital was the rapid deterioration of the disease (*frequency, severity of the attacks of myoclonias, and seizures*). On examination after admission, generalized asynchronous and arrhythmic myoclonias were observed. The intensity of myoclonias varied during the course of the disease and they culminated at certain occasions. Cerebellar symptomatology (ataxia) was present, and according to patient history, she also suffered from tonic and clonic seizures. Neither intellectual deterioration nor marked psychic disorders were detected. A worsening of clinical condition occurred after parturition; both myoclonias and absence and generalized tonic-clonic seizures had become more frequent. Electroencephalographic records showed bursts of complex polyrhythmic activity with 4 to 6 Hz sharp waves with normal background activity and negative photostimulation (Fig.1). The cerebrospinal fluid, CT-scan and MRI images of the brain showed no pathological results. The biopsy (skin, muscles) showed no abnormalities (including Lafora bodies and RRF).

Catamnestic examination showed that the patient suffered an episode of abdominal crisis in the past. The high level of urobilinogen in the urine led us to include the examination of porphyrine metabolism. The presence of aminolevulinic acid and porphobilinogen in urine and high levels of uro- and coproporphyrine were detected (classic gas chromatographic method), which

supported the diagnosis of acute intermittent porphyria (Fig. 2, Tab.1).

When the diagnosis of AIP was confirmed, intermittent treatment with heme (Normosang) and the change of anti-epileptic treatment (clonazepam instead of hydantoin and valproic acid) had beneficial effects and the condition of the patient, after 25 years duration of the disease, was gradually improved [21, 17, 22].

The 26-year-old sister (M.K.) and 27-year-old brother (J.K.) of our patient have suffered from several generalized asynchronous, arrhythmic and asymmetric myoclonias, and sporadic generalized tonic and clonic seizures, since the age of 8 and 9 respectively, which proved the presence of ME syndrome. They were also emotionally unstable without the symptoms of more important psychic changes (IQ, performance) and also suffered from abdominal crisis' in the past (adnexitis and appendicitis, respectively). EEG showed polyrhythmic "polyspike" 4 to 6 Hz activity with complex paroxysmal manifestations. The CSF, MRI and CT examination showed no abnormalities. Aminolevulinic acid, porphobilinogen and higher levels of uroporphyrine and coproporphyrine were found, and the diagnosis of AIP in both siblings was confirmed (Fig.2, Tab.1).

The mother of these three siblings had asymptomatic AIP with abnormal values of porphyrins in the urine. The father was healthy. Four children of these siblings, now aged 10–12 years, have not shown any signs

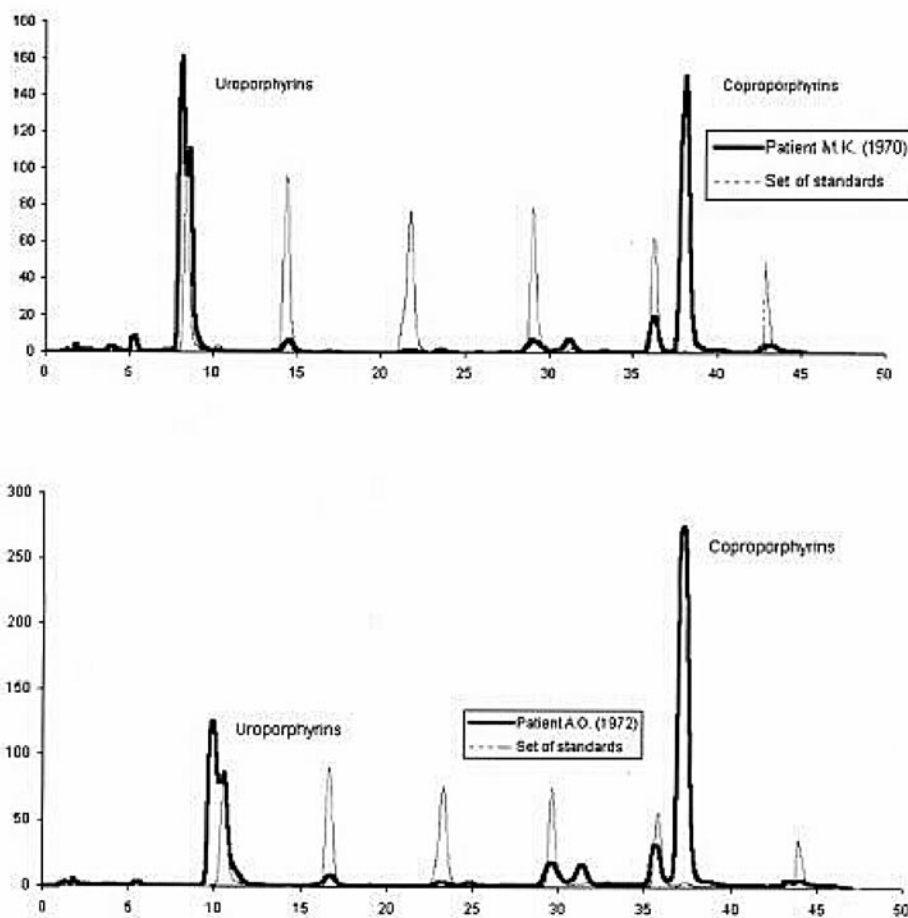


Fig. 2 : Amino-levulinic acid, porphobilinogen and higher levels of uroporphyrine and coproporphyrine in establishing AIP diagnosis in both siblings.

**Table 1:** The values of porphyrins in urine in three siblings (A.O., M.K., J.K.) with acute intermittent porphyria in remission.

Sample Control	uroporphyrin mol/l up to 50	coproporphyrin nmol/l up to 250	PBG umol/l up to 8.8	DALA umol/l up to 12.0
A.O., 1972	4925	1231	994.6	246.7
	128	512	18.7	29.6
M.K., 1970	1056	704	299.8	41.0
J.K., 1969	54	84	12.8	27.4

Legend : PBG – porphobilinogen, DALA – delta-amino levulic acid.  
Note :first sample of patient A.O. was taken during the attack of AIP

**Table 2.** The collection of published cases.

AUTHOR (reference)	GENDER	AGE		EPILEPSY	Type	Etiology	AIP				clinical picture
		years	age at diagnosis				age at diagnosis	provoking factor	acute attack	causal relationship	
Gretter et al. 1963 [10]	F	33	33	A+PE	AIP	33	AEM	+	+	P+PO+E	
Davidson et al. 1963 [6]	M	52	19	A,TCS	?	52	AEM(PB,PHT)	+	?	E,AC	
Nielsen,Thorn et al. 1965 [20]	F	32	32	TCS	AIP	32	AEM(PHT)	+	+	AC,PO+E	
	M	21	21	TCS	AIP	21	AEM	+	+	AC,PO+E	
Birchfield,Cowger et al. 1965 [2]	F	7	3?	PE+G	PCL,chorea	7	AEM	+	-	coma,AC+VC,E	
Magnussen et al. 1975 [18]	M	36	20	TCS	?	36	AEM+OP(PHT+PB)	+	?	AC+P,E	
Larson et al. 1978 [16]	M	35	35	PE	Trauma	35	AEM	+	-	E,AC	
Biagini et al. 1979 [1]	M	14	3	TCS+A+MCS	PCL	14	AEM(PB+PHT+VPA)	+	-	E,AC	
Wirtschafter et al. 1980 [27]	F	16	15	PE+G,status epil.	Trauma	16	AEM	+	-		
Bonkowski et al. 1980 [3]	M	38	38	TCS	AIP	21	AEM(PHT+CBZ)	+	+	E,AC	
Lai et al. 1981 [15]	F	21	21	TCS	AIP	21	AEM(CBZ)	+	+	AC+P+E	
Herrick et al. 1989 [12]	F	40	2	TCS	PCL	40	AEM(VPA+CBZ)	+	-	E,AC	
	M	50	6	TCS	PCL	50	AEM(PHT+VPA+CPZ)	+	-	E,AC	
Sadeh et al. 1991 [21]	F	16	16	PE+G	AIP	16	AEM+infection	+	+	E,AC	
Suzuki et al. 1992 [25]	F	13	6	MCS	heredit.	13	AEM	+	-	E,AC	
Bylesjö et al. 1996 [5]	M	9	1	PE+G	?	1	AEM(PHT+VPA)	+	?	E	
	M	29	3	TCS	PCL?	27	AEM	?	?	E+	
	F	60	58	PE+G	trauma	?	?	?	?	E+	
	F	61	52	PE+G	?	79	AEM(PHT)	?	?	E	
	F	50	41	PE+G	AIP	27	AEM+starvation	+	+	E,AC	
	F	63	24	TCS	AIP	24	AEM+operation	+	+	E,AC,HT	
	F	51	25	TCS	AIP	22	AEM	+	+	E,AC	
	F	48	24	TCS	AIP	24	menstruation	+	+	E,AC,HT	
	F	50	49	TCS	AIP	45	Starv. M,infection	+	+	AC,E	
	F	30	26	TCS	AIP	21	M,infection	+	+	AC,HT,PO,P,E	
Buranová et al. 2001 [4]	F	25	8	MCS	heredit.	24	AEM+operation	+	-	E,AC	
	F	26	9	MCS	heredit.	25	AEM+operation	+	-	E,AC	
	M	28	9	MCS	heredit.	27	AEM	+	-	E,AC	
Sykes et al. 2001 [26]	M	3	1	TCS	PCL	3	AEM(PB)	+	-	E,AC	
Gaida,Hommernick et al. 2001 [9]	M	28	3	PE+G	PCL	28	AEM(OCBZ)	+ PCL	-	AC	

**Legend:** T – trauma, H – hereditary etiology, A – absence, PE+G – parcial epilepsy+generalization, TCS – tonic-clonic seizure, MCS – myoclonic seizure, AEM – antiepileptic medication, A+O – anesthesia and surgery, PCL – perinatal cerebral lesion, M – menstruation, ? – unclear etiology, +E – epil. seizures preceding AIP, -E – epil. seizure after AIP diagnosis, AC+VC – abdominal and vegetative crisis, HT – hypertension, P – paresis, PO – psycho-organic syndrome, E – epileptic seizure, PB – pentobarbital, PHT – phenytoin, VPA – valproic acid, CBZ – carbamazepine

**Table 3.** Differential diagnosis of ME syndrome (according to Donaghy, 2001) [8]

Disease	Genetic Disturbance	Clinical picture				EEG
		MJ	CA	ME	MR	biopsy+abnormalities
PME						abn. background act.
- UL dis.	21.q 22.8	+	+	+	+ -+++	S-W, PS-W, FS +
- Lafora d.	6.q 23-25	+	+	+	+ -+++	bursts 2,5-3 Hz (Biopsy-Lafora bodies)
- Baltic M. (DRD)	21	++	++	+	0 -+	norm. background act. S-W, PS-W, 4-6Hz, FS+
JME	6	+	+	+	0	norm. background act. S-W, PS-W, 4-6 Hz, FS-
DRPLA	12.p 13-31	++	++	+ -	+ -++	various abnorm. EEG
MERRF	mt DNA Mutations	+	+	+	0 -+	various abnorm. EEG + deafness, +myopathy (+Biopsy- RRF )
gangliosidosis						various abnorm. EEG
GM 1	3	+ -	+ -	+	+++	+skeletal abnormalities
GM 2	15.q 23-24				+++	+ red spot
Mukopolysach.		+ -	+ -	+	+++	various EEG abnormalities
Sialidosis						+ facial and skelet. dys.
Ceroid	16.p 12			+	+++	various abnorm. EEG
Lipofuscinosis						+ skeletal abnormalities + red spot

Legend:UV dis.-Unverricht-Lundborg disease,,Baltic myoclonus,, DRD -dentato-rubral degeneration ,DRPLA-dentato-rubro-pallido-lousian atrophy, MERRF-myoclonic epilepsy with muscle,,red ragged fibers"

or symptoms of ME syndrome and/or AIP so far (the values of porphyrins in the urine are in normal range).

### Results:

- 1) The coincidence of ME syndrome and AIP in all three siblings was found. In all cases approximately 15 years of the treatment by anti-epileptic drugs preceded the manifestation of the AIP symptomatology.
- 2) In all three siblings the symptoms of myoclonias, cerebellar ataxy, sporadic generalized tonic-clonic seizures and minimal psychic changes were documented. In EEG records the S-W and PS-W bursts 4 to 6 Hz activity were presented and FS reaction on intermittent light with eye closure was absent. Imaging methods, cerebrospinal fluid examination, and biopsy (skin and muscles) showed normal findings (Lafora bodies and RRF).
- 3) Upon biochemical examination of serum and urine, the AIP and defect of porphobilinogen deaminase was confirmed (defect of locus 11 q 23-24).
- 4) The clinical picture of ME syndrome and a benign form of PME, namely so called "Baltic myoclonus" (or DRD - degenerative disease of dentate-rubral system with the genetic disturbance on chromosome 21) was most probably indicated.

### Discussion:

The clinical picture of all three siblings was similar: the disorder began at 8 or 9 years of age, with myoclonias, cerebellar ataxia, and sporadic tonic and clonic seizures. It was without important psychic changes, had a long 25-year duration, and a benign course. EEG records suggest the presence of a benign form of ME syndrome, probably the "Baltic myoclonus" (or degenerative disease DRD - so called Ramsay-Hunt syndrome and dyssynergia cerebellaris myoclonica with epilepsy). The diagnostic problem has a genetic explanation; a familial incidence of ME syndrome, which lasted for 25-27 years, and clinical symptoms of AIP, which occurred after 15 years anti-epileptic treatment. These facts supported our assumption that ME syndrome was actually the first manifestation of the independent degenerative cerebral disease. It is probable that latent form AIP was present in the siblings their whole life, and a possible pathogenetic way of occurrence and clinical manifestation of the disease was triggered by porphyrinogenic stimuli and substances (drugs) - in this case, namely the long term administration of anti-epileptic therapy.

According to the works of McKussick, epileptic seizures occur in 10-20% of patients with AIP, usually during attacks of porphyric disease. Nevertheless the experience in our country, and the data from the Swedish National Centre for porphyria, showed that the occurrence of epilepsy may be less than 5-10% of AIP

patients (294 patients with porphyria and only 10 cases of epileptic syndrome) [5]. The coincidence of a different type of partial or generalized epilepsy and AIP in many cases is very frequently provoked by anti-epileptic drugs (Tab.2.).

The presence of epilepsy in acute attacks of AIP may be an increasing trend, because abnormal findings in EEG and MRI examinations, which are not present in interictal period of AIP, were documented [10, 14, 19, 23, 25].

These data confirmed that the changes are usually provoked in the ictal phase by delta-aminolevulinic acid (DALA), and due to the toxic influence of free radicals (oxidative stress) at the cellular level. Consequently DALA may be competitively linked to GABA receptors. This may be the cause of neuronal dysfunction, vascular changes and development of neuro-psychiatric clinical symptoms [3, 8, 11, 24].

Detailed chromosomal genetic analysis is presently not available in our country, and thus proof of localization of the chromosomal genetic abnormality responsible for ME syndrome has not been found. Hypothetically, we do not suggest the origin of ME in the two sisters and brother as the result of porphyric changes; because in all three siblings the uniform clinical picture and course of the disease PME confirmed and AIP as the cause may be practically excluded. In despite a heterogeneity of the variants of genetic abnormalities, the defect of the locus in chromosome 11 in AIP, is generally accepted, and in this locus only one neurologic disturbance of typical ataxia (SCA5-so called president Lincoln family ataxy) is described [7, 8, 17, 21]. Thus we suggest that in all three siblings, two genetic locus abnormalities are present, the most probable location is on chromosome 21 for PME and on chromosome 11 for the AIP (Table 3).

We suppose the precipitation of AIP attacks was brought about by the long-term administration of anti-epileptic drugs. At the same time, we suggest that there is a coincidence of two independent genetic abnormalities (a benign form of PME and AIP), while the AIP might not have been manifested clinically in other circumstances (if no antiepileptic drugs were administered).

#### REFERENCES:

- Biagini R, Tigniani R, Fifi AR, Nappini L. Acute intermittent porphyria and epilepsy. *Arch Dis Child* 1979; **54**:644–645.
- Birchfield RI, Cowger ML. Acute intermittent porphyria with seizures. *Am J Dis Child*, 1966; **112**:561–565.
- Bonkowsky HL, Sinclair PR, Emery S, Sinclair JF. Seizure management in acute hepatic porphyria: risk of valproate and clonazepam. *Neurology* 1980; **30**:585–592.
- Buranová D, Varsik P, Baláž M, Božek P. Acute intermittent porphyria and symptoms of the disturbance of the nervous system (in Slovak). *Neurologie pro praxi* 2001; **3**(2):147–152.
- Bylesjö I, Forsgren L, Lithner F, Boman K. Epidemiology and Clinical Characteristics of Seizures in Patients with Acute Intermittent Porphyria. *Epilepsia*. 1996; **37**(3):230–235.
- Davidson R. Acute porphyria and epilepsy:safety of clonazepam. *Epilepsia* 1991; **33**:108–111.
- Desnick RJ, Ostakiewicz L, Tischler P, Mustajoki P. Acute intermittent porphyria: characterization of a novel mutation in the structural gene for porphobilinogen deaminase. Demonstration of non catalytic enzyme intermediates stabilized by bound protein. *Journal of Clinical Investigation* 1985; **76**:865–874.
- Donaghy M (Editor). *Brain's Diseases of the Nervous System*. Eleventh Edition, Oxford Univ Press 2001. p. 1244.
- Gaida –Hommernick B, Rieck K, Runge U. Oxcarbamazepine in focal epilepsy and hepatic porphyria: a case report. *Epilepsia* 2001; **42** (6): 793–795.
- Gretter T, Danner P, Nibbelink D, Green D, Sahs AL. The effect of diphenylhydantoin (Dilantin) on acute intermittent porphyria. *Trans Am Neurol Assoc* 1963; **88**:176–178
- Hahn M, Gildemeister OS, Krauss GL, Pepe JA, Lambrecht RW, Donohue S, Bonkowsky HL. Effects of new anticonvulsant medication on porphyrin synthesis in cultured liver cells:Potential implications for patients with acute porphyria. *Neurology* 1997; **49**: 97–105.
- Herrick AL, McColl KEL, Moore MR, Brodie MJ, Adamson AR, Goldberg A. Acute intermittent porphyria in two patients with anticonvulsant therapy and with normal erythrocyte porphobilinogen deaminase activity. *Br J Clin Pharmacol* 1989; **27**:491–497.
- Kaupinnen R. and Mustajoki P. Prognosis of acute intermittent porphyria: occurrence of acute attacks, precipitating factors and associated diseases. *Medicine* 1992; **71**:1–13.
- Kučera P, Krahulec B, Štrbová L. Skin Sympathetic response in subclinical diabetic neuropathy diagnosis. In Program and abstracts, Fifth Diabetic Neuropathy Satellite San Jose (s.n.), 2000; p 64.
- Lai CW. Carbamazepine in seizure management in acute intermittent porphyria. *Neurology* 1981; **31**:232–233.
- Larson AW, Wasserstrom WR, Felsher BF, Shih JC. Posttraumatic epilepsy and acute intermittent porphyria: effect of phenytoin, carbamazepine and clonazepam. *Neurology* 1978; **28**:824–828.
- Lehesjoki A, Koskineniemi M, Sistonen D, Miao J, Mästäbacka J, Norio R, De la Chapelle A. Localization of a gene for progressive myoclonic epilepsy to chromosome 21q 22 *Proc Nat Acad Sci USA* 1991; **88**:3606–3699.
- Magnussen CR, Doherty JM, Hess RA, Tschudy DP. Grand mal seizures and acute intermittent porphyria. *Neurology* 1975; **25**: 1121–1125.
- Mustajoki P, Desnick RJ. Genetic heterogeneity in acute intermittent porphyria: characterization and frequency of porphobilinogen deaminase mutation in Finland. *Brit Med Journal* 1985; **291**: 505–509.
- Nielsen B, Thorn NA. Transient excess urinary excretion of antidiuretic material in acute intermittent porphyria. With hyponatremia and hypomagnesemia. *Am J Med* 1965; **38**:345–358.
- Sadeh M, Blatt I, Martonovits I, Karmi A, Goldhammer V. Treatment of porphyric convulsions with magnesium sulfate. *Epilepsia* 1991; **32**:712–715.
- Sadeh M, Blatt I, Martonovits I, Karmi A, Goldhammer V. Treatment of porphyric convulsions with magnesium sulfate. *Epilepsia* 1991; **32**: 712–715.
- Stein JA, Tschudy DP. Acute intermittent porphyria. A clinical and biochemical study of 46 patients. *Medicine* 1970; **49**:1–16
- Suarez JI, Cohen ML, Larkin J, Kernich CA, Hricik DE, Daroff RB. Acute intermittent porphyria: clinicopathologic correlation. Report of case and review of the literature. *Neurology* 1997; **48**: 1678–1683.
- Suzuki A, Aso K, Ariyoshi C, Ishimarn M. Acute intermittent porphyria and epilepsy:safety of klonazepam. *Epilepsia* 1991; **33**: 108–111.
- Sykes RM. Acute intermittent porphyria, seizures and antiepileptic drugs: a report on 3-year old Nigerian boy. *Seizure* 2001; **10**(1): 64–66.
- Wirtschafter JD, Turner FW, Dow RS. Convulsive seizures as the presenting manifestation of intermittent porphyria. *Neurology* 1960; **10**:787–792.