

# Evaluation of subretinal fluid absorption by optical coherence tomography in circumscribed choroidal hemangioma after photodynamic therapy with Verteporfin

**Petr Soucek & Iona Cihelková**

The Eye Department, University Hospital of 3<sup>rd</sup> Medical Faculty, Prague, CZECH REPUBLIC

*Correspondence to:* Petr Soucek, M.D.  
The Eye Department  
University Hospital  
Srobarova 50, 100 34 Prague, CZECH REPUBLIC  
CZECH REPUBLIC  
EMAIL: soucek@fnkv.cz

*Submitted:* February 21, 2004

*Accepted:* February 27, 2004

*Key words:* **circumscribed choroidal hemangioma; optical coherence tomography; photodynamic therapy; retinal thickness at fixation point; subretinal fluid absorption; verteporfin**

Neuroendocrinol Lett 2004; 25(1/2):109-114 NEL251204A14 Copyright © Neuroendocrinology Letters www.nel.edu

## **Abstract**

**PURPOSE:** To determine if optical coherence tomography (OCT) measurements of retinal thickness at the fixation point (RTFP) can be used to confirm the effectiveness of photodynamic therapy (PDT) with verteporfin in the treatment of symptomatic circumscribed choroidal hemangioma (CCH).

**METHODS:** Nine eyes of nine patients with subretinal fluid under foveal centre were treated by PDT with a dose of 6 mg/m<sup>2</sup> of intravenous verteporfin administered 5 minutes before a laser irradiation at 689 nm. Visual outcomes, initial, and final findings were evaluated using biomicroscopy, OCT, ultrasound, fluorescein angiography, and indocyanine green angiography.

**RESULTS:** After a mean follow-up of 8 months (range, 3-18 months) OCT showed absorption of subretinal fluid in all cases (100%). Maximal decrease of RTFP was seen within first month after treatment. Average RTFP decreased from 378 µm (range, 221 µm - 849 µm) preoperatively to 190 µm (range, 118 µm - 321 µm) postoperatively (p=0.017, paired t-test). Mean best corrected visual acuity (BCVA) improved from 4/16 (range, 4/5-1/20) preoperatively to 4/8 (range, 4/3-1/15) postoperatively (p=0.0046, paired t-test). An improvement in BCVA was observed in all cases (100%, one to seven lines on Early Treatment Diabetic Retinopathy Study charts). BCVA returned to 4/5 or better in six patients (67%). Mean tumor height decreased from 3.2 mm (range, 1.5 mm - 4.0 mm) preoperatively to 0.9 mm (range, 0 mm - 2.4 mm) postoperatively (p=0.00003, paired t-test). There was no measurable tumor height in four cases (44%), there were marked reduction in the other five cases (56%) on ultrasound.

**CONCLUSIONS:** OCT appears to be useful method for evaluation of subretinal fluid absorption after the treatment of CCH by PDT with verteporfin. RTFP value can be used for quantification of subretinal fluid under the foveal centre. Functional results of PDT with verteporfin in CCH are limited in pre-existing retinal alterations. Randomised trial with single versus repeated sessions of PDT with verteporfin is needed.

## Introduction

### *Optical Coherence Tomography*

Optical coherence tomography (OCT) is modern the most precise method for quantification of a subretinal and intraretinal fluid. It has been widely used to document therapeutical results in the fields of medical and surgical retina and also for evaluation of one case with hemangioma. The latest model of an instrument (Stratus OCT, Zeiss, Germany) is a computer-assisted precision optical instrument that generates cross sectional images (tomograms) of the retina with a minimum of 10  $\mu\text{m}$  axial resolution and transverse resolution of 20 microns. It uses an optical measurement technique known as low-coherence interferometry. The principle of operation of interferometry is analogous to ultrasound, except that it uses light rather than sound. As it is well known, the principal difference is that the speed of light is nearly a million times faster than the speed of sound. This speed difference permits measurement of structures and distances on the 10 microns scale, as compared to the 100 microns scale for ultrasound. Another important difference is that optical interferometry does not require contact with the tissue examined, unlike ultrasound [1].

The Stratus OCT displays the tomograms in real time using a false color scale that represents the degree of light backscattering from tissues at different levels in front of, within and under the retina over 2 mm of depth. The system stores the scans we select for later analysis.

“Radial lines” scan protocol consists of a group of 6 scans arranged in a spoke pattern. The algorithm computes retinal thickness separately for each line scan with default diameter of 6 mm. Analysis protocol “Centre” represents the calculation of average retinal thickness at the fixation point (RTFP, in  $\mu\text{m}$ ), where all six scans intersect [2]. This technique was successfully used for quantification of leakage from choroidal neovascularization (CNV) under foveal centre in patients with predominantly classic subfoveal CNV caused by age-related and myopic macular degeneration treated by photodynamic therapy (PDT) with verteporfin [3].

To our knowledge, this is the first such a study using Stratus OCT in patients with circumscribed choroidal hemangioma (CCH).

### *Photodynamic therapy with verteporfin*

PDT is a treatment modality in which a nontoxic light-sensitive compound called a photosensitizer is administered and subsequently activated by light exposure to producing photochemical effects in the target area. PDT is currently used to treat various types of solid tumors. However, recent improvements in our understanding of the mechanisms of action, light sources, and the development of specific photosensitizing agents with improved selectivity and activity, such as verteporfin (benzoporphyrin derivative monoacid, [BPD-MA]), have expanded the possible therapeutic uses of PDT in ophthalmology [4].

Verteporfin (Visudyne™, Novartis AG, Switzerland) is a potent second-generation photosensitizing agent derived from porphyrin. It is a chlorin-type molecule, which is a chemically stable compound and has been shown to be an efficient generator of singlet oxygen. It is generally believed that the formation of singlet oxygen is the primary mechanism of PDT-induced damage, although this has never been detected in any biological system. In addition to absorption maximum in the UVA range, verteporfin offers an absorption peak between 680–695 nm. Consequently, it can be activated with light from a low-power, nonthermal laser at wavelength that can penetrate blood, melanin, and fibrotic tissue. This leads to the damage of endothelial cells followed by platelet adhesion and degranulation and finally to thrombosis of pathologic vessels selectively within the treated area in vivo.

Pharmacokinetic studies in humans show that the plasma half-life of verteporfin is 5–6 hours. Skin photosensitivity, assessed by a UVB-filtered solar stimulator, showed rapid return to baseline in a dose-dependent manner. At 6 mg/m<sup>2</sup> of body surface area, which is clinically relevant dose being used, no photosensitivity was detected at 24 hours [5, 6]. These findings support the safety of verteporfin.

### *Circumscribed choroidal hemangioma*

CCH is a hamartomatous benign vascular tumor believed to be congenital in origin. It is located in the peripapillary or macular area, not associated with systemic diseases [7].

CCH is initially seen as a nonpigmented orange-red mass that can simulate a choroidal malignancy, such as amelanotic melanoma or metastasis. By ultrasonography, the hemangioma is acoustically solid on B-scan, and the echogenic character is generally similar to that of the surrounding normal choroid. On A-scan ultrasonography, this tumor shows high internal reflectivity. Fluorescein angiography (FA) showed early lacy mild hyperfluorescence in the prearterial or early arterial phase and diffuse intense late hyperfluorescence. Indocyanine green angiography (ICGA) is critical for demonstrating the high-flow state of the choroidal hemangioma with rapid filling by 1 minute into the study followed by a “washout” phenomenon. On magnetic resonance imaging (MRI) there is bright signal on T1- and T2- weighted images. Nevertheless, the diagnosis of CCH continues to be a challenge for many clinicians. It is important to achieve an accurate diagnosis of this benign tumor to reassure patients and provide proper therapy [8].

Asymptomatic CCH lesions should be observed but visually threatening or visually impairing lesions require treatment. Serous retinal detachment accounts for decreased vision in most patients. Secondary neurosensory (cystoid macular edema, CME) and retinal pigment epithelial (RPE) changes were well documented. Leakage recurrence after photocoagulation with progressive loss of vision, radiation complications, or impossibility to treat subfoveal lesions with transpupillary thermotherapy are reasons why these

methods previously used for primary management of CCH are at present replaced by PDT with verteporfin [9].

*Photodynamic therapy with verteporfin in age-related macular degeneration and CCH*

In the field of ophthalmology, PDT with verteporfin is being developed for the management of CNV mainly secondary to age-related macular degeneration (AMD). This technique was also recently used in vascular tumors – circumscribed choroidal hemangioma [10–17], diffuse choroidal hemangioma [18], papillary capillary hemangioma [19], and vasoproliferative tumor of the retina [20].

CCH is classified histopathologically as capillary or cavernous vessels with a normal endothelial lining in contrast to the proliferative neovasculature in CNV with a distinct angiogenic stimulus. Obviously, PDT does, nevertheless, target this type of nonproliferative vessels of choroidal origin. Angiography demonstrated areas with nonperfusion, progressive rarefaction, and finally partial atrophy of the choroidal bed of CCH. A lack of neovascular selectivity was obvious in the ICGA analysis of PDT effects in CNV that showed intensive and persistent occlusion of collateral physiologic choroid. Light microscopy and electron microscopy showed a dose-dependent occlusion of the choroidal layer after endothelial cell damage histologically. Other nearby tissues such as retinal cells and vessels, RPE, and Bruch’s membrane remain intact.

Localization activity may be driven by the perfusion characteristics of a lesion, such as the slower perfusion in CNV and tumors and the increased permeability of neovascular walls with enhanced leakage into the extravascular stroma.

First results of PDT with verteporfin in CCH were excellent in nearly all of 73 patients reported, with an increase in visual acuity, flattening of the tumor, and disappearance of the retinal detachment and intraretinal edema [10–17]. None of the patients developed retinal damage, retinal nonperfusion, or visual field defects. Following treatment, some investigators noted RPE alterations at the site of the original tumor. Persistent, focal choroidal ischemia and atrophy were reported after treatment of prominent lesions with three and more sessions of PDT. There was no recurrence of tumor or subretinal fluid during follow-up periods of 3–50 months.

Also, the lack of serious side effects of PDT for CNV in AMD in 20,000 patients who have been treated as

**Table 1.** Demographic data and treatment methods

	Sex	age (Years)	history (Months)	fellow eye	GLD (µm)	infusion time (min.)	No. of spots
Patient 1	F	38	12	normal	7200	1	1
Patient 2	M	51	11	normal	6700	1	1
Patient 3	M	52	6	normal	7000	1	1
Patient 4	M	41	3	normal	7900	10	1
Patient 5	F	65	12	amblyopic	8900	10	1 <sup>y</sup>
Patient 6	M	73	8	blind	8200	10	2
Patient 7	M	38	0.5	normal	8900	10	2 <sup>x</sup>
Patient 8	M	48	3	normal	8400	10	1 <sup>z</sup>
Patient 9	F	39	60	normal	10900	10	2 <sup>y</sup> +4 <sup>x</sup>
<b>Average</b>		<b>50</b>	<b>15</b>		<b>8200</b>		

x-overlapping spots, y-targeting the most prominent central part of the hemangioma, z-“rotating” spot 4200 µm, GLD – greatest linear diameter

**Table 2.** Pretreatment and final findings

	BCVA before Rx	BCVA at last visit	US before Rx (mm)	US at last visit (mm)	RTPP before Rx (µm)	RTPP at last visit (µm)	Follow-up (months)
Patient 1	4/5	4/4	1.5	0	221	118	18
Patient 2	4/25	4/16	3.3	1.5	334	169	12
Patient 3	4/12	4/4	2.5	0	353	143	12
Patient 4	4/5	4/3	3.2	0 226		126	12
Patient 5	4/25	4/4	3.9	2.0	423	210	3
Patient 6	4/16	4/12	3.2	1.5	256	232	3
Patient 7	4/25	4/5	3.3	0	293	202	3
Patient 8	4/16	4/5	3.6	2.4	849	186	3
Patient 9	1/20	1/15	4.0	0.9	448	321	3
<b>Average</b>	<b>4/16</b>	<b>4/8</b>	<b>3.2</b>	<b>0.9</b>	<b>378</b>	<b>190</b>	<b>8</b>

BCVA – best corrected visual acuity, US – ultrasound, RTPP – retinal thickness at fixation point

of the year 2000 repeatedly worldwide, supports the safety of this treatment [21]. Our own long-term experience confirmed effectiveness of PDT with verteporfin in patients with predominantly classic subfoveal CNV caused by age-related and myopic macular degeneration as well [22].

**Materials and methods**

Nine patients (six males and three females, age range 38–73 years, 50 years in average, see Table 1), referred to our clinic reporting visual impairment caused by CCH, were treated from April 2002 through August 2003. They had not any prior treatment.

All the patients had serous retinal detachment under the foveal centre but were able to maintain fixation. All OCT measurements were performed by one examiner (I.C.). RTPP on Stratus OCT ranged from 221 µm to 849 µm (378 µm in average, see Table 2).

The pretreatment best corrected visual acuity (BCVA), using Early Treatment for Diabetic Retinopathy Study (ETDRS) charts, ranged from 1/20 to 4/5 (mean 4/16, see Table 2). Tumor thickness obtained from standardised A-scan measurements ranged from 1.5 to 4.0 mm, 3.2 mm in average (see Table 2) at initial examination.

Symptoms of decreased vision were present for between 2 weeks to 5 years (15 months in average, see Table 1). Fellow eye was amblyopic in one case (Patient No. 5) and blind in other (Patient No. 6) due to unsuccessful retinal detachment surgery elsewhere. BCVA of remaining eyes was normal (see Table 1).

FA (Fluorescein 10% 5 ml, Alcon, USA) showed pre-existing occult extrafoveal CNV in one case (Patient No. 2), RPE alterations in macula in one case (Patient No. 6), and CME in other (Patient No. 9).

The ICGA image (ICG Pulsion 25 mg, Pulsion, Germany) obtained by the digital imaging system Imagenet 2000, version 2.12 (Topcon Corporation, Tokyo, Japan) with fundus camera 50IX and CCD camera Kodak 1,4i was used to detect the greatest linear dimension (GLD) of the CCH. GLD was measured using PDT function of the software and ranged from 6700 to 10900  $\mu\text{m}$ , 8200  $\mu\text{m}$  in average (see Table 1). ICGA also revealed an extrafoveal plaque in one case in which there were intraretinal fluid observed on Stratus OCT in the macula (Patient No. 2).

No unstable ischaemic heart disease, decompensated arterial hypertension or increased liver tests were detected during internal screening performed before the treatment in all patients.

The local ethical committee approved the study protocol. After obtaining each patient's fully informed consent, PDT was applied using a laser emitting a light at 689 nm (Visulas 690s, version 2.8, Zeiss, Germany). Pulsing aiming beam was projected to the fundus for better resolution in targeting of the tumor. Verteporfin at a dose of 6  $\text{mg}/\text{m}^2$  of body surface area was administered intravenously before laser application. A laser beam with an intensity of 600  $\text{mW}/\text{cm}^2$  was applied to the tumor 5 minutes after the end of verteporfin administration in all cases. The type of contact lens with antireflex covering for diode laser was chosen according to the size of the laser spot (OG3MA, Ocular Instrument for spots up to 3500  $\mu\text{m}$ , OMRA-WF for spots up to 6500  $\mu\text{m}$ , PRP-UF for larger ones with a maximum of 8000  $\mu\text{m}$ ).

Different protocols cited in literature were used regarding infusion time, number of spots, area covered, and number of sessions as follows [10–17].

Prescribed dose was manually infused in 1 minute in the first three patients. Standard regimen with dilution of verteporfin in a volume of 30 ml dextrose 5% solution (infusion time 10 minutes) was used in the remaining six cases (see Table 1).

Single spot was used to treat four smaller tumors (GLD up to 7900  $\mu\text{m}$ ) by covering the whole lesion and was applied also in the fifth case (GLD of 8900  $\mu\text{m}$ ) to the most prominent central part of the hemangioma. Two peripapillary tumors (GLD of 8200  $\mu\text{m}$  and 8900  $\mu\text{m}$  respectively) were treated using two spots which were overlapping in the former case. Laser application time was set at 83 seconds in eight patients. New technique of "rotating" spot (diameter 4200  $\mu\text{m}$ ) was used in one case (GLD of 8400  $\mu\text{m}$ ) for a period of 333 seconds reaching the radiant exposure 50  $\text{J}/\text{cm}^2$  as in all other cases (Figures 1, 2).

Eight patients were treated only once. Patient with the biggest tumor was treated twice: first time two spots targeted the most prominent part of the hemangioma, and after five months the rest of the tumor was treated by four overlapping spots (see Table 1).

All patients underwent a complete ophthalmic evaluation at baseline and subsequently at 1, 3, 6, 12 and 18 months. BCVA, slit-lamp examination, tonometry, biomicroscopy, Stratus OCT, A-scan and B-scan ultrasound examination were performed at baseline and during each visit. FA and ICGA were repeated in the four patients that completed sixth-months or one-year visits. Statistical significance was determined by using paired t-test.

## Results

Table 2 presents the baseline data as well as results from the follow-up of 3–18 months (8 months in average). Macula was flat as verified by resorption of subretinal fluid and normalisation of foveal contour on Stratus OCT in all cases (100%) at the last visit (see Figures 3, 4). Maximal decrease of RTFP was seen within first month after treatment (see Chart 1). Average RTFP decreased from an average of 378  $\mu\text{m}$  (range, 221–849  $\mu\text{m}$ ) at baseline to 190  $\mu\text{m}$  at the last visit (range, 118–321  $\mu\text{m}$ , see Table 2). This decrease of RTFP was significant ( $p=0.017$ ).

As compared to baseline visual acuity improvement (one to seven lines on ETDRS charts) was observed in all cases (100%). BCVA returned to 4/5 or better in six cases (67%), to 4/12, 4/16, and 1/15 in one case respectively (mean 4/8, from 4/16 at study beginning). Improvement of BCVA is statistically significant at  $p=0.0046$ .

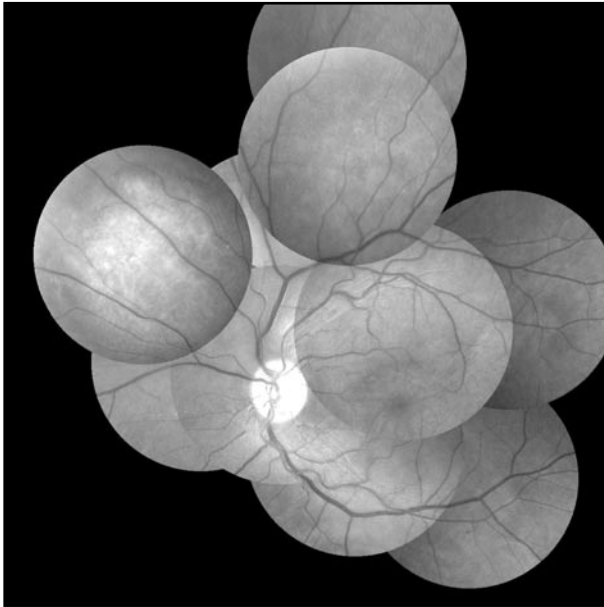
When examined by ultrasound, there was no measurable tumor height in four cases (44%, patients No. 1,3,4, and 7), there were marked reduction in the other five cases (56%, patients No. 2,5,6, 8, and 9). Posttreatment tumor height decreased from an average of 3.2 mm (range, 1.5–4.0 mm) at baseline to 0.9 mm (range, 0–2.4 mm) at the last visit (see Table 2). Regression of tumor height was significant at  $p=0.00003$ .

No eye developed recurrent vision loss, recurrent subretinal exudation or recurrent tumor growth. There were no systemic or ocular complications during the follow up time.

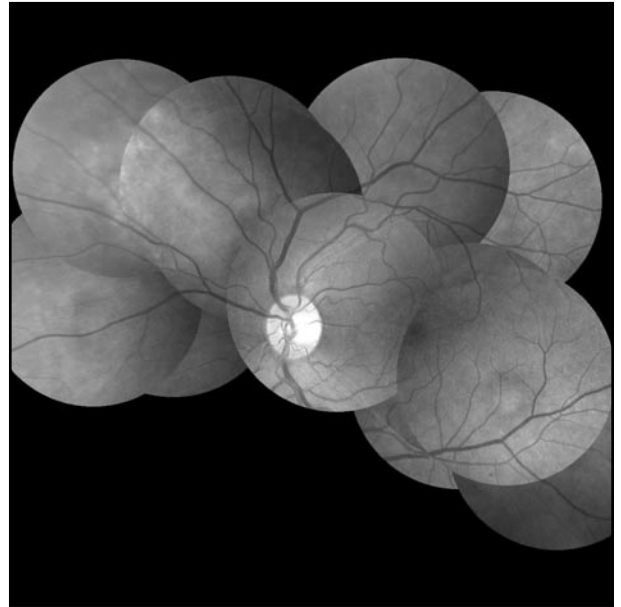
## Discussion

To our knowledge, evaluation of effectiveness of PDT with verteporfin in patients with CCH by close quantitative control of subretinal fluid resolution by OCT was so far not investigated.

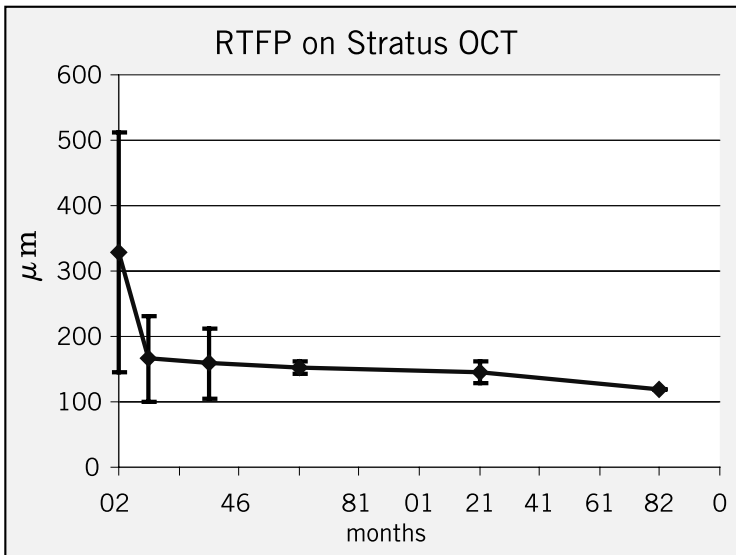
In this study PDT with verteporfin has been successfully employed for management of CCH with wide range of physical parameters of treatment such as power, duration, spot size, and number of spots used in one session. Despite good results the main question, i.e. the endpoint of treatment such as resolution of



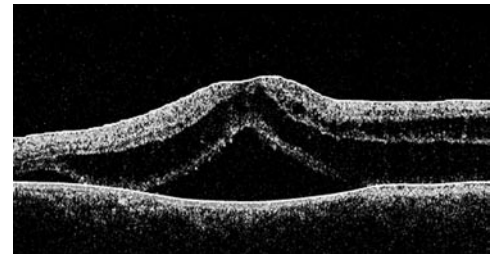
**Figure 1.** Pretreatment mosaic of color fundus photographs with CCH nasal to the optic disc in patient 8.



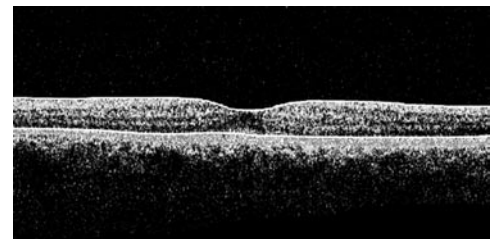
**Figure 2.** Posttreatment mosaic of color fundus photographs with the rest of the tumor in patient 8.



**Chart 1.** Mean retinal thickness at the fixation point (RTFP) value on Stratus OCT during follow up.



**Figure 3.** Pretreatment finding on Stratus OCT with subretinal fluid under the foveal centre in patient 8.



**Figure 4.** Posttreatment finding on Stratus OCT with complete subretinal fluid absorption in patient 8.

leakage and subretinal fluid or complete flattening of tumor remains unanswered.

There was no recurrence of tumor or subretinal fluid after single session of PDT with verteporfin during follow-up periods of 3 to 15 months [12, 15].

Additional PDT courses (up to four consecutive sessions) progressively improved vision, and best BCVA outcomes were regularly seen with complete resolution and flattening of the lesion [13, 14, 16]. Tumor regression was most pronounced after the first session of PDT, 1.5 mm within 6 weeks [13].

In our study different protocols were used regarding the speed of an infusion and the amount of area of the lesion covered by laser spot(s). Eight patients were treated only once (89%). Patient with the biggest tumor was treated twice. BCVA improved together with subretinal fluid absorption and normalisation of foveal contour on Stratus OCT. It occurred most quickly

within the first month of treatment in all patients (see Fig. 1). Functional results were limited only to cases with pre-existing retinal alterations (RPE changes, intraretinal fluid from occult CNV, and CME) [23]. Final BCVA did not depend on the tumor height during follow up after the treatment. The mean regression of tumor height was 2.3 mm within 14 weeks.

We believe that retreatment may not be necessary for incompletely flattened these benign tumors that stop leaking. However the risk for late recurrence remains unknown and the long-term prognosis is guarded. It is not excluded that any late CCH leakage can be managed by repeat session, as in the current approach in CNV [24]. It is published that recurrence of subretinal fluid after scatter laser treatment occurred 2 to 78 months years after treatment [25]. Our follow-up was 8 months in average (range, 3–18 months).

We introduced technique of “rotating” spot in one patient. This would guarantee more homogenous distribution of energy in bigger or peripapillary lesion as compared to application of separate nonsimultaneous spots. Interrupted delivery of energy did not seem to play a role in the final effect, i.e. speed of subretinal fluid resolution, RTFP value, improved vision, decrease of tumor height as compared to the continuous lighting.

In conclusion OCT appears to be useful method for evaluation of subretinal fluid absorption after the treatment of CCH by PDT with verteporfin. RTFP value can be used for quantification of subretinal fluid under the foveal centre. Randomised trial with single versus repeated sessions of PDT with verteporfin are needed to define the endpoint of this treatment.

#### REFERENCE

- 1 Ip MS, Baker BJ, Duker JS et al. Anatomical Outcomes of Surgery for Idiopathic Macular Hole as determined by Optical Coherence Tomography. *Arch Ophthalmol* 2002; **120**:29–35.
- 2 Massin P, Vicaud E, Haouchine B et al. Reproducibility of retinal Mapping Using Optical Coherence Tomography. *Arch Ophthalmol* 2001; **119**:1135–42.
- 3 Cihelkova I, Soucek P. Nalezy na opticke koherentni tomografii u pacientu s makularni degeneraci lecenych pomoci fotodynamicke terapie s preparatem Visudyne. [(Findings on Optical Coherence Tomography in Macular Degeneration with Predominantly Classic Subfoveal Choroidal Neovascularization Treated by Photodynamic Therapy with Visudyne.) (In Czech with English abstract.)] *Ces a slov Oftal* 2003; **59**:250–6.
- 4 Schmidt-Erfurth U, Hasan T. Mechanisms of Action of Photodynamic Therapy with Verteporfin for the Treatment of Age-Related Macular Degeneration. *Surv Ophthalmol* 2000; **45**:195–214.
- 5 Keam SJ, Scott LJ, Curran MP. Verteporfin: a review of its use in the management of subfoveal choroidal neovascularisation. *Drugs* 2003; **63**:2521–54.
- 6 Bakri SJ, Kaiser PK. Verteporfin ocular photodynamic therapy. *Expert Opin Pharmacother* 2004; **5**:195–203.
- 7 Witschel H, Font RL. Hemangioma of the choroid. A clinicopathologic study of 71 cases and a review of literature. *Surv Ophthalmol* 1976; **20**:415–31.
- 8 Shields CL, Honavar SG, Shields JA et al. Circumscribed Choroidal Hemangioma. Clinical Manifestation and Factors Predictive of Visual Outcome in 200 Consecutive Cases. *Ophthalmology* 2001; **108**:2237–48.
- 9 Mashayekhi A, Shields, CL. Circumscribed choroidal hemangioma. *Curr Opin in Ophthalmol* 2003; **14**:142–9.
- 10 Jurkles B, Anastassiou G, Ortman S. et al. Photodynamic therapy using verteporfin in circumscribed choroidal haemangioma. *Br J Ophthalmol* 2003; **87**:84–9.
- 11 Porrini G, Giovannini A, Amato G et al. Photodynamic Therapy of Circumscribed Choroidal Hemangioma. *Ophthalmology* 2003; **110**:674–80.
- 12 Landau IME, Steen B, Seregard S. Photodynamic therapy for circumscribed choroidal haemangioma. *Acta Ophthalmol. Scand* 2002; **80**:531–6.
- 13 Schmidt-Erfurth U, Michels S, Kusserow C et al. Photodynamic Therapy for Symptomatic Choroidal Hemangioma. *Ophthalmology* 2002; **109**:2284–94.
- 14 Robertson DM. Photodynamic Therapy for Choroidal Hemangioma Associated With Serous Retinal Detachment. *Arch Ophthalmol* 2002; **120**:1155–61.
- 15 Madreperla SA. Choroidal Hemangioma Treated With Photodynamic Therapy Using Verteporfin. *Arch Ophthalmol* 2001; **119**:1606–10.
- 16 Barbazetto I, Schmidt-Erfurth U. Photodynamic therapy of choroidal hemangioma: two case reports. *Graefe's Arch Clin Exp Ophthalmol* 2000; **238**:214–21.
- 17 Verbraak FD, Schlingemann RO, Keunen JEE et al. Longstanding symptomatic choroidal hemangioma managed with limited PDT as initial or salvage therapy. *Graefe's Arch Clin Exp Ophthalmol* 2003; **241**:891–8.
- 18 Anand R. Photodynamic therapy for diffuse choroidal hemangioma associated with Sturge Weber syndrome. *Am J Ophthalmol* 2003; **136**:758–60.
- 19 Schmidt-Erfurth UM, Kusserow C, Barbazetto IA et al. Benefits and Complications of Photodynamic Therapy of Papillary Capillary Hemangiomas. *Ophthalmology* 2002; **109**:1256–66.
- 20 Barbazetto IA, Smith RT. Vasoproliferative tumor of the retina treated with PDT. *Retina* 2003; **23**:565–7.
- 21 Messmer KJ, Abel SR. Verteporfin for age-related macular degeneration. *Ann Pharmacother* 2001; **35**:193–8.
- 22 Soucek P, Boguszakova J, Cihelkova I. Fotodynamicka terapie s preparatem Visudyne u makularni degenerace se subfoveolarne ulozenou prevazne klasickou choroidalni neovaskularizaci. [(Photodynamic therapy with Visudyne in Macular Degeneration with Subfoveal Predominantly Classic Choroidal Neovascularization.) (In Czech with English abstract.)] *Ces a slov Oftal* 2002; **58**:89–97.
- 23 Ruby AJ, Jampol LM, Golberg MF et al. Choroidal neovascularization associated with choroidal hemangiomas. *Arch Ophthalmol* 1992; **110**:658–61.
- 24 Soucek P, Cihelkova I. Treatment of macular degeneration (A controlled case). *Neuroendocrinology Letters* 2002; **23**:370–2.
- 25 Sanborn GE, Augsburger JJ, Shields JA. Treatment of circumscribed choroidal hemangiomas. *Ophthalmology* 1982; **89**:1374–80.