

Quantitative study on the effects of chronic ethanol administration on the testis of adult male rat

Gamal H. El-Sokkary

Department of Zoology, Faculty of Science, Assiut University, Assiut-Egypt 71516, Egypt.

Correspondence to: Department of Zoology, Faculty of Science, Assiut University, Assiut-Egypt 71516, Egypt.
TEL: +20 88-401724
FAX: +20 88-312564
E-MAIL: El-Sokkary@UAS.NET

Submitted: January 31, 2001

Accepted: March 25, 2001

Key words: **alcoholism; seminiferous tubules; Leydig cells; ³H-thymidine; labelling index**

Neuroendocrinology Letters 2001; 22:93-99 piii: NEL220201A03 Copyright © Neuroendocrinology Letters 2001

Abstract

OBJECTIVES: Considering the possibility that alcoholism induces gonadal dysfunction, the present work was designed to investigate the morphophysiology of rat testes submitted to experimental alcoholism.

METHODS: Male Sprague-Dawley rats weighing 150 ± 5 gm were chronically given 40% ethanol solution at a dose of 3 g/kg body weight for 30 days. ³H-thymidine autoradiographic investigations and histological studies were carried out to determine the proliferative activity and/or different stages of spermatogenesis in the seminiferous tubule cycle and Leydig cells.

RESULTS: The ³H-thymidine autoradiographic investigation revealed that there was a significant inhibition in the proliferative activity of the spermatogonia in all stages of the seminiferous tubule cycle in the alcohol-treated rats versus controls as indicated by the values of ³H-labelling indices. The histological and numerical investigations indicated that the alcohol-treated rats presented testicular lesions including a significant decrease in the diameter of the seminiferous tubules, the number of different germ cells in all stages of the seminiferous tubule cycle and the presence of degenerative germ cells. In addition, there was a significant decrease in the number of Leydig cells.

CONCLUSION: The present work suggests the deleterious effects of alcohol on the testes. These effects may be due to the effect of alcohol on the gonadotrophic cells of the pituitary gland and/or directly on the seminiferous tubules and Leydig cells.

Introduction

It is well known that alcoholism impairs reproductive performance in experimental animals and human [1, 2] but it is still a matter of discussion which site in the organism is the most susceptible to the deleterious effects of this drug. Alcoholics often have fertility disturbances with low sperm count and impaired sperm motility [3]. Ethanol also has an adverse effect on sperm maturation, which may be affected due to the decrease in sperm/epididymal testosterone and dihydrotestosterone level and epididymal secretory products. Haider et al. [2] pointed out that the chief alcohol-induced testicular changes include: 1. loss of typical arrangement of elongated spermatids, dominance of duplicated form of elongated spermatids; 2. thickening, hyalinosis, and sclerosis of lamina propria with nearly complete lack of Ca^{++} -ATPase; 3. decrease of 3β -hydroxy steroid dehydrogenase and 17β -hydroxy steroid dehydrogenase activity in the Leydig cells, and 4. appearance of oval or spindle shaped mast cells in the interstitial tissue.

They also reported that the lamina propria seems to be the main target of deleterious effects of alcohol. Sufficient experimental data are now available on the effect of alcohol on the hypothalamic-pituitary-gonadal axis. It has been reported that chronic alcohol consumption exerts a suppressive effect on gonadotropins in the pituitary gland [4–7]. The significant reduction of the androgen binding sites in the pituitary gland of alcohol treated rats was observed by Chung [8]. In addition, chronic alcohol consumption was found to cause a reduction of the nuclear androgen receptors in the hypothalamus and pituitary gland of male rats [9].

Studies of Rettori and McCann [10] indicated that alcohol suppresses reproduction in humans, monkeys and rodents by inhibiting the release of luteinizing hormone (LH). After 10 days of feeding a 6% ethanol liquid diet, Steiner et al. [11] reported that serum testosterone levels were markedly decreased as was the rate of different stages of puberty (35, 50 and 65 days old).

The aforementioned studies on the effect of alcohol on the gonads have focused on the evaluation of hormones and examination of the morphology of the gonadotropins and function of gonadotropins. In a previous study, we found that chronic ethanol administration significantly increased lipid peroxidation of the testes. This study was designed to quantitatively study the effect of chronic administration of alcohol on the seminiferous tubule cycle, Leydig cells, and proliferation of spermatogonia in male adult albino rats.

Material and methods

Animals and treatments

30 adult male Sprague-Dawley rats weighing 150 ± 5 gm purchased from Assiut University Joint Animal Breeding were used in the present study. All rats were kept under the same laboratory conditions of temperature ($25 \pm 2^\circ\text{C}$), lighting (12:12 light:dark cycle) and were given free access of standard food and tap water. The animals were divided into two groups. The first group (16 rats) was daily given subcutaneous injections of 40% ethanol in saline for 30 days at a dose of 3 g/kg body weight. The second group (14 rats) was given equal doses of the saline solution only and served as control.

Chemicals

Tritiated thymidine was purchased from New England Nuclear (Boston, Mass.). Kodak NTB2 emulsion, Kodak D19 developer and Kodak fixer were purchased from Estman Kodak (Rochester, New York). All other chemicals were of the highest quality available.

Autoradiography and Quantitation of Autoradiographs

One day after the last injection of alcohol, 7 rats from the controls and 8 from the alcohol-treated group were sacrificed. Two hours before sacrificing, the rats received a subcutaneous injection of 1 mCi/gm body weight tritiated thymidine (^3H -methyl thymidine [^3H] TDR specific activity 6.7 Ci/m mol. New England Nuclear (NEN) Boston, Mass.). Specimens from the testes were taken and fixed in 10% buffered neutral formalin. Paraffin sections of 5 microns thickness were prepared.

The autoradiographs were prepared by dipping the deparaffinized sections in Kodak emulsion NTB2 diluted 1:1 with distilled water and stored at 4°C for 26 days. After developing and washing, the slides were stained with haematoxylin and eosin. The spermatogonial cells were scored for the presence of silver grains over the nuclei, five silver grains constituting a labelled cell. All labelled and unlabelled spermatogonia in the 8 stages of the seminiferous tubules were counted. The ^3H -labelling index (LI) was expressed as the percentage of labelled spermatogonia.

Histology and Quantitation of Seminiferous Epithelial Cycle and Leydig Cell

7 rats from the controls and 8 from alcohol-treated group were sacrificed concomitantly with the previous rats and specimens of testes were taken, fixed, embedded in paraffin, sectioned and stained with hae-

matoxylin and eosin. The identification of the different stages of seminiferous epithelial cycle was based on the morphological changes of the germ cell nuclei and the local arrangement of the spermatids [12, 13].

Using an ocular micrometer at a magnification of 400X performed the measurements of the seminiferous tubule diameters. A total number of 100 rounded seminiferous tubule diameters were measured for each animal.

The number of Leydig cells/mm² (unit area) was counted using the square grid (area/mm²) at a magnification of 1000X. The Leydig cells in 25 unit areas were counted.

The volume of Leydig cells nuclei was performed using ocular micrometer at magnification of 1000X. A total number of 250 nuclei were measured/animal. The measurements were carried out in two ways. The first concerned rounded nuclei of Leydig cells where the formula of the sphere was applied

$$V = 4/3\pi r^3$$

The second concerned oval nuclei of Leydig cells. The volume of the nucleus was obtained by means of revolution spheroid

$$V = p/6 AP^2$$

where A → long diameter P → short diameter [14].

Statistics

All results are presented as means ± SE. Statistical comparison between means was performed by using Student's t-test.

Results

The seminiferous tubules

In the alcohol-treated rats, the diameters of the seminiferous tubules decreased when compared with those of control animals, as shown in Figures 1 and 2. The majority of seminiferous tubules of alcohol-treated rats were characterized by the presence of

degenerating germ cells and contained vacuoles of varying sizes, as shown in Figure 4. The number of germ cells in all stages of the seminiferous tubule sharply decreased in alcohol-treated rats compared to those of controls (Fig.3).

The quantitative results are presented in Table 1. Statistically, there was a highly significant decrease (P < 0.01) in the mean diameter of the seminiferous tubules in alcohol-treated rats versus controls. Also, there was a highly significant reduction (P < 0.01) in the mean number of different germ cell types in all stages of the seminiferous tubules in alcohol-treated rats versus controls.

The frequency and stages of the seminiferous epithelial cycle are presented in Table 2. As can be seen, the frequencies of stages VI, VII and VIII were low in rats given alcohol compared with those of controls.

The interstitial cells of Leydig

As seen in Figures 1 and 2 there was a sharp drop in the number of Leydig cells in the testes of alcohol-treated rats when compared with those of controls. The quantitative results of the number and nuclear volume of Leydig cells are presented in Table 3. As shown, there was a highly significant decrease (P < 0.01) in the mean number of Leydig cells/mm² (unit area) in alcohol-treated rats versus controls. Also, the quantitative data revealed that there was a highly significant reduction (P < 0.01) in the mean volume of nuclei of Leydig cells in alcohol-treated rats versus controls.

Autoradiography and spermatogonial proliferation

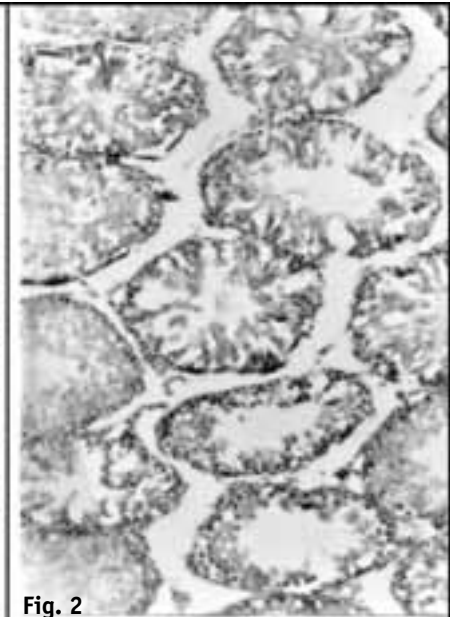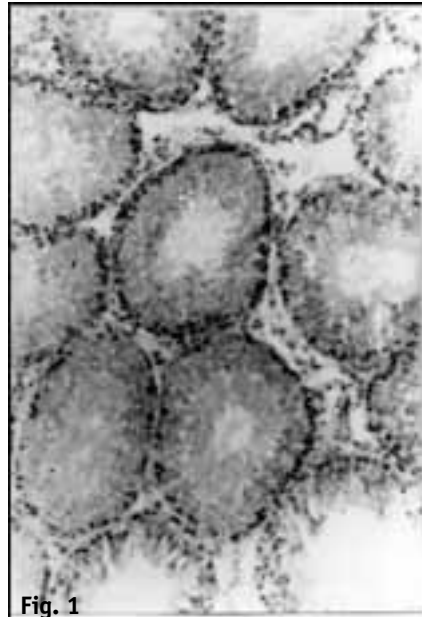In alcohol-treated rats, the number of labelled spermatogonia in the different stages of seminiferous tubule cycle was lower than that of control rats, as shown in Figures 5 and 6. The quantitative results of autoradiographic study are presented in Table 4.

Table 1. Mean number of cells (± S.E) in different stages of the seminiferous epithelial cycle and the mean diameter of seminiferous tubules (± S.E) in control and alcohol-treated rats.

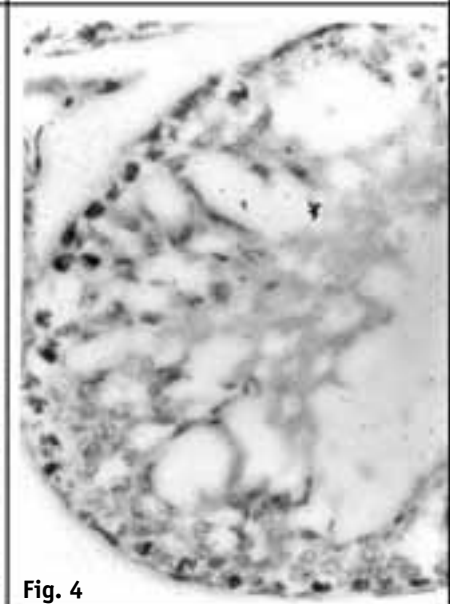
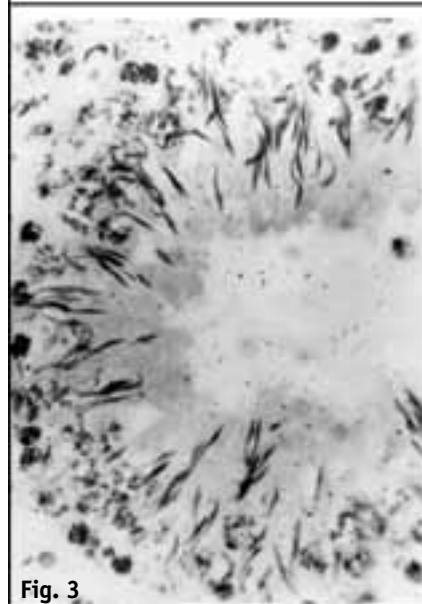
Stages	Sertoli cells	Spermatogonia			Primary spermatocytes				Secondary spermatocytes	Spermatids				Diameter of seminiferous tubule
		Type A	Type B	Total	Preleptotene	Zygotene	Pachytene	Diplotene & Diakinese		Sa	Sb	Sc	Sd	
Experiment														
Control group	110 ± 5.03	112 ± 3.00	219 ± 11.30	331 ± 10.31	11.51 ± 2.35	261 ± 8.31	343 ± 10.99	76 ± 4.22	69 ± 4.35	958 ± 24.70	125 ± 8.60	253 ± 12.50	859 ± 27.60	225.3 ± 3.01
Alcohol-treated group	74* ± 6.11	68* ± 3.92	98* ± 4.38	166* ± 3.34	6.12* ± 1.43	121* ± 3.21	152* ± 5.80	50* ± 3.31	32* ± 3.20	261* ± 10.06	71* ± 4.40	124* ± 5.60	191* ± 6.38	178.3* ± 4.09

*P<0.01; S.E: standard error

Figs. 1, 2. T.S. of testis of control (1) and alcohol-treated rats (2) showing the alterations in the seminiferous tubules and Leydig cells (H&E X 400).



Figs. 3, 4. T.S. of testis of control (3) and alcohol-treated rats (4) showing different stages of the seminiferous tubule cycle (H&E X 400). The stages of the alcohol-treated rats present several degenerative germ cells and vacuoles.



Figs. 5, 6. T. S. of testis of control (5) and alcohol-treated rats (6) showing the distribution of labelled spermatogonia in different stages of seminiferous tubule cycle (H&E X1000). The 3H-labelled spermatogonia sharply decreased in alcoholized rats.

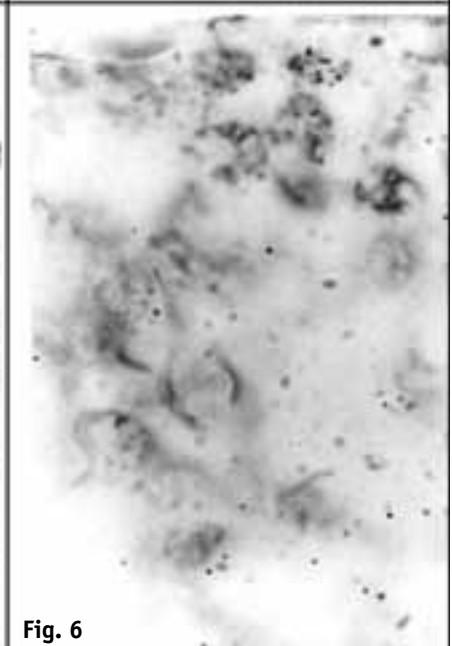
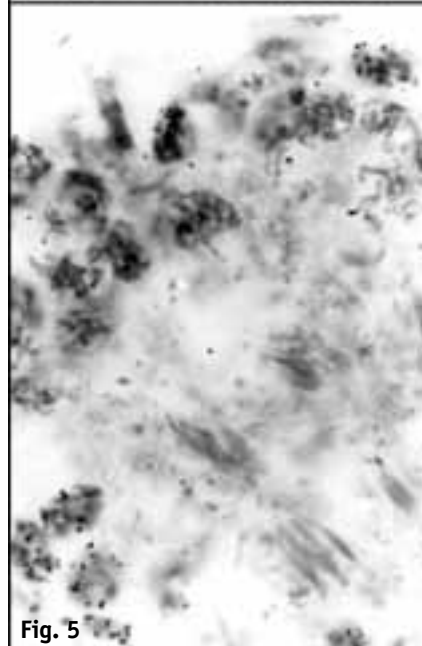


Table 2. Frequency of the stages of the seminiferous epithelial cycle.

Stages \ Groups	Stages							
	I	II	III	IV	V	VI	VII	VIII
Control group	5.11	6.85	24.10	3.00	20.20	8.56	8.50	20.13
Alcohol-treated group	30.90	4.60	17.95	1.85	34.38	2.41	1.88	1.35

Table 3. Means of number and nuclear volume of a leydig cells in control and alcohol-treated rats.

Groups \ Measurements	Measurements	
	Mean number of Leydig cells \pm S.E	Mean nuclear volume of Leydig cells \pm S.E
Control group	27.6 \pm 2.01	80.18 \pm 3.80
Alcohol-treated group	10.93* \pm 0.98	30.37* \pm 2.75

*P<0.01; S.E: standard error.

Table 4. Mean ³H-labelling indices (\pm S.E) in spermatogonia of all stages of seminiferous tubules in control and alcohol-treated rats.

Stages \ Groups	Stages									Mean
	I	II	III	IV	V	VI	VII	VIII		
Control group	17.09 \pm 0.85	10.85 \pm 0.76	11.02 \pm 1.13	17.73 \pm 1.50	12.04 \pm 0.53	20.23 \pm 0.59	17.89 \pm 0.86	11.22 \pm 0.65	14.76 \pm 1.36	
Alcohol-treated group	8.91* \pm 0.40	6.60* \pm 0.75	7.50* \pm 0.26	8.15* \pm 0.33	5.92* \pm 0.49	9.19* \pm 0.59	8.80* \pm 0.31	6.08 \pm 0.18	7.64* \pm 0.47	

*P<0.01; S.E: standard error.

As shown, the mean ³H-labelling index (LI) was highly significant decreased (P<0.01) in spermatogonia of each stage in the seminiferous tubule cycle of alcohol-treated rats versus controls. In addition, the mean value of LI in the spermatogonia of all stages of the seminiferous tubule cycle as a whole decreased highly significant (P<0.01) in rats given alcohol versus controls. The above data revealed that there was a sharp suppression in the proliferative activity of the spermatogonia of alcohol-treated rats.

Discussion

It is generally accepted that chronic alcohol consumption impairs reproductive performance in male rats [5, 9, 15, 16]. Acting as a direct toxic through different mechanisms, alcohol causes many hormonal changes, which induce sexual functional impairment and fertility problems [17]. These authors pointed out that the area of the seminiferous tubule is reduced in alcoholic rats. The qualitative and quantitative data of the present study support this assumption. The results of the present work showed that chronic administration of alcohol (ethanol) caused testicular lesions including significant decrease in the diameter

of seminiferous tubules, the number of spermatogonic cells, and the presence of degenerating germ cells and vacuoles of varying sizes. Also, there was a significant decrease in the number and nuclear volume of Leydig cells. In addition, there was a significant inhibition in the proliferation of spermatogonia in the seminiferous tubules of alcohol-treated rates as indicated by the significant decrease of the mean value of the ³H-labelling index.

Evidence for an inhibitory role of alcohol on the hypothalamic-pituitary-gonadal axis in male rats were described by a number of authors [1, 5, 7, 18–20]. Alcohol exerts a suppressive effect on the content of androgen receptors and secretory function of the gonadotrops in the pituitary gland [8]. This author found also that the number of androgen binding sites was significantly reduced and the concentration of serum luteinizing hormone (LH) was significantly lower in alcohol-treated animals when compared to those of controls. Cicero et al. [7] found that alcohol strongly suppressed serum LH levels in male adult rats. Moreover, the in vitro studies of McGivern et al. [21] revealed that Leydig cells from male rats prenatally exposed to alcohol produced a marked insensitivity of the cells to LH. There is evidence that alcohol

treatment suppresses reproduction by reducing the release of LH [10,20] and thereby markedly decreasing serum testosterone in rats [11, 16, 22, 23]. Decreases in the circulating levels of LH and/or the activity of testicular steroidogenic enzymes have been proposed as putative mechanisms underlying this inhibitory effect [20].

The findings of Babichev et al. [9] showed that administration of a 25% ethanol-saline solution in male rats at a dose of 7.5 g/kg body weight of the course of 5 days significantly decreased serum testosterone level. They observed marked reduction of the nuclear androgen receptors in the preoptic-anterior hypothalamic area (POA), mediobasal hypothalamus (MBH) and pituitary gland of alcohol-treated rats. Unlike the androgen receptors, the number of nuclear estradiol-binding sites in POA was significantly increased in these males. Thus, the results demonstrated that repeated administration of ethanol induced a decrement in serum testosterone and in the number of androgen receptors in MBH and pituitary gland that possibly results in reduction in the negative feedback mechanism between the gonads and pituitary gland.

The report of Esquifino et al. [6] provided strong evidence of the effect of ethanol on the hypothalamic-hypophyseal-testicular function. In this report, it was postulated that there was an increase in the plasma prolactin level together with a reduction in the basal LH levels in alcohol-treated rats. An exaggerated response of LH to the luteinizing hormone-releasing hormone was also evident in rats treated with alcohol for 2 weeks. Also, it was found that gonadotropin-stimulated plasma testosterone levels were diminished in alcohol-treated rats compared with controls. In addition, plasma estradiol levels were increased in alcohol-treated rats. Esquifino et al. [6] suggested a direct suppressive effect of ethanol on LH release early in the treatment with the subsequent elevations in plasma estradiol and prolactin levels possibly contributing in the maintenance of hypogonadism after chronic ethanol administration. Frias et al. [23] demonstrated that acute alcohol intoxication produces in adolescents a high increase in plasma prolactin, ACTH, and cortisol, and the opposite behavior of testosterone according to gender; plasma testosterone was increased in females and decreased in males. They also reported that the decrease in testosterone and increase in beta-endorphin in males suggests that acute alcohol intoxication could have an inhibitory effect on testosterone, perhaps mediated by beta-endorphin.

Bortolussi et al. [24] pointed out that the pituitary gonadotropins, FSH and LH exert an overall control on testicular development by interacting with membrane receptors expressed by Sertoli cells and Leydig

cells. These data may explain the results of the present work.

It is well established that alcohol dehydrogenase in the testis of rat metabolizes ethanol [25, 26]. The investigations of Murolo and Fisher-Simpson [25] revealed that ethanol metabolism to acetaldehyde by alcohol dehydrogenase activity reduced androgen secretion by rat Leydig cells. Furthermore, studies in the localization of alcohol dehydrogenase activity in the testis of rat were done by Yamauchi et al. [26]. They revealed the presence of the enzyme activity in either Leydig cells or in seminiferous tubules alone or at both sites. In vitro studies using isolated Leydig cells indicated that ethanol inhibited testosterone synthesis in rats [27]. The ethanol-induced inhibition was reversed by 4-methylpyrazole, an alcohol dehydrogenase inhibitor, suggesting that ethanol metabolism was responsible for this inhibition. In addition, findings of Srikanth et al. [28] suggested that the ethanol treatment impairs Leydig cellular NADPH-generating enzymes such as glucose-6-phosphate dehydrogenase (G-6-PDH), and 6-phosphogluconate dehydrogenase (6-PGDH) which may be one of the biochemical mechanisms mediating the direct and indirect effects of ethanol which result in hypoandrogenism. In premenopausal women, Sarkola et al. [29] found a development of hyperandrogenism and loss of female sexual characteristics associated with heavy alcohol consumption. Therefore, it may conclude that the deleterious effect of ethanol on the Leydig cells and seminiferous tubules observed in the present work was resulted from the metabolism of ethanol by alcohol dehydrogenase.

The interaction of ethanol with testicular subcellular membranes contributes, at least in part, to alcohol-induced gonadal dysfunction in adult rats [30]. The observations of these authors showed that alcohol-treated rats exhibited a reduced testes/body ratio. Mitochondrial enriched extracts obtained from the testes of the alcohol-treated rats showed significant increases in the malondialdehyde formation; moreover, glutathione levels were reduced in the testes of alcohol-treated rats. Somani et al. [31] reported that ethanol significantly augmented glutathione peroxidase (GSH-Px) activity in the hypothalamus. Bekpınar and Tugrul [32] and El-Sokkary et al. [33] pointed out that the testicular levels of lipid peroxide were increased by alcohol. These findings suggested that lipid peroxidation is a consequence of ethanol metabolism which may be involved, at least in part, in testicular dysfunction in alcohol-treated rats. Results of Shirai and Ikemoto [22] indicated that alcohol damage influencing the testicular interstitial cells and the seminiferous tubules, particularly the Sertoli cells and peritubular wall of the latter. Also, Zhu et al. [34] reported that chronic alcohol administration to

male animals is associated with testicular atrophy and gonadal failure. The Sertoli cell seems to be the first testicular cell injured as a result of alcohol exposure.

Taken together, from the data of the present work and those of the aforementioned studies, it may be concluded that alcohol exerts a strong suppressive effect of the structure and function of the rat testes. In addition, the present work suggests that the deleterious effects of alcohol on the testes may occur either indirectly through its effect on gonadotropins secretion from the pituitary gland and/or directly on the Leydig cells and seminiferous tubules as a result of its metabolism.

REFERENCES

- 1 Van Thiel DH, Gavaler JS, Cobb CF, Sherins RJ, Lester R. Alcohol-induced testicular atrophy in the adult male rat. *Endocrinology* 1979; **105**:888–895.
- 2 Haider SG, Hofmann N, Passia D. Morphological and enzyme-histochemical observations on alcohol induced disturbances in testes of two patients. *Andrologia* 1985; **17**:532–540.
- 3 Srikanth V, Malini T, Arunakaran J, Govindarajulu P, Balasubramanian K. Effects of ethanol treatment on epididymal secretory products and sperm maturation in albino rats. *J Pharmacol Exp Ther* 1999; **288**:509–515.
- 4 Cicero T, Badger T. Effects of alcohol on the hypothalamic-pituitary-gonadal axis in the male rat. *J Pharmacol Exp Ther* 1977; **201**:427–433.
- 5 Somer L, Wrobel KH, Schimmel M. Castration in rat adihypafter long-term alcohol consumption. *Acta Anat* 1988; **131**:41–46.
- 6 Esquifino AI, Mateos A, Agrasal C, Martin I, Canovas JM, Feroso J. Time-dependent effects of alcohol on hypothalamic-hypophysial-testicular function in the rat. *Alcoholism* 1989; **13**:219–223.
- 7 Cicero TJ, Greenwald J, Nock B, O'Connor L. Castration-induced changes in the response of the hypothalamic-pituitary axis to alcohol in the male rat. *J Pharmacol Exp Ther* 1990; **252**:456–461.
- 8 Chung KW. Effects of alcohol feeding on androgen receptors in the rat pituitary gland. *Life Sci* 1987; **41**:2077–2082.
- 9 Babichev VN, Peryshkova TA, Aivazashvili NI, Shishkina IV. Effect of alcohol on the content of sex steroid receptors in the hypothalamus and hypophysis of male rats. *Bull Eksp Biol Med* 1989; **107**:204–207.
- 10 Rettori V, McCann SM. The mechanism of action of alcohol to suppress gonadotropin secretion. *Mol Psychiatry* 1997; **2**:350–354.
- 11 Steiner JC, LaPaglia N, Hansen M, Emanuele NV, Emanuele MA. Effect of chronic ethanol on reproductive and growth hormones in the peripubertal male rat. *J endocrinol.* 1997; **154**:363–370.
- 12 Clermont Y. Kinetics of spermatogenesis in mammals: Seminiferous epithelium cycle and spermatogonial renewal. *Physiol Rev* 1972; **52**:198–236.
- 13 Selim AA, Hassanein AM, Gamal AM. Quantitative cytological studies on the effect of constant darkness on the testis of albino rat. *Assiut Vet Med J* 1986; **16**:31–45.
- 14 Lewinski A, Vaughan MK, Champney TH, Reiter RJ, Smith NKR. Inhibitory action of the pineal gland on nuclear volume of thyroid follicular cells in male gerbils. *Exp Clin Endocrinol* 1984; **84**:239–244.
- 15 de Oliveira C, Ferrira AL. Effect of alcohol on the rat juxtaprostatic pelvic ganglia and gonads. *Gegenbaurs Morphol Jahrb* 1987; **133**:771–780.
- 16 Emanuele NV, LaPaglia N, Vogl W, Steiner J, Kirsteins L, Emanuele MA. Impact and reversibility of chronic ethanol feeding on the reproductive axis in the peripubertal male rat. *Endocrine* 1999; **11**:277–284.
- 17 Calleja EJ, Rodriguez TLA, Fernandez BE, Vaquero PC. Testicular changes produced by alcohol. *Actas Urologicas Espanolas* 1997; **21**:337–342.
- 18 Symons AM, Marks V. The effects of alcohol on weight gain and the hypothalamic-pituitary-gonadotrophin axis in the maturing male rat. *Biochem Pharmacol* 1975; **24**:955–958.
- 19 Inoue K, Tanaka S, Kurosumi K. Mitotic activity of gonadotropins in the anterior pituitary of the castrated male rat. *Cell Tissue Res* 1985; **240**:271–276.
- 20 Rivier C. Alcohol rapidly lowers plasma testosterone levels in the rat: evidence that a neural brain-gonadal pathway may be important for decreased testicular responsiveness to gonadotropin. *Alcohol Clin Exp Res* 1999; **23**:38–45.
- 21 McGivern RF, Raum WJ, Salido E, Redei E. Lack of prenatal testosterone surge in fetal rats exposed to alcohol: alterations in testicular morphology and physiology. *Alcoholism* 1988; **12**:243–247.
- 22 Shirai T, Ikemoto I. mechanism of alcoholic testicular damage. *Nippon Hinyokika Gakkai Zasshi-Japanese J Urol* 1992; **83**:305–314.
- 23 Frias J, Rodriguez R, Torres JM, Ruiz E, Ortega E. Effects of acute alcohol intoxication on pituitary-gonadal axis hormones, pituitary-adrenal axis hormones, beta-endorphin and prolactin in human adolescents of both sexes. *Life Sci* 2000; **67**:1081–1086.
- 24 Bortolussi M, Zanchetta R, Belvedere P, Colombo L. Sertoli and Leydig cell numbers and gonadotropin receptors in rat testis from birth to puberty. *Cell Tissue Res* 1990; **260**:185–191.
- 25 Murono EP, Fisher-Simpson V. Partial characterization of alcohol dehydrogenase activity in purified rat Leydig cells. *Arch Androl* 1986; **17**:39–47.
- 26 Yamauchi M, Potter JJ, Mezey E. Detection and localization of immunoreactive alcohol dehydrogenase protein in the rat testis. *Alcoholism* 1988; **12**:143–146.
- 27 Orpana AK, Harkonen M, Eriksson CJ. Ethanol-induced inhibition of testosterone biosynthesis in rat Leydig cells: role of mitochondrial substrate shuttles and citrate. *Alcohol Alcoholism* 1990; **25**:499–507.
- 28 Srikanth V, Balasubramanian K, Govindarajulu P. Effects of ethanol treatment on Leydig cellular NADPH-generating enzymes and lipid profiles. *Endocrine J* 1995; **42**:705–712.
- 29 Sarkola T, Fukunaga T, Makisalo H, Eriksson CJ. Acute effect of alcohol on androgens in premenopausal women. *Alcohol Alcoholism* 2000; **35**:84–90.
- 30 Rosenblum FR, Gavaler JS, Van Thiel DH. Vitamin A at pharmacologic doses ameliorates the membrane lipid peroxidation injury and testicular atrophy that occurs with chronic alcohol feeding in rats. *Alcohol Alcoholism* 1987; **22**:241–249.
- 31 Somani SM, Husain K, Diaz-Phillips L, Lanzotti KR, Trammell GL. Interaction of exercise and ethanol on antioxidant enzymes in brain regions in the rat. *Alcohol* 1996; **3**:603–610.
- 32 Bekpinar S, Tugrul Y. Influence of selenium supplementation in non-toxic doses on testis lipid peroxide and antioxidant levels in chronic alcohol-fed rats. *Alcohol Alcoholism.* 1995; **30**:645–650.
- 33 El-Sokkary GH, Reiter RJ, Tan DX, Kim SJ, Cabrera J. Inhibitory effect of melatonin on products of lipid peroxidation resulting from chronic ethanol administration. *Alcohol Alcoholism* 1999; **34**:842–850.
- 34 Zhu Q, Van Thiel DH, Gavaler JS. Effects of ethanol on rat Sertoli cell function: studies in vitro. *Alcoholism Clin Exp Res* 1997; **21**:1409.