

Sudden loss of vision due to breast cancer metastasis to the eyeball

Zbigniew S. ANTOSZ¹, Jerzy WALOCHA², Ryszard PORĘBA³, Urszula SIOMA-MARKOWSKA³

¹ Department of Pathology, Megrez Sp. z o.o. Regional Specialist Hospital, Tychy, Poland

² Department of Anatomy, Collegium Medicum, Jagiellonian University, Kraków, Poland

³ Department and Chair of Obstetrics and Gynecology, Medical University of Silesia, Katowice, Poland

Correspondence to: Zbigniew Antosz, MD.

Department of Pathology, Megrez Sp z o.o. Regional Specialist Hospital

Ul. Edukacji 102, PL, 43-100 Tychy, Poland.

FAX: +48-32-3255370; E-MAIL: antosz@mp.pl

Submitted: 2014-01-15 Accepted: 2014-03-03 Published online: 2014-07-15

Key words: **distant metastasis; choroid; breast carcinoma**

Neuroendocrinol Lett 2014; **35**(4):249–251 PMID: 25038605 NEL350414C01 © 2014 Neuroendocrinology Letters • www.nel.edu

Abstract

Intraocular choroidal metastasis is a very rare cause of blindness. Carcinoma of breast is the most common primary malignancy the accounts for choroidal metastasis in females. Other primary neoplasms which can uncommonly metastasize to the choroid are gastrointestinal tract, thyroid, pancreas, prostate and testis. Metastatic neoplasm to the eye outnumbers the primary tumors such as retinoblastoma and malignant melanoma. We present a case of sudden loss of vision due to breast cancer metastasis to the eyeball. The interval between the diagnosis of the primary tumor and the choroidal metastasis was 4 years.

INTRODUCTION

The choroid is the most vascular tissue in the eye supplied by about 20 short and long posterior ciliary arteries. Histologically four layers can be identified in the transverse section of the choroid: suprachoroid, vascular stroma, choriocapillaris, and lamina vitrea (Bruch's membrane). The choroidal stroma can be divided into layers based on the caliber of these vessels: an outer layer of larger vessels (Haller's layer), an inner layer of smaller vessels (Sattler's layer). The last layer may give rise to choriocapillaris. The choriocapillaris is composed of large, fenestrated capillaries, which anastomose between themselves and provide nutrients to five outer layers of the retina. The most common source of metastasis to the eye is the breast. 85% of them are metastases to the choroid (Demirici *et al.* 2003). Metastases to extraorbital eye muscles and bilateral metastases are considered very rare (Amichetti *et al.* 2000). They typically occur about three years after the diagnosis of breast cancer (Shields

et al. 1997)). Early diagnosis is very important in case of response to the treatment. Often overlooked ocular symptoms in 11% of patients are the first symptoms of metastatic breast cancer (Wiegel *et al.* 1998). Metastases of breast cancer in men are very rare but should also be born in mind (Silvestris *et al.* 2003)).

CASE DESCRIPTION

A 65-year-old patient with chronic hepatitis C was admitted to the infectious diseases department in order to undergo routine examination. Four years ago, she has been treated surgically for breast cancer with metastases to the axillary lymph nodes. Then she underwent adjuvant therapy (chemotherapy and radiotherapy). She did not complain of any eye ailments. After several days of hospitalization sudden, progressive loss of vision in the left eye occurred. Additional tests were performed: ultrasound (Figure 1) and angiography (Figure 2). Ophthalmological examination

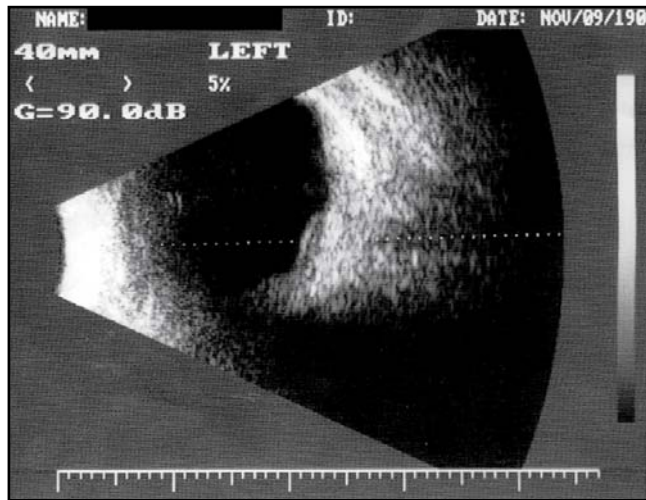


Fig. 1. Ultrasound.

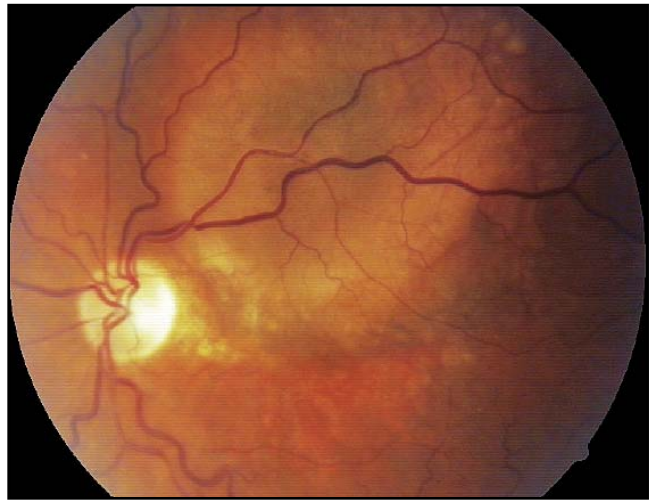

Fig. 2. Angiography.

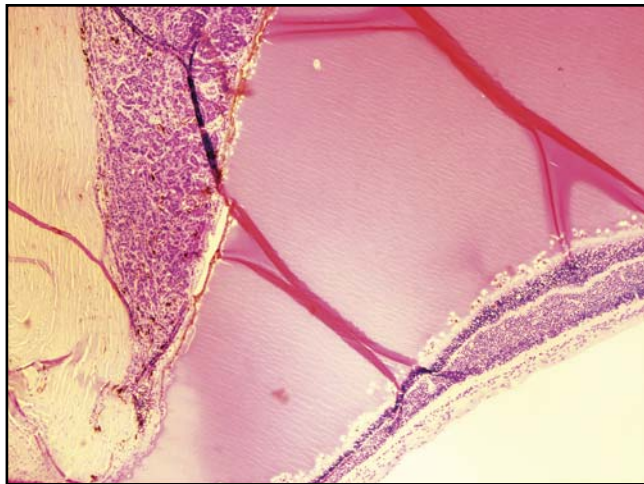


Fig. 3. Histological examination $\times 40$.

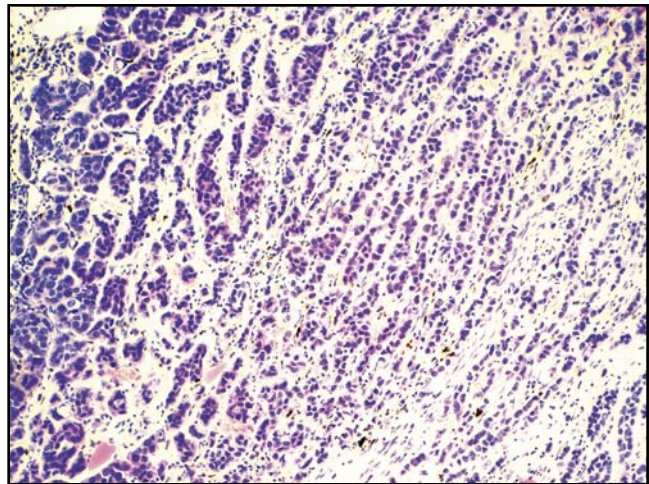


Fig. 4. Histological examination $\times 100$.

revealed no light perception in the left eye. Intralobular tumor with retinal ablation and amaurosis of the left eye were diagnosed. After 5 months the patient consented to the removal of the eyeball; the operation was performed on November 2004. Histological examination results were the following: *Metastatic lobular carcinoma from the breast to the choroid* (Figures 3 and 4). In the years 2008–2009 multiple metastases to the mediastinal lymph nodes were revealed. On May 6, 2009 the patient died with symptoms of multiorgan failure.

DISCUSSION

Ocular metastasis usually strikes the choroid, layers of blood vessels that nourish the posterior 5/6 of the eye. The most common site of uveal metastasis from breast carcinoma is the choroid (85%), followed by iris (3%) and ciliary body (<1%) (Demirci *et al.* 2003). Choroidal metastasis usually develops late in the disease. The data in literature regarding the incidence of breast cancer metastases to the eye must be approached

with caution, however, as these metastases occur far more frequently than in the clinical observations, upon which the literature is based. Bloch and colleagues microscopical examinations report revealed metastases to the choroid of the eye in 37% of patients who died from breast cancer (Bloch *et al.* 1971). Part of the ocular metastases are asymptomatic, some of the subtle symptoms are associated with poor general condition of the patient, and finally, the rarity of occurrence explains why all patients are not tested ophthalmologically. Our patient did not show report of eye ailments four years after the mastectomy. Additional routine tests did not show other abnormalities, the patient was admitted to the screening due to chronic hepatitis C. Within four days of her stay in the hospital, she suddenly lost the sight in her left eye; ophthalmic examination revealed no perception of light in that eye. In this case, the mechanism of eye damage is known – the tumor was 1 cm diameter, located in the posterior chamber of the eye, caused retinal detachment and damage to the optic apparatus (Coleman *et al.* 1974). In our patient the

metastasis to the eye occurred four years after mastectomy and five years after the diagnosis of the metastasis the patient died. Cases of even complete regression of the metastatic changes under the influence of combined treatment with chemotherapy (Paclitaxel) using monoclonal anti-HER2 antibodies (Trastuzumab) have been observed (Papageorgiou *et al.* 2009). Earliness of diagnosis of metastases as well as appropriate treatment are vital for the patient survival and comfort (Merrill *et al.* 1991; Ratanatharathorn *et al.* 1991). Ophthalmological examination of patients after surgical treatment of breast cancer should be a mandatory part of routine inspections.

REFERENCES

- 1 Amichetti M, Caffo O, Minatel E *et al.* (2000). Ocular metastases from breast carcinoma: A multicentric retrospective study. *Oncol Rep.* **7**(4): 761–5.
- 2 Bloch RS, Gartner S (1971). The incidence of ocular metastatic carcinoma. *Arch Ophthalmol.* **85**(6): 673–5.
- 3 Coleman DJ, Abramson DH, Jack RL, Franzen LA (1974). Ultrasound diagnosis of tumors of the choroid. *Arch Ophthalmol.* **91**: 344–54.
- 4 Demitrici H, Shields CL, Chao A, Shields JA (2003). Uveal metastasis from breast cancer in 264 patient. *Am J Ophthalmol.* **136**: 264–71.
- 5 Merrill CF, Kaufman DI, Dimitrov NV (1991). Breast cancer metastatic to the eye is a common entity. *Cancer* **68**: 623–7.
- 6 Papageorgiou KI, Sinha A, Ioannidis AS, Davidson NG (2009). Ocular metastases from HER2 positive breast carcinoma and the response to combination therapy with Paclitaxel and Trastuzumab: a case report. *Cases Journal* **2**: 9143.
- 7 Ratanatharathorn V, Powers WE, Grimm J, Steverson N *et al.* (1991). Eye metastasis from carcinoma of the breast: Diagnosis, radiation treatment and results. *Cancer Treatment Rev.* **18**: 261–76.
- 8 Shields CL, Shields JA, Gross NE, Schwartz GP, Lally SE (1997). Survey of 520 eyes with uveal metastases. *Ophthalmology* **104**: 1265–6.
- 9 Silvestris N, Di Cosimo S, Ferretti G, Angelini F *et al.* (2003). Breast cancer metastatic to the choroid in a male patient: case report. *Tumori.* **89**(3): 333–5.
- 10 Wiegel T, Kreusel KM, Bornfeld N, Bottke D *et al.* (1998). Frequency of asymptomatic choroidal metastasis in patient with disseminated breast cancer: results of a prospective screening programme. *Br J Ophthalmol* **82**: 1159–1161.