

# Idiopathic intracranial hypertension: a unifying neuroendocrine hypothesis through the adrenal-brain axis

Vincenzo SALPIETRO<sup>1</sup>, Agata POLIZZI<sup>2</sup>, Luca Francesco BERTÈ<sup>1</sup>, Roberto CHIMENZ<sup>1</sup>, Valeria CHIRICO<sup>1</sup>, Sara MANTI<sup>1</sup>, Valeria FERRAÙ<sup>1</sup>, Annamaria SALPIETRO<sup>1</sup>, Teresa ARRIGO<sup>1</sup>, Martino RUGGIERI<sup>3</sup>

<sup>1</sup> Department of Pediatrics, University of Messina, Italy

<sup>2</sup> National Centre for Rare Diseases, Superior Institute of Health, Rome, Italy

<sup>3</sup> Department of Educational Processes, University of Catania, Italy

Correspondence to: Vincenzo Salpietro, MD.  
Department of Pediatrics, University of Messina  
Via Consolare Valeria, 1 98125 – Messina, Italy.  
TEL: +39 0902213115; FAX: +39 090 2217029; E-MAIL: salpietroenzo@yahoo.it

Submitted: 2012-10-11 Accepted: 2012-10-25 Published online: 2012-11-15

Key words: **idiopathic intracranial hypertension; neuroendocrinology; renin-aldosterone system; obesity; growth hormone; vitamin A; progesterone; pregnancy; corticosteroids; pseudotumor cerebri**

Neuroendocrinol Lett 2012; **33**(6):569–573 PMID: 23160227 NEL330612C06 © 2012 Neuroendocrinology Letters • [www.nel.edu](http://www.nel.edu)

## Abstract

The clinical syndrome idiopathic intracranial hypertension (IIH), also termed pseudotumor cerebri, consists of symptoms of headache, nausea, vomiting and visual field defects in combination with findings of papilledema.

IIH is more commonly seen in overweight women where the rise in intracranial pressure is putatively a consequence of an endocrine-based disturbance of electrolytes. Less frequently, it can also occur in men and in the pediatric age group. Associated risk factors include primary and secondary aldosteronism, pregnancy, recombinant growth hormone (r-GH) therapy, oral contraceptives, obesity, vitamin A intoxication or deficiency, Addison disease, corticosteroid therapy or acute withdrawal of steroid therapy and Cushing disease. Herein, we review the association between these conditions and IIH working toward its having a unifying neuroendocrine hypothesis.

## INTRODUCTION

Idiopathic intracranial hypertension (IIH; also known as pseudotumor cerebri) is a neurological disorder of uncertain etiology, characterized by increased intracranial pressure in the absence of a tumor, hydrocephalus and no apparent cause evident on neuroimaging or other routine evaluation. Its main symptoms and signs are headache, nausea and vomiting, as well as visual field defects and papilledema. Its pathophysiologic origins remain uncertain. Several decades ago, it was

suggested IIH is a consequence of an underlying endocrine abnormality related to a disturbance of electrolytes. In 1955, Foley suggested that: "... an underlying endocrine imbalance, with presumably a disturbance of electrolytes, is in some way connected with the alteration of intracranial pressure" (Foley 1955). The occurrence of a "... water-electrolyte imbalance, brought about by hormonal disturbance" was likewise suggested by Oldston (Oldston 1966). In this context, Weber *et al.* in 2002 were the first to draw attention to the association between IIH and primary aldoste-

ronism (PAL) in 2 overweight, middle-aged women (Weber *et al.* 2002). Since then additional cases associated with PAL have been reported.<sup>4</sup> IIH has also been reported in children and adolescents with secondary aldosteronism (SAL) including an Italian girl that we recently reported (Salpietro *et al.* 2012). The English literature thus currently consists of 12 reported cases of IIH with either PAL or SAL (Khan *et al.* 2012). The PAL group were mostly hypertensive middle-aged women with adrenal pathology, whereas the SAL patients were mostly normotensive girls affected by inherited renotubular defect. Five out of the 12 patients reviewed by Khan *et al.* (2012) were treated with spironolactone with good control of symptoms. In two of these five, an additional therapy was correction of hypokalemia and hypomagnesaemia. Conclusions of that study inferred that IIH patients should be evaluated for aldosteronism and considered for spironolactone therapy.

## ALDOSTERONISM

Aldosterone is a mineralocorticoid which promotes Na<sup>+</sup> resorption at the expense of a well-recognized K<sup>+</sup> excretion and a less-recognized mechanism of Mg<sup>2+</sup> and Ca<sup>2+</sup> excretion in classic target tissues (e.g., kidneys, colon, and sweat and salivary glands) but also newly discovered sites including epithelial cells of the choroid plexus and inner ear (Lecain *et al.* 2003; Akiyama *et al.* 2010). The biological action of aldosterone on the epithelial cells of the choroid plexus are similar to the classical mechanisms involved in the epithelial cells of the kidney with enhancement of the number and activity of the Na<sup>+</sup>/K<sup>+</sup> ATPase pumps in the apical membranes (Weber 2003, Wright 1978). Cerebrospinal fluid (CSF) production by the choroid plexus is governed by the systemic volume control (Go 1997), which is tightly regulated by the action of aldosterone acting on its specific receptors (Figure 1). In this respect, aldosterone alters the composition of CSF, which in turn contributes to the regulation of blood (CSF) pressure (Weber 2003). Whether CSF formation is increased in aldosteronism accounting either for increased intracranial pressure and for headache, shared symptoms in aldosteronism and IIH, remains unknown. In addition to aldosterone, other risk factors associated with IIH include pregnancy, corticosteroid therapy, Cushing disease, r-Gh therapy, obesity and vitamin A intoxication, which act to enhance the renin-aldosterone axis thus disturbing the electrolyte balance and/or by influencing mineralocorticoid receptors in the epithelial cells of the choroid plexus.

## PREGNANCY

In normal pregnancy plasma aldosterone concentrations increase in parallel to progesterone (Escher 2009) playing a key role in the maintenance of volume expansion

(especially during the first trimester) by contributing to water and sodium retention. Progesterone has an additional effect secondary to its *in vitro* demonstrated high affinity for mineralocorticoids and its *in vivo* demonstrated low agonistic mineralocorticoid activities (Myles & Funder 1996). It is well known that IIH can be precipitated by normal pregnancy and that there is a tendency for preexisting IIH to worsen during pregnancy, possibly due these hormonal change (Shehata & Okosun 2004). It is conceivable that the activation of the renin-aldosterone axis may have a pathogenetic role in pregnant women who develop IIH in association to their weight gain. The affinity of progesterone to mineralocorticoid receptor in the choroid plexus could explain why almost all patients with IIH are overweight women, when applied strict diagnostic criteria. It is also conceivable that the modulation of MR by progesterone is cumulative to the action of other hormones for which it is sensitive.

## CORTICOSTEROID AXIS

Chronic steroid administration, Cushing disease and acute withdrawal of chronic steroid use are among the other largely reported risk factors for IIH. There is a putative mechanism for the effects of corticosteroids on CSF production. The enzyme 11 $\beta$ -hydroxysteroid dehydrogenase type 1 (11 $\beta$ -HSD1) is highly expressed in the epithelium of the choroid plexuses: among its main activities is the reduction of inactive cortisone to cortisol. The latter can activate mineralocorticoid receptors with a degree of affinity similar to aldosterone thereby increasing CSF pressure and leading to the development of IIH (Zada *et al.* 2010). Of interest, it has been also proposed that autocrine regulation of intracerebral cortisol is dependent on 11 $\beta$ -HSD1 expression in the epithelial cells of the choroid plexus and that this enzyme may be involved in the CSF production and may influence cortisol levels in the CSF (Sinclair *et al.* 2007). An additional effect of 11 $\beta$ -HSD2 is its dehydrogenase activity, which inactivates corticosterone or cortisol via their conversion to inactive cortisone. This enzyme in the adult brain is thought to protect mineralocorticoid receptors from activation by cortisol and it is also implicated in mediating central control of salt/water balance (Holmes & Seckl 2006) where its expression in the brain could be considered a factor indirectly influencing CSF production and composition.

## RENIN/ALDOSTERONE AXIS AND OBESITY

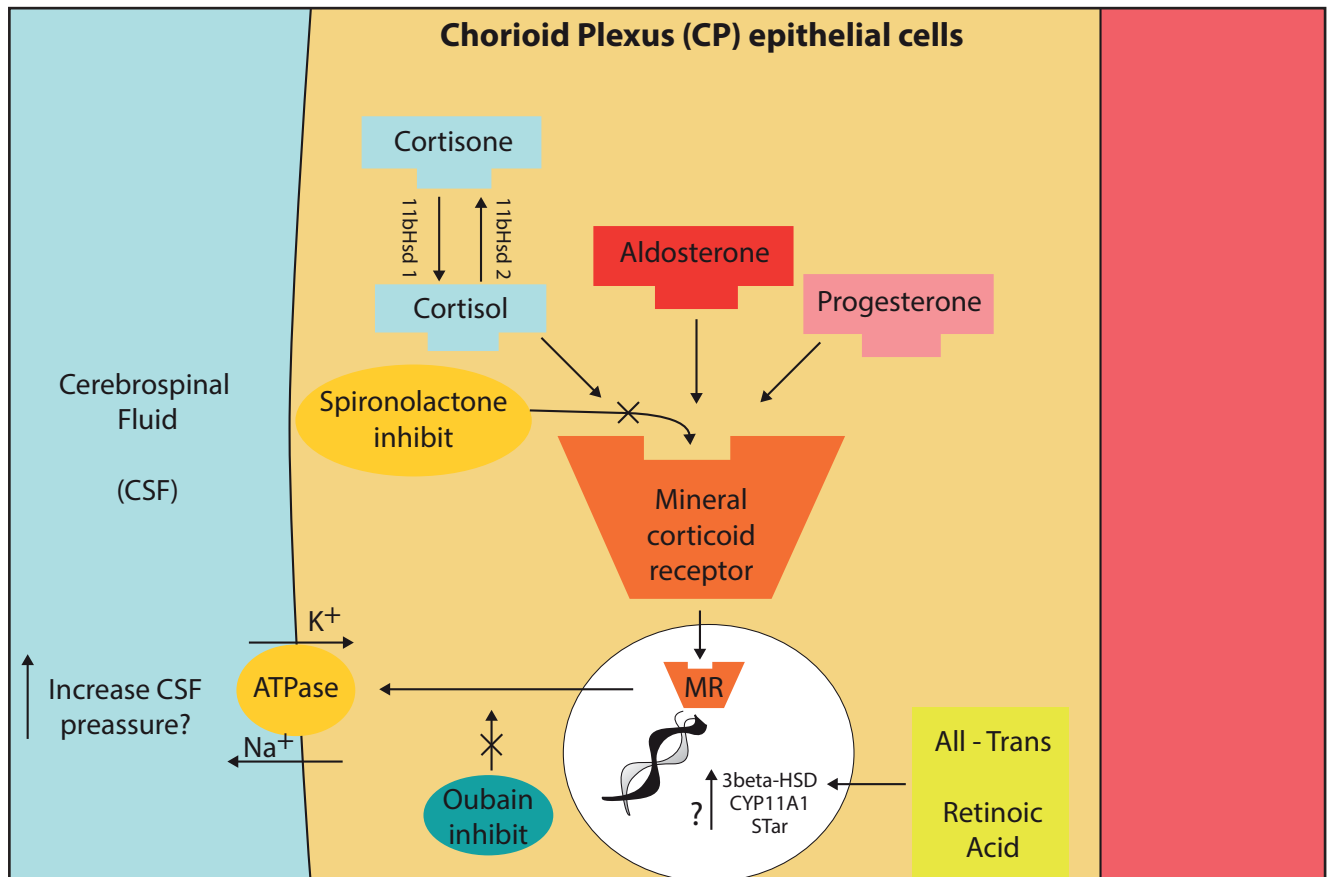
The renin-aldosterone axis is involved and enhanced in obesity. Obesity is frequently associated with increased plasma aldosterone levels. Increased mineralocorticoid activity may be the common link between obesity, hypertension, dyslipidemia and insulin resistance,

features that make up the metabolic syndrome. Recent evidence suggests that human fat is a highly active endocrine tissue and secretory products strongly stimulate steroidogenesis in human adrenocortical cells with a predominant effect on mineralocorticoid secretion (Ehrhart-Bornstein *et al.* 2003). Human adipocytes secrete potent mineralocorticoid-releasing factors, suggesting a direct correlation between obesity and hypertension. Adipocytes release secretagogues that stimulate adrenocortical steroidogenesis with a strong effect on mineralocorticoid secretion. Mineralocorticoid-releasing factors secreted from subcutaneous or from visceral fat into the circulation may reach the adrenal glands via endocrine pathways reaching concentrations capable of stimulating adrenocortical steroidogenesis (Nagase *et al.* 2006). Increased levels of aldosterone may be responsible for hypertension and for cardiovascular complications associated with obesity, including IHH through the activation of mineralocorticoid receptors in the choroid plexuses.

## VITAMIN A INTOXICATION

Recent studies focused on the role of retinoic acid during steroidogenesis and demonstrating that all-trans-retinoic acid (ATRA) activates the expression of neurosteroid biosynthesis genes in the human glial cell line GI-1, expresses the major steroidogenic genes. Treatment with ATRA induces an increase in the expression of the cytochrome P450<sub>scc</sub> (CYP11A1) gene, the steroidogenic acute regulatory protein (StAR) and 3 $\beta$ -hydroxysteroid dehydrogenase (Kushida & Tamura 2009).

In addition, ATRA also induces *de novo* synthesis of neurosteroids, including pregnenolone and progesterone. These results would suggest that ATRA might induce the *de novo* neurosteroid synthesis via the induction of steroidogenic genes in human glial cells. The multiple effects of vitamin A on central nervous system functions might therefore be partly explained by the induction of neurosteroidogenesis by retinoid acids.



**Fig. 1.** The putative effects of neuroendocrine interactions on cerebrospinal fluid secretion in the choroid plexus epithelium.

Detailed figure of CP epithelium illustrating the proposed regulation of CSF secretion by several neuroendocrine interactions.

Aldosterone can stimulate MR; spironolactone can antagonize MR activation. In nucleus MR can activate mineralocorticoid responsive

elements that stimulate synthesis from DNA of Na<sup>+</sup>/K<sup>+</sup> ATPase pumps. Active sodium secretion by the Na<sup>+</sup>/K<sup>+</sup> ATPase at the apical CP membrane lead to movement of sodium ions into the cerebral ventricle and this create an osmotic gradient to drive CSF secretion.

Ouabain can inhibit activation and increased number of Na<sup>+</sup>/K<sup>+</sup> ATPase pumps.

The enzyme 11 $\beta$ HSD1 is highly abundant in the CP, in which its oxidoreductase activity converts inactive cortisone to cortisol, which can activate the MR with similar affinity to aldosterone. Also progesterone can activate MR with a similar affinity to aldosterone and cortisol.

All-Trans retinoic acid, interacting with DNA, can activate neurosteroidogenesis and *de novo* synthesis of steroids, such as pregnenolone and progesterone. Abbreviations: CP= choroid plexus; CSF= cerebrospinal fluid; MR= mineralocorticoid receptor

Among the overall complications induced by vitamin A intoxication one could consider the risk of developing acute IIH, which could be related to an upregulation of the secretion of neurosteroids, which in turn would overload the mineralocorticoid receptor in the choroid plexuses.

## GROWTH HORMONE

Growth hormone (GH) has important effects on the renin-angiotensin-aldosterone system. Acute treatment of GH-deficient adults with r-Gh can lead to sodium and water retention with increased plasma renin activity and aldosterone levels (Ho & Weissberger 1990). The complications of these treatment protocols include hypertension, dependent edema and carpal tunnel syndrome. In GH-deficient children treated with r-Gh, hypertension-dependent edema and fluid retention are less frequent. However, some studies recorded transient, mild increases in blood pressure during the first phase of treatment (Barton 1993). Of interest, the activation of the renin/aldosterone axis complicated by sodium and water retention has been recorded in children with idiopathic short stature who had been treated with r-Gh therapy (Hanukoglu *et al.* 2001; Lampit *et al.* 1998). These findings suggest activation of the renin/aldosterone axis in children the exogenous (r-GH) hormone administration must overlap the endogenous (GH) hormone production. Recent studies have shown also that chronic GH excess is associated with increased aldosterone in humans and mice and that the underlying mechanism is likely to be independent from renin action, IGF-I excess, or adrenal aldosterone synthase expression (Bielohuby *et al.* 2009).

## A UNIFYING NEUROENDOCRINE HYPOTHESIS

The literature of reported cases of IIH points to various risk factors, together with yet unknown individual predisposition, as a cause of this neuroendocrine syndrome.

The IIH has also been associated to conditions such as withdrawal of chronic steroid therapy (Liu *et al.* 1994), hypoadrenalism (Alexandrakis 1993) and vitamin A deficiency (Panozzo *et al.* 1998); there are many reports that correlate these factors to an acute or chronic onset of IIH. These conditions may reduce the activation of the MR in the epithelial cells of the choroid plexus, leading to reduced movement of sodium ions into the cerebral ventricle and a negative osmotic gradient to drive CSF secretion, resulting in a possible reduction of CSF volume and pressure.

Applying the Monroe-Kellie doctrine, which dictates that the sum and subtraction of the volumes of intracranial blood, cerebrospinal fluid, and cerebral tissue must remain constant where the skull is intact, a decrease in CSF volume and pressure results in a reduction of CSF

absorption in arachnoid villi and an increase in resistance to cerebrospinal fluid outflow.

There are several evidences in support of this consideration. It has been shown in canine studies that the abrupt cessation of steroids after chronic therapy can cause a substantial reduction in cerebrospinal fluid absorption and a subsequent increase in resistance to cerebrospinal fluid flow (Johnston *et al.* 1975). Thus, abnormalities in cerebrospinal fluid dynamics during the glucocorticoid withdrawal may lead to high intracranial pressure. We can imagine an impaired CSF outflow also in hypoadrenalism, with a similar mechanism. Vitamin A deficiency in experimental animals causes intracranial hypertension associated with a demonstrated increase in CSF outflow resistance (Calhoun *et al.* 1967). Finally, it is conceivable that aldosteronism, r-Gh therapy, Cushing disease, vitamin A intoxication, pregnancy and chronic steroid therapy can lead to IIH through stimulation of MR pathway that lead to active sodium secretion by the Na/K ATPase at the apical membrane of choroid plexus epithelium (Figure 1). On the contrary, vitamin A deficiency, acute withdrawal of steroid therapy and hypoadrenalism could lead to IIH through prolonged reduction of CSF absorption (that exceeds the reduced production), in the presence of not clarified factors of CSF dynamics alteration.

Thus far, however, there is not a credible and comprehensive hypothesis aimed to uncover the pathogenesis and pathophysiology of IIH despite the different mechanisms proposed. Some recent clinical and laboratory evidence have suggested a role for the renin/aldosterone system in symptomatic IIH patients: this was supported by the empirical benefits recorded after spironolactone (an antagonist of central receptors for aldosterone) administration (Khan *et al.* 2012; Salpietro *et al.* 2012). That could be regarded as the first etiological therapy in IIH. In addition there is increasing evidence suggesting other hormones (e.g., corticosteroids, GH), endogenous or exogenous substances (e.g., retinoic acids) and/or enzymes (11 $\beta$ -HSD1) may act on non-classical peripheral targets (i.e., epithelial cells of the choroid plexuses) involved in the production and increase of CSF. In light of these new advances we propose that multiple neuroendocrine interactions could influence the activation of mineralocorticoid receptor in the central nervous system and could play a key role in the onset of IIH. This awareness could provide the guidelines for a greater understanding of the underlying alteration of CSF production and composition (i.e., the main pathogenetic premise for developing IIH) and for non-conventional therapeutic strategies.

## ACKNOWLEDGMENTS

We gratefully acknowledge Prof. Karl T Weber, University of Tennessee Health Science Center and Prof. Michael Wall, University of Iowa, for their precious suggestions and for the critical revision of this manuscript.

**Financial Disclosure**

The authors declare that they have no competing interests

## REFERENCES

- 1 Akiyama K, Miyashita T, Matsubara A, Inamoto R, Mori T, Nishiyama A *et al.* (2010). Expression and localization of 11 $\beta$ -hydroxysteroid dehydrogenase (11 $\beta$ HSD) in the rat endolymphatic sac. *Acta Otolaryngol.* **130**: 228–32.
- 2 Alexandrakis G, Filatov V, Walsh T (1993). Pseudotumor cerebri in a 12-year-old boy with Addison's disease. *Am J Ophthalmol.* **116**: 650–1.
- 3 Barton JS, Hindmarsh PC, Preece MA, Brook CG (1993). Blood pressure and the renin-angiotensin-aldosterone system in children receiving recombinant human growth hormone. *Clin Endocrinol (Oxf).* **38**: 245–51.
- 4 Bielohuby M, Roemmler J, Manolopoulou J, Johnsen I, Sawitzky M, Schopohl J *et al.* (2009). Chronic growth hormone excess is associated with increased aldosterone: a study in patients with acromegaly and in growth hormone transgenic mice. *Exp Biol Med (Maywood).* **234**: 1002–9.
- 5 Calhoun MC, Hurt HD, Eaton HD, *et al.* (1967). Rates of formation and absorption of cerebrospinal fluid in bovine hypovitaminosis A. *Am J Dairy Sci.* **50**: 1486–94.
- 6 Chitalia N, Weeg N, Antonios TF (2010). Aldosterone-producing adrenal adenoma and idiopathic intracranial hypertension--a pathogenetic link for aldosterone? *QJM.* **103**: 699–702.
- 7 Ehrhart-Bornstein M, Lamounier-Zepter V, Schraven A, Langenbach J, Willenberg HS, Barthel A, *et al.* (2003). Human adipocytes secrete mineralocorticoid-releasing factors. *Proc Natl Acad Sci U S A.* **100**: 14211–16.
- 8 Escher G (2009). Hyperaldosteronism in pregnancy. *Ther Adv Cardiovasc Dis.* **3**: 12332.
- 9 Foley J (1955). Benign forms of intracranial hypertension. toxic and otitic hydrocephalus. *Brain.* **78**: 1–41.
- 10 Go KG (1997). The normal and pathological physiology of brain water. *Adv Tech Stand Neurosurg.* **23**: 47–142.
- 11 Hanukoglu A, Belutserkovsky O, Phillip M (2001). Growth hormone activates renin-aldosterone system in children with idiopathic short stature and in a pseudohypoaldosteronism patient with a mutation in epithelial sodium channel alpha subunit. *J Steroid Biochem Mol Biol.* **77**: 49–57.
- 12 Ho KY, Weissberger AJ (1990). The antinatriuretic action of biosynthetic human growth hormone in man involves activation of the renin-angiotensin system. *Metabolism.* **39**: 133–7.
- 13 Holmes MC, Seckl JR (2006). The role of 11beta-hydroxysteroid dehydrogenases in the brain. *Mol Cell Endocrinol.* **248**: 9–14.
- 14 Johnston I, Gilday DL, Hendrick EB (1975). Experimental effects of steroids and steroid withdrawal on cerebrospinal fluid absorption. *J Neurosurg.* **42**: 690–695
- 15 Khan MU, Khalid H, Salpietro V, Weber KT. Idiopathic Intracranial Hypertension Associated with Either Primary Or Secondary Aldosteronism. *Am J Med Sci* (2012), in press
- 16 Kushida A, Tamura H (2009). Retinoic acids induce neurosteroid biosynthesis in human glial GI-1 cells via the induction of steroidogenic genes. *J Biochem.* **146**: 917–23.
- 17 Lampit M, Nave T, Hochberg Z (1998). Water and sodium retention during short-term administration of growth hormone to short normal children. *Horm Res.* **50**: 83–8.
- 18 Lecain E, Yang TH, Tran Ba Huy P (2003). Steroidogenic enzyme expression in the rat cochlea. *Acta Otolaryngol.* **123**: 187–91.
- 19 Liu GT, Kay MD, Bienfang DC, Schatz NJ (1994). Pseudotumor cerebri associated with corticosteroid withdrawal in inflammatory bowel disease. *Am J Ophthalmol.* **117**: 352–7.
- 20 Myles K, Funder JW (1996). Progesterone binding to mineralocorticoid receptors: in vitro and in vivo studies. *Am J Physiol.* **270**: E601–7.
- 21 Nagase M, Yoshida S, Shibata S, Nagase T, Gotoda T, Ando K *et al.* (2006). Enhanced aldosterone signaling in the early nephropathy of rats with metabolic syndrome: possible contribution of fat-derived factors. *J Am Soc Nephrol.* **17**: 3438–46.
- 22 Oldstone MB (1966). Disturbance of pituitary-adrenal interrelationships in benign intracranial hypertension (pseudotumor cerebri). *J Clin Endocrinol Metab.* **26**: 1366–9.
- 23 Panozzo G, Babighian S, Bonora A (1998). Association of xerophthalmia, flecked retina, and pseudotumor cerebri caused by hypovitaminosis A. *Am J Ophthalmol. May.* **125**(5): 708–10.
- 24 Salpietro V, Ruggieri M, Sancetta F, Colavita L, D'Angelo G, Chimenz R, Fede C (2012). New insights on the relationship between pseudotumor cerebri and secondary hyperaldosteronism in children. *J Hypertens.* **30**: 629–30.
- 25 Shehata HA, Okosun H (2004). Neurological disorders in pregnancy. *Curr Opin Obstet Gynecol.* **16**: 117–22.
- 26 Sinclair AJ, Onyimba CU, Khosla P, Vijapurapu N, Tomlinson JW, Burdon MA *et al.* (2007). Corticosteroids, 11 $\beta$ -hydroxysteroid dehydrogenase isozymes and the rabbit choroid plexus. *J Neuroendocrinol.* **19**: 614–20.
- 27 Weber KT, Singh KD, Hey JC (2002). Idiopathic intracranial hypertension with primary aldosteronism. Report of 2 cases. *Am J Med Sci.* **324**: 45–50.
- 28 Weber KT (2003). Aldosteronism revisited. Perspectives on less well-recognized actions of aldosterone. *J Lab Clin Med.* **142**: 71–82.
- 29 Wright EM (1978). Transport processes in the formation of the cerebrospinal fluid. *Rev Physiol Biochem Pharmacol.* **83**: 3–34.
- 30 Zada G, Tirosh A, Kaiser UB, Laws ER, Woodmansee WW (2010). Cushing's disease and idiopathic intracranial hypertension: case report and review of underlying pathophysiological mechanisms. *J Clin Endocrinol Metab.* **95**: 4850–4.