

Effect of functional stabilization training on balance and motor patterns in a patient with Charcot-Marie-Tooth disease

Alena KOBESOVA¹, Pavel KOLAR¹, Jindriska MLCKOVA¹, Martin SVEHLIK²,
Craig E. MORRIS³, Clare FRANK⁴, Magdalena LEPSIKOVA¹, Jiri KOZAK¹

¹ Department of Rehabilitation and Sports Medicine, University Hospital Motol, Second Medical Faculty, Charles University, Prague, Czech Republic

² 2nd Orthopedic Clinic, University Hospital Motol, Second Medical Faculty, Charles University, Prague, Czech Republic

³ Department of Clinical Sciences, Cleveland Chiropractic College, Los Angeles, California

⁴ Kaiser Permanente Los Angeles Movement Science Fellowship, U.S.A

Correspondence to: Alena Kobesova, MD., PhD.
Department of Rehabilitation and Sports Medicine,
Second Medical Faculty, Charles University and University Hospital Motol,
V Uvalu 84, Prague 5, 159 00, Czech Republic.
TEL: +420 224 43 9264; FAX: +420 224 439 220; E-MAIL: alenamudr@me.com

Submitted: 2011-11-30 *Accepted:* 2011-12-29 *Published online:* 2012-03-10

Key words: **hereditary motor and sensory neuropathy; Charcot-Marie-Tooth disease; balance; rehabilitation; dynamic neuromuscular stabilization; physical therapy**

Neuroendocrinol Lett 2012; **33**(1):3-10 PMID: 22467104 NEL330112C01 © 2012 Neuroendocrinology Letters • www.nel.edu

Abstract

OBJECTIVES: Balance and motor disturbances are significant symptoms commonly associated with hereditary motor and sensory neuropathy (HMSN), also known as Charcot-Marie-Tooth disease (CMT). Although CMT is a progressive neurological disease, comprehensive physiotherapeutic strategies may improve balance and motor patterns, and, therefore, enhance the quality of life (ADL).

CASE PRESENTATION: A 55-year-old HMSN patient with confirmed CMT X phenotype was evaluated for locomotor stability on a stabilometric platform. Stability tests were repeated after a 3-week, intensive in-patient rehabilitation program and the results were compared.

CONCLUSIONS: Improvements in “modified clinical testing of sensory interaction on balance”, “limits of stability” and “forward lunge” tests were observed. Subjectively, the patient noted a significant improvement in both balance and gait.

Abbreviations:

ADL	- activities of daily living	EC	- eyes closed
AFO	- ankle-foot orthoses	EMG	- electromyography
CMT	- Charcot-Marie-Tooth disease	EO	- eyes open
CMT X	- chromosome X-linked Charcot-Marie-Tooth disease	FL	- forward lunge
CNS	- central nervous system	HMSN	- hereditary motor and sensory neuropathy
COG	- center of gravity	LOS	- limits of stability
DNA	- deoxyribonucleic acid	mCTSIB	- modified clinical test of sensory interaction on balance
DNS	- dynamic neuromuscular stabilization		

INTRODUCTION

The most commonly occurring form of inherited polyneuropathy is hereditary motor and sensory neuropathy (HMSN), which has a reported incidence rate of 1:2,500 (Dyck & Thomas 2005). HMSN is also known as Charcot-Marie-Tooth (CMT) disease, so named after the investigators who first described the disorder (Smith 2001).

A progressive neurological disorder, CMT has been historically subcategorized in a variety of ways. Recent scientific advances in the understanding of the human genome have allowed more specific distinction by genotype, which has led to new insights (Reilly *et al.* 2010) correlating genotypes with spinal deformities such as scoliosis and hyperkyphosis (Horacek *et al.* 2007). Both CMT types (i.e. I and II) are genetically heterogeneous, resulting from various genetic defects (genotypes), each presenting with a specific clinical picture or phenotype (Pareyson & Marchesi 2009; Reilly *et al.* 2010; Shy *et al.* 2002).

CMTX is the second most common phenotype resulting from a mutation of the gene for connexin 32 (Reilly *et al.* 2011). It is an X-linked demyelinating neuropathy accounting for approximately 10% to 20% of all hereditary demyelinating neuropathies (Hanemann *et al.* 2003; Pareyson 2003). As with all X-linked traits, males are far more commonly affected than females (Dubourg *et al.* 2001; Reilly *et al.* 2011). Mild subclinical central nervous system (CNS) involvement has been described in CMTX patients with transient white matter lesions (Hanemann *et al.* 2003; Mazzeo *et al.* 2008; Reilly *et al.* 2011). Clinically, CMT patients often present initially with bilateral distal muscle weakness of the lower extremities, progressing to involvement of the distal musculature of the upper extremities. Deformity of the feet and sensory deficits of the lower extremities are also typical, with associated abnormalities in gait (Pareyson & Marchesi 2009; Shy 2004). Some patients also have spinal deformities (Horacek *et al.* 2007; Karol & Elerson 2007).

Current available treatment options for CMT primarily address the symptomatic aspects of this disorder (Pareyson 2003; Pareyson *et al.* 2006; Reilly *et al.* 2010). Patients commonly seek orthopedic and prosthetic management for pedal deformity and rehabilitation to address muscle weakness, loss of balance and pain that typically affects the legs but may also include the entire locomotor system. However, little has been documented regarding these clinical strategies to date.

The following case study demonstrates a combination of novel therapeutic strategies designed to improve a CMT patient's clinical presentation.

CASE PRESENTATION

A 55-year-old male patient with the CMTX form of HMSN was admitted to the Rehabilitation Clinic, University Hospital Motol, 2nd Medical Faculty, Charles

University, Prague, Czech Republic. His primary complaints were (1) disturbed balance with standing and walking, especially on uneven surfaces or in the dark, (2) inability to run, (3) coldness and numbness in both feet, (4) painful plantar sores, (5) low back pain, (6) weakness of the hands, (7) disturbed fine motor activity, and (7) requiring assistance during stair climbing.

Past medical history

The patient's initial signs of CMT disease appeared at age 10 with the onset of significant distal leg symptoms i.e., tripping, fatigue when walking longer distances or running, and an inability to keep up with his schoolmates. The patient demonstrated a gradual progression of the lower extremity impairment, especially lower leg muscle atrophy and bilateral pedal deformity. He was diagnosed with CMT at the age of 13: Electromyography (EMG) confirmed a demyelinating form of inherited neuropathy, previously defined as Type 1. The first upper extremity signs appeared at the age of 25 with carpal muscle wasting, weakness, and disturbed fine motor activity. The CMTX form was established at the age of 48 following DNA analysis that confirmed mutation at connexin 32.

Prior Therapy

The patient previously received multiple treatment series of both in-patient and out-patient physical therapy resulting in temporary reductions in back and bilateral leg pain. However, he denied any observable improvements in balance with these prior rehabilitation programs. Previous physiotherapeutic interventions consisted of bilateral tarsal joint mobilization and sensory-motor training according to Janda: balance exercise on unstable surfaces (Janda *et al.* 2006; Page *et al.* 2010). In addition, the physiotherapist performed mobilization and manipulation of blocked spinal segments and stretching techniques for tight muscles.

Objective examination findings on the day of admission:

Upper extremities: The patient demonstrated bilateral, generalized muscle wasting and weakness below the elbows, weakened grasp, inability to perform a "pinch" maneuver and fine hand motor skills. C5-8 reflexes were absent bilaterally.

Spine: No apparent deviation in the frontal plane; hyperkyphosis in the thoracic spine, forward drawn position of the head, hypertonus of the paravertebral muscles at the level of cervicothoracic and thoracolumbar junctions, abnormal respiratory stereotype with overloading of accessory respiratory muscles, weak abdominal wall musculature, and anterior pelvic tilt.

Lower extremities: Bilaterally high-arch foot with collapse of the transverse arches; hammer toes of all toes bilaterally; plantar sores located below the heads of the 1st and 5th metatarsals, proximal to the interphalangeal joints on dorsal aspect of the 5th toes bilaterally, contracture of the plantar aponeuroses and Achilles'

tendons bilaterally, weakness and atrophy of the musculature of the lower legs and feet; L2/4 and L5/S2 areflexia; dystaxia; tactile hypesthesia of the lower legs that was most pronounced in the feet; inability to stand on his heels and tip-toes.

Gait: able to walk independently with a drop-foot gait, covering 10 meters in 7.05 seconds.

CMT Neuropathy scale (Shy *et al.* 2005): 21 out of 30 points. (The greater the point count, the more advanced the stage of neuropathy).

Stability analysis

Computerized Dynamic Posturography was used to analyze the patient's stability in quiet stance. The Balance Master™ Stabilometric Platform utilizes a fixed 18" x 60" dual force plate to measure the vertical ground reaction forces exerted by the patient's feet (NeuroCom International, Inc.). Data collected from the patient's performance for each test were compared to the normative data included in the software. The following tests were performed:

1. Modified Clinical Test of Sensory Interaction on Balance (mCTSIB). This test detects and traces the center of gravity (COG) and calculates the mean COG sway velocity under four conditions, i.e. eyes open on firm surface (Firm-EO), eyes closed on firm surface (Firm-EC), eyes open on unstable surface (Foam-EO), and eyes closed on unstable surface (Foam-EC). The patient initially demonstrated abnormal mean COG sway velocity under all four measured conditions (Figure 1A).
2. The Limits of Stability (LOS) quantifies the maximum distance a person can intentionally displace their COG before balance is lost. Directional control is defined as a comparison of the amount of movement in the intended direction (towards the target) to the amount of extraneous movement (away from the target). The key abnormalities that this patient initially presented were markedly short excursion in the forward and backward directions and abnormal directional control in backward and left direction (Figure 2A).
3. Forward Lunge (FL) quantifies movement characteristics as the patient lunges or steps forward onto one leg, and then pushes back with that same leg to return to a standing position. Prior to our rehabilitation program, the patient demonstrated prolonged contact times when lunging with both left and right leg. Force impulse is defined as the total work performed by the lunging leg during the landing and thrust phases of the movement. The force impulse demonstrated by this patient was initially increased on the right leg and reached the borderline of an increase for the left lunging leg (Figure 3A).

Stabilometric measures were repeated three times to allow for statistical analysis. The Student t-test

(STATISTICA 6.0 software, StatSoft, Tulsa, USA) was applied to demonstrate the differences in between the measurements. *p*-value <0.05 was considered to be statistically significant.

Intervention

The patient underwent a 3-week individualized rehabilitation program at in-patient rehabilitation department, individually performed by a physiotherapist trained in manual therapeutic methods according to Lewit (2010), Dynamic Neuromuscular Stabilization according to Kolar (Kolář 2006; Kolar & Kobesova 2010) sensorimotor training according to Janda (Janda *et al.* 2006; Page *et al.* 2010). These are therapeutic procedures commonly utilized in the Czech Republic for CMT, so they formed the clinical basis for this case study. The therapeutic protocols consisted of individual and group sessions that consisted of the following procedures:

1. Individualized and specific exercises with a physiotherapist based on findings from a detailed musculoskeletal movement examination, provided 30 minutes twice per day; mobilization of the peripheral joints and soft tissue manipulation primarily directed toward the plantar aponeuroses, digital extensors and Achilles' tendons (Lewit 2010), sensorimotor balance training (Janda *et al.* 2006; Page *et al.* 2010), and activation of the integrated stabilizing system of the spine utilizing Dynamic Neuromuscular Stabilization protocols (Kolar 2006; Kolar & Kobesova 2010). Readers are directed to the works of Lewit (2010), Janda (Janda *et al.* 2006; Page *et al.* 2010) and Kolar (Kolar 2006; Kolar & Kobesova 2010) for details of the techniques utilized.
2. Group exercise 30 min once daily: combination of Tai-Chi and exercise on gym balls.
3. Hydrotherapy: 30 min once a day: exercise in the pool under supervision of the physiotherapist.
4. Occupational therapy: 30 min once a day focused on improvement of fine motor activity of the hands and specific functional exercises designed to assist in the performance of activities of daily living.

RESULTS

The patient was re-evaluated prior to discharge (the last, i.e. 21st day of hospitalization). Stabilometric assessments were also repeated and results compared with those obtained on the first day.

Stability analysis

1. mCTSIB (Figure 1B): Following rehabilitation, the values of COG sway velocity under all four measured conditions improved significantly. The patient's stance on the unstable surface (foam) with his eyes closed particularly improved. In this test, the mean COG sway velocity was 3.0 deg/sec on the

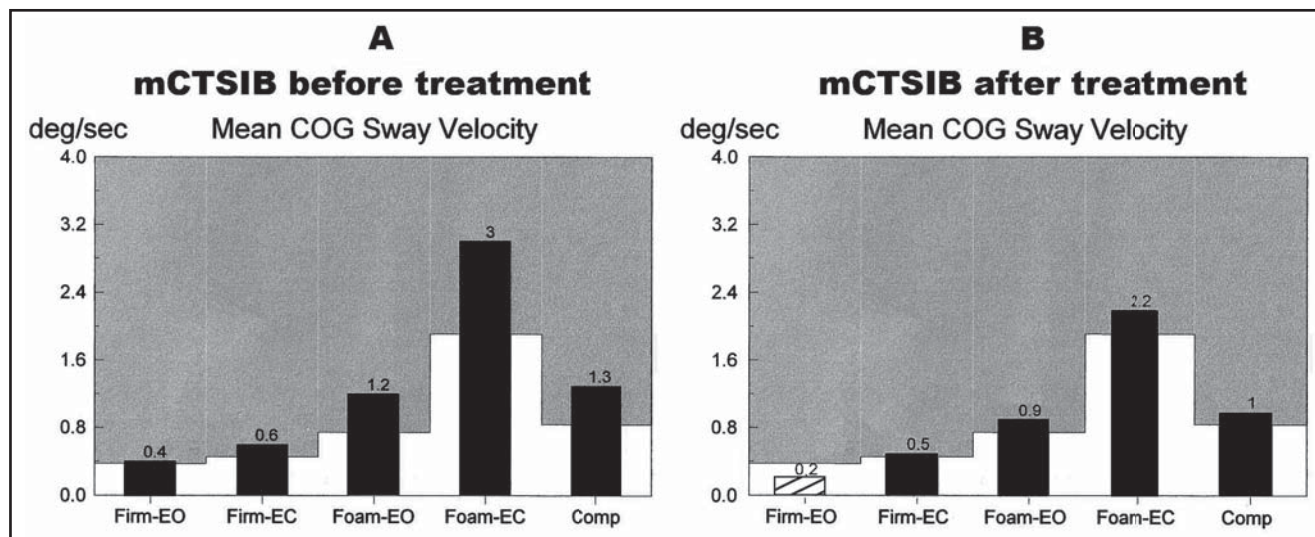


Fig. 1. Modified clinical test of sensory interaction on balance. The white area of the stabilometric graphs refers to normal values, while the grey is abnormal. The striped slope indicates that patient's values fall within the normal values, while the black slopes mean that the patient's values fall outside the normal and are considered abnormal. Following rehabilitation, improved (decreased) values of COG sway velocity under all four measured conditions were observed. However, only stance on firm surface with eyes open reached normative values. COG: center of gravity; Firm EO: Eyes open firm surface; Firm EC: Eyes closed firm surface; Foam EO: Eyes open unstable surface (foam); Foam EC: Eyes closed unstable surface (foam); Comp: the mean sway velocity averaged over the twelve trials

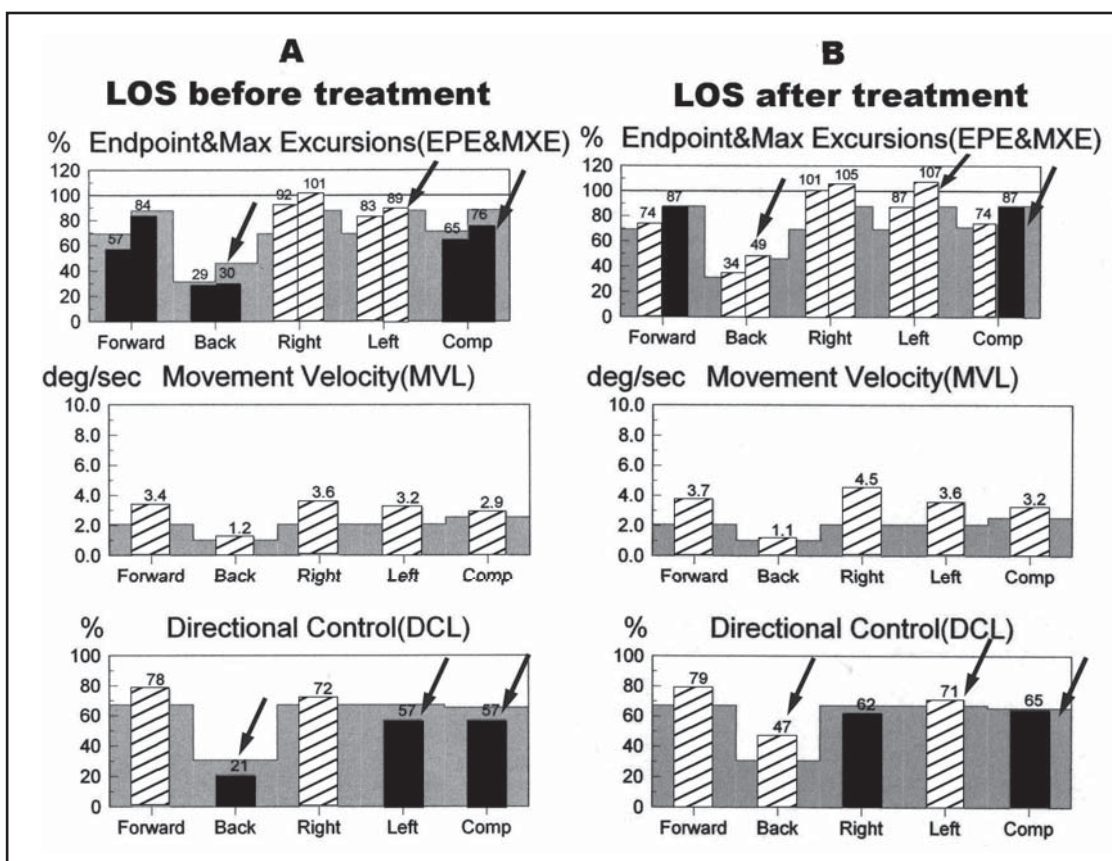


Fig. 2. Limits of stability. The white area of the stabilometric graphs refers to normal values, while the grey is abnormal. The striped slope indicates that patient's values fall within the normal values, while the black slopes mean that the patient's values fall outside the normal and are considered abnormal. After rehabilitation: increased (improved) limits of stability in backward and left motion (see arrows, compare the left and right side of the table) were noted as well as composite MXE. Composite directional control also improved after rehabilitation (57% before and 65% after rehabilitation) with maximum changes in back and left directions. Directional control however declined in right direction (72% before and 62% after rehabilitation). EPE: Endpoint Excursion is the distance of the first movement toward the designated target. MXE: Maximum Excursion is the maximum distance achieved during the trial.

initial day, and improved to 2.2 deg/sec post rehabilitation program ($p=0.021$). A composite sway also improved (1.3 deg/sec pre rehabilitation versus 1.0 deg/sec after rehabilitation, $p=0.015$) reaching the borderline normal values.

2. LOS (Figure 2B): After rehabilitation, limits of stability were improved significantly in backward and left directions. Maximum backward excursion was 30% pre- and 49% post-rehabilitation ($p=0.009$), maximum left excursion was 89% pre- and 107% post-rehabilitation ($p=0.017$). Composite maximum excursion also improved significantly; it was 76% pre- versus 87% post-rehabilitation ($p=0.025$). Improvement was also observed in composite directional control (57% pre and 65% post-rehabilitation,

$p=0.020$) with maximum changes in back (21% versus 47%, $p=0.004$) and left directions (57% versus 71%, $p=0.017$).

3. FL (Figure 3B): All the values measured were within the normative data following rehabilitation. The contact time was improved when lunging on each leg. Left leg contact time pre-rehabilitation was 1.67 seconds versus 0.88 seconds post-rehab ($p=0.001$). Right leg contact time was 1.73 seconds pre-rehabilitation and 1.27 seconds post rehabilitation ($p=0.014$). In addition, each leg lunging force impulse was decreased and stayed within the normative data limits after rehabilitation. On the left side the force impulse decreased from 161% (expressed as percentage of body weight multiplied

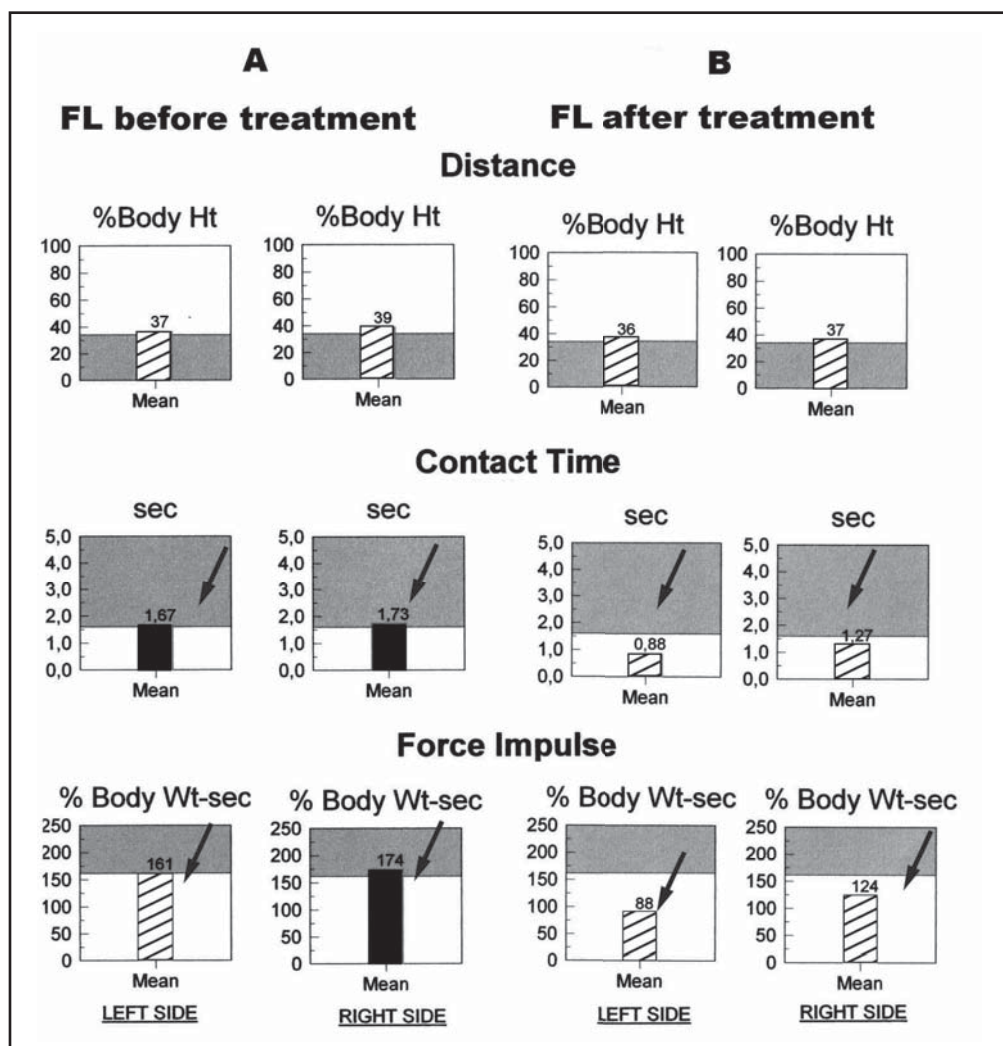


Fig. 3. Forward lunge. The white area of the stabilometric graphs refers to normal values, while the grey is abnormal. The striped slope indicates that patient's values fall within the normal values, while the black slopes mean that the patient's values fall outside the normal and are considered abnormal.

All the values measured within the normative data following rehabilitation. The contact time was decreased (improved) when lunging with each leg (arrows). Both leg lunging force impulse decreased and was within the normative data limits after rehabilitation (arrows in the bottom graphs). However the distance did not increase when lunging by each leg.

%Body Ht: percentage of the individual's height.

%Body Wt-sec: percentage of body weight multiplied by the time the force is exerted in seconds

by the time the force is exerted in seconds) to 88% ($p < 0.001$), while the right side decreased from 174 to 124% ($p = 0.009$). These results indicate that the post-rehabilitation patient performed the forward lunge at greater speed and efficiency.

Most of the stabilometric test values improved post rehabilitation except for a negligible decline in the backward direction movement velocity of LOS (1.2 versus 1.1 deg/sec pre and post rehabilitation respectively, $p = 0.548$) and a more prominent decline in right directional control which was not statistically significant (72% versus 62%, $p = 0.2034$). Finally, the FL distance in both right and left legs slightly decreased. Specifically, the FL distance was 37% pre-rehabilitation (expressed as percentage of the individual's height) versus 36% ($p = 0.746$) on the right leg; left leg was 39% versus 37% post rehabilitation, $p = 0.435$.

DISCUSSION

CMT is currently an incurable progressive neurological disease (Pareyson *et al.* 2006; Reilly *et al.* 2011) and limited literature exists regarding rehabilitation strategies and their effectiveness. Njegovan *et al.* (1997) noted that timely rehabilitation of foot deformities may result in significant functional improvement and delay or prevent the need for future surgery. Surgical procedures are most commonly performed to correct foot deformity or re-balance force loading strategies via tendon transfers and have reported to improve balance or motor control in some studies (Guyton & Mann 2000; Santavirta *et al.* 1993). Bean *et al.* (2001) reported that ankle-foot orthoses (AFO) can enhance physiological performance and perceived exertion at submaximal activity levels in patients with Charcot-Marie-Tooth disease. Vinci (2003) reported improved balance and independent ambulation in severely affected HMSN patients after rehabilitation management consisting of ankle stabilization by drop-foot boots. Chetlin *et al.* (2004) suggested progressive resistance training as an effective way to improve activities of daily living.

To our knowledge, there are only two papers published addressing the effect of dynamic balance training on CMT patients' motor stereotypes. Matjacić & Zupan (2006) evaluated the effect of dynamic balance training on 16 CMT patients. After a 12-day intervention that consisted of passive stretching and dynamic balance training on a commercially available, mechanical balance training apparatus, the patients showed statistically significant improvement in balance. Maggi (Maggi *et al.* 2011) published a pilot study utilizing combined treadmill training, stretching, respiratory, and proprioceptive exercise on eight CMT patients. After 8 weeks of exercise, applied 2 times per week they report significantly faster 6 meters walk and increased ankle dorsiflexion range, however with regards to balance, the results showing an average improvement were

not significant. Schenone *et al.* (2011) state in their rather extensive review paper that there is not enough evidence to recommend muscle stretching exercise and proprioceptive training to improve balance. Burns *et al.* (2009) investigated an effect of 12 week progressive resistance strength training in a 15 years old CMT girl. They report significant increase in dorsiflexion and plantarflexion strength while balance has not improved.

Stabilometric results of our patient showed improvement in most parameters following an intensive and comprehensive 3-week, in-patient rehabilitation. Some of the initially abnormal pre-rehabilitation values achieved fell within normal limits i.e. standing on firm surface with eyes open and composite endpoint excursion in LOS test. All stabilometric test values improved post rehabilitation except for a negligible decline in the backward direction movement velocity of LOS. These data demonstrate consistent measurable functional gains realized through this multi-modal approach to therapy.

At the time of discharge, the patient reported improved balance during stance and gait, reduced plantar pain, complete resolution of his chronic low back pain, giving him a sense of well-being and satisfaction of his time in rehabilitation. It can be argued that the improvement observed in the test parameters may result from a learning process rather than a true improvement of balance itself. However it is questionable whether a 3-week interval may be sufficient for significant adaptive learning to occur.

In a study by Geurts *et al.* (1992), the postural organization in patients with CMT type I or II was studied clinically utilizing a force platform. Balance was registered in 14 barefooted CMT patients and healthy matched control subjects during quiet stance. The effect of visual deprivation was tested to determine the degree of visual dependency. The effect of the simultaneous performance of a concurrent attention-demanding task was tested to estimate the level of balance automaticity. In comparison with control subjects, the CMT patients showed a decreased efficiency of postural control as well as an increased visual control of posture in both directions of sway. However, no loss of balance automaticity was found, which the authors suggested was due to a central adaptation to the slowly developing peripheral impairments. This may hold true for our case patient where the mCTSIB data clearly demonstrate a strong visual dependency for postural control. Backward limits of stability (LOS) were severely disturbed due to total atrophy of peroneal muscles and tibialis anterior. However, LOS in backward direction was improved after the 3-week rehabilitation. In the presence of severely denervated muscles, it is suggested that this improvement may have resulted in reduced back pain, activation of lumbopelvic muscles and improved hip balance strategy through core stability training, due to the DNS protocols. Maggi *et al.* (Maggi *et al.* 2011) also theorized that targeted training helps CMT patients to improve

utilization of compensatory balance and movement strategies of lower limb proximal muscle groups, which may result in increased functional performance.

CONCLUSIONS

Stability analyses were used to analyze the effect of a 3-week intensive in-patient rehabilitation program consisting mainly of balance and core stability training of a 55-year-old male patient suffering from the CMTX. Computerized Dynamic Posturography demonstrated improvement in most parameters.

There is little research published in the management of CMT, and this case is presented to emphasize the importance of this work to this patient population and prompt additional critical research in this field. Although this is the report of only one patient, and a variety of therapeutic approaches utilized to establish an intensive, dynamic stability training program, we feel that this is the beginning point for ongoing research in this area because this is the combination that forms the medical standard of care in the Czech Republic at this point in time. These findings suggest that intensive dynamic stability training may improve functional stability of CMT patients. Future studies can add to this case study by a variety of methods, including utilizing additional measures for functional stability, additional therapeutic methods for comparison, subdivisions of the therapeutic methods utilized here to determine specific efficacy, and greater numbers of patients, with or without controls, to initiate statistical analyses. Additional research of a statistically significant population of CMT patients would help to establish more concrete parameters regarding effective long-term management of this group of patients. This could be of critical importance for CMT patients, considering Maggi's (Maggi et al 2011) study showing regression of strength, balance, gait speed, ankle range of motion, lung function and CMT NS (Shy *et al.* 2005) after 6 months period without rehabilitation. As Maggi concluded, all CMT patients should receive rehabilitation treatment at least twice every year but it still remains questionable what type of rehabilitation treatment alone or in combination is most effective.

ACKNOWLEDGEMENTS

This study was supported by the foundation Movement without Help, Prague, Czech Republic.

REFERENCES

- 1 Bean J, Walsh A, Frontera W (2001). Brace modification improves aerobic performance in Charcot-Marie-Tooth disease: a single-subject design. *Am J Phys Med Rehabil.* **80**: 578–582.
- 2 Burns J, Raymond J, Ouvrier R (2009). Feasibility of foot and ankle strength training in childhood Charcot-Marie-Tooth disease. *Neuromuscul Disord.* **19**: 818–821.
- 3 Chetlin RD, Gutmann L, Tarnopolsky M, Ullrich IH, Yeater RA (2004). Resistance training effectiveness in patients with Charcot-Marie-Tooth disease: recommendations for exercise prescription. *Arch Phys Med Rehabil.* **85**:1217–1223.
- 4 Dubourg O, Tardieu S, Birouk N, Gouider R, Léger JM, Maisonobe T, et al (2001). Clinical, electrophysiological and molecular genetic characteristics of 93 patients with X-linked Charcot-Marie-Tooth disease. *Brain.* **124**: 1958–1967.
- 5 Dyck PJ, Thomas PK (2005). *Peripheral Neuropathy*. 4th ed. Philadelphia: Elsevier Saunders.
- 6 Geurts AC, Mulder TW, Nienhuis B, Mars P, Rijken RA (1992). Postural organization in patients with hereditary motor and sensory neuropathy. *Arch Phys Med Rehabil.* **73**: 569–572.
- 7 Guyton GP, Mann RA (2000). The pathogenesis and surgical management of foot deformity in Charcot-Marie-Tooth disease. *Foot Ankle Clin.* **5**: 317–326.
- 8 Hanemann CO, Bergmann C, Senderek J, Zerres K, Sperfeld AD (2003). Transient, recurrent, white matter lesions in X-linked Charcot-Marie-Tooth disease with novel connexin 32 mutation. *Arch Neurol.* **60**: 605–609.
- 9 Horacek O, Mazanec R, Morris CE, Kobesova A (2007). Spinal deformities in hereditary motor and sensory neuropathy: a retrospective qualitative, quantitative, genotypical, and familial analysis of 175 Ppatients. *Spine.* **32**: 2502–2508.
- 10 Janda V, Vávrová M, Herbenová A, Veverková M (2006). Sensory motor stimulation. In: Liebensohn C, editor. *Rehabilitation of the Spine – A Practitioner's Manual*. 2nd ed. Baltimore: Lippincott Williams & Wilkins. p. 513–530.
- 11 Karol LA, Elerson E (2007). Scoliosis in patients with Charcot-Marie-Tooth disease. *J Bone Joint Surg Am.* **89**: 1504–10.
- 12 Kolář P (2006). Facilitation of Agonist-Antagonist Co-activation by Reflex Stimulation Methods Liebensohn C, editor. *Rehabilitation of the Spine – A Practitioner's Manual*. 2nd ed. Baltimore: Lippincott Williams & Wilkins. p. 531–565.
- 13 Kolar P, Kobesova A (2010). Postural – locomotion function in the diagnosis and treatment of movement disorders. *Clinical Chiropractic.* **13**: 58–68.
- 14 Lewit K (2010). *Manipulative Therapy*. 1st ed. Edinburgh: Churchill Livingstone Elsevier.
- 15 Maggi G, Monti Bragadin M, Padua L, Fiorina E, Bellone E, Grandis M, et al (2011). Outcome measures and rehabilitation treatment in patients affected by Charcot-Marie-Tooth neuropathy: a pilot study. *Am J Phys Med Rehabil.* **90**: 628–37.
- 16 Matjacić Z, Zupan A (2006). Effects of dynamic balance training during standing and stepping in patients with hereditary sensory motor neuropathy. *Disabil Rehabil.* **28**: 1455–1459.
- 17 Mazzeo A, Di Leo R, Toscano A, Muglia M, Patitucci A, Messina C, et al (2008). Charcot-Marie-Tooth type X: unusual phenotype of a novel CX32 mutation. *Eur J Neurol.* **15**: 1140–1142.
- 18 NeuroCom International, Inc. Neurocom's Balance Manager Systems/Products. Available at: <http://www.onbalance.com/neurocom/products/BalanceMaster.aspx>.
- 19 Njegovan ME, Leonard EI, Joseph FB (1997). Rehabilitation medicine approach to Charcot-Marie-Tooth disease. *Clin Podiatr Med Surg.* **14**: 99–116.
- 20 Page P, Frank CC, Lardner R (2010). *Assessment and Treatment of Muscle Imbalance. The Janda Approach*. 1st ed. Champaign (IL): Human Kinetics.
- 21 Pareyson D (2003). Diagnosis of hereditary neuropathies in adult patients. *J Neurol.* **250**: 148–160.
- 22 Pareyson D, Schenone A, Fabrizi GM, Santoro L, Padua L, Quattrone A, et al. (2006). A multicenter, randomized, double-blind, placebo-controlled trial of long-term ascorbic acid treatment in Charcot-Marie-Tooth disease type 1A (CMT-TRIAL): the study protocol. *Pharmacol Res.* **54**: 436–441.
- 23 Pareyson D, Marchesi C (2009). Diagnosis, natural history, and management of Charcot-Marie-Tooth disease. *Lancet Neurol.* **8**: 654–67.
- 24 Reilly MM, Shy ME, Muntoni F, Pareyson D (2010). 168th ENMC International Workshop: outcome measures and clinical trials in Charcot-Marie-Tooth disease (CMT). *Neuromuscul Disord.* **20**: 839–846.

- 25 Reilly MM, Murphy SM, Laurá M (2011). Charcot-Marie-Tooth disease. *J Peripher Nerv Syst.* **16**: 1–14.
- 26 Santavirta S, Turunen V, Ylinen P, Konttinen YT, Tallroth K (1993). Foot and ankle fusions in Charcot-Marie-Tooth disease. *Arch Orthop Trauma Surg.* **112**: 175–179.
- 27 Schenone A, Nobbio L, Monti Bragardin M, Ursino G, Grandis M (2011). Inherited neuropathies. *Curr Treat Options Neurol.* **13**: 160–179.
- 28 Shy ME, Garbern JY, Kamholz J (2002). Hereditary motor and sensory neuropathies: a biological perspective. *Lancet Neurol.* **1**: 110–118.
- 29 Shy ME (2004). Charcot-Marie-Tooth disease: an update. *Curr Opin Neurol.* **17**: 579–585.
- 30 Shy ME, Blake J, Krajewski K, Fuerst DR, Laura M, Hahn AF, *et al.* (2005). Reliability and validity of the CMT neuropathy score as a measure of disability. *Neurology* **64**: 1209–1214.
- 31 Smith AG (2001). Charcot-Marie-tooth disease. *Arch Neurol.* **58**: 1014–1016.
- 32 Vinci P (2003). Gait rehabilitation in a patient affected with Charcot-Marie-Tooth disease associated with pyramidal and cerebellar features and blindness. *Arch Phys Med Rehabil.* **84**: 762–765.