

Evaluation of temporal bone computed tomography and paranasal sinuses magnetic resonance images in acromegalic patients

Tomasz ZATOŃSKI¹, Marek BOLANOWSKI², Aleksandra SKRZYPEK¹,
Monika MORAWSKA-KOCHMAN¹, Marcin KAŁUŻNY², Katarzyna ZATOŃSKA³,
Krzysztof MOROŃ⁴, Roman BADOWSKI⁴, Tomasz KRĘCICKI¹

¹ Department of Otolaryngology, Head & Neck Surgery, Medical University in Wrocław, Poland

² Department of Endocrinology, Diabetology and Isotope Therapy, Medical University in Wrocław, Poland

³ Department of Social Medicine, Medical University in Wrocław, Poland

⁴ Department of Radiology, Medical University in Wrocław, Poland

Correspondence to: Tomasz Zatoński, MD.
Dept. of Otolaryngology, Head and Neck Surgery, Wrocław Medical University
Borowska 213, 50-556 Wrocław, Poland.
TEL: +48 605 41 49 63; E-MAIL: zatoński@orl.am.wroc.pl

Submitted: 2010-11-03 Accepted: 2010-11-25 Published online: 2011-01-09

Key words: **acromegaly; CT; MR; temporal bone; paranasal sinuses**

Neuroendocrinol Lett 2010;31(6):796-800 PMID: 21206436 NEL310610A24 © 2010 Neuroendocrinology Letters • www.nel.edu

Abstract

OBJECTIVE: Acromegaly is a rare disease, which symptoms are caused by excess secretion of a growth hormone (GH) from the anterior pituitary benign tumor – adenoma. Authors present an evaluation of computed tomography (CT) and magnetic resonance (MR) images of temporal bone and paranasal sinuses of patients with acromegaly.

CONCLUSIONS: 1. In all patients with acromegaly, morphological changes in paranasal sinuses were shown. They were mostly pronounced within the maxillary sinuses including the mucosa thickening up to 6 mm and encysted fluid occurrence. 2. CT of temporal bone did not reveal structural changes of internal and median ear. 3. There is a need for further studies on hearing impairment in patients with acromegaly.

INTRODUCTION

Acromegaly is characterized by enhanced skeletal growth and soft-tissue enlargement, usually caused by a pituitary tumor that produces growth hormone (GH) in excess. It is a disease occurring usually after the completion of growth. The stimulatory effect of GH on bone formation and soft tissues influences the function of many organs and systems (Zalesska-Kręcicka *et al.* 2006; Nabarro 2006; Molitch 1992; Rajasoorya *et al.* 1994; Bolanowski *et al.* 2006). There are described changes in peri-nasal sinuses as frontal sinuses magnification, polyps in sinuses and nasal cave. They can

be found in endoscopic examination, computed tomography (CT) or magnetic resonance (MR) imaging or intraoperatively (Zalesska-Kręcicka *et al.* 2006; Wani *et al.* 2001; Cooke & Hadley 1991; Beahm *et al.* 1990; Branstetter & Weissman 2005). Correlation between acromegaly and otosclerosis is possible. There are reports about conductive or mixed hearing lesion in acromegalic patients (Zalesska-Kręcicka *et al.* 2006; Graham & Brackmann 1978; Doig & Gatehouse 1984). In the literature one can find hypothesis, that sensorineural hearing lesion can be caused by bone hypertrophy

and pression on the acoustic nerve (Zaleska-Kręcicka *et al.* 2006; Graham & Brackmann 1978; Doig & Gatehouse 1984).

The aim of the study was to evaluate CT images of the temporal bone and hearing and balance organ, and to evaluate MR ones of paranasal sinuses – their size and changes in mucosa.

MATERIAL AND METHODS

Standard MR of brain (follow-up examination of pituitary gland) widened on paranasal sinuses was carried out in 10 patients suffering from acromegaly: 5 women, 5 men, mean age 49.6 years (range 31–71 years). The shortest duration of disease was 2 years and the longest 32 years, mean value 10.3 years. Examined patients were both: cured, with well controlled level of GH secretion and patients in active stadium of disease. All but one patient were operated using the transsphenoidal approach. Patients generally complained about nasal obturation and headaches.

In 4 subjects, whose audiologic examinations have shown more advanced disorders, CT of temporal bone was carried out. Sphenoid sinus MR was not evaluated because of postoperative changes.

RESULTS

There were no pathologic findings in temporal bone or structures of middle and inner ear in the evaluation of CT imaging (Figures 1 and 2). In MR T2-weighted images of paranasal sinuses changes of mucosa and sinuses size were observed (Figure 3). The most occur-

ring finding was a thickening of the mucosa. Cysts and free fluid were also present. Changes were bilateral, localized in all sinuses in almost all of the patients. The sphenoidal sinus was not evaluated, because of operative approach to pituitary gland tumors through sphenoid sinus. Different postoperative time period and implementation of different fillings in the sphenoid sinus made the evaluation and comparison of changes in sinuses complicated or even impossible (Figure 4). It is worth to noticing that frontal sinus is often magnified to even 105 mm. The results of examinations are shown in Table 1. Proper mucosa thickness was admitted as lower or equal to 1 mm.

Thickening of the sinuses mucosa up to 6 mm was observed in all patients except one in which normal mucosa thickness was found in the frontal sinus. In four patients encysted fluid in maxillary sinuses was present: in three patients unilateral, in one patient bilateral. In one subject encysted fluid was notable in ethmoidal sinuses. Free fluid appeared in maxillary sinus of one patient.

DISCUSSION

There is only few reports of laryngological disorders and dysfunctions in acromegalic patients except for quite numerous publications from anesthesiology and intensive care, concerning changes in upper respiratory tract and connected difficulties with intubation in them (Goldhill *et al.* 1982). In several reports sensorineural, conductive and mixed hearing disorders are described. Some authors indicate possible connection between acromegaly and otosclerosis (Graham & Brackmann

Tab. 1. Findings of sinuses pathologies in MR images.

No	Patient (sex)	Age (years) / duration of disease (years)	Operated	Maximal mucosa thickness (mm)			Frontal sinus diameters (mm)			
				Right maxillary sinus	Left maxillary sinus	Ethmoidal sinuses	Frontal sinuses	Sagittal	Coronal	Transversal
1	AW (m)	31 / 2	yes 2x	2.5	2.5	2.5	2.5	25	58	68
2	HC (f)	55 / 32	yes	3 + encysted fluid 8x14	5	3	<1	15	30	53
3	JK (f)	54 / 2	yes	2.5	3 + encysted fluid 8x10	2.5	3	12	27	40
4	WK (m)	59 / 4	yes	6	3	2.5	2	20	21	87
5	AK (m)	47 / 7	yes	3.5	2.5	2	2	19	35	52
6	MB(f)	62 / 15	yes	3 + encysted fluid 15x25	3 + encysted fluid 10x10	3+ encysted fluid 6x1.2	1.5	22	58	105
7	AK (m)	50 / 13	yes 2x	4	5	2	1	20	57	33
8	AK (f)	34 / 6	yes 2x	4	4	2	1.5	10	15	28
9	FS (m)	54 / 2	yes	3 + encysted fluid 15x20	3	2.5	1	60	30	15
10	AP (f)	71 / 20	no	3	Full of fluid	3	3	10	24	65

m-male, f-female

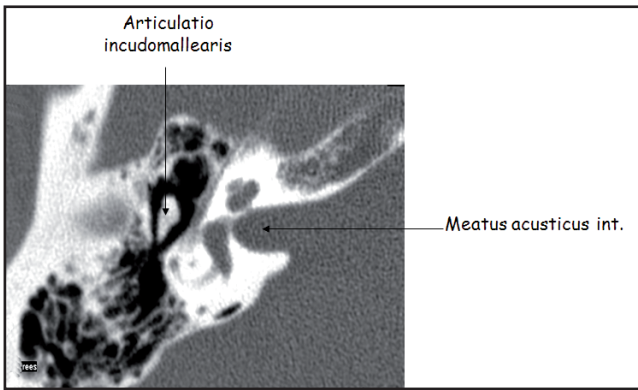


Fig. 1. "Ice cream corner" - typical, physiologic picture of middle ear and ossicles. Without any pathological findings.

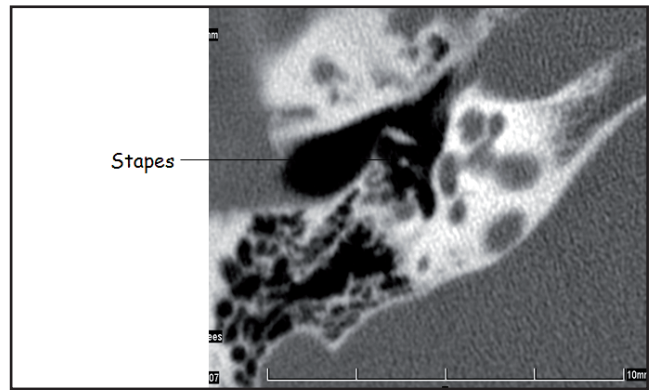


Fig. 2. Image on cochlea level. Without pathological findings.

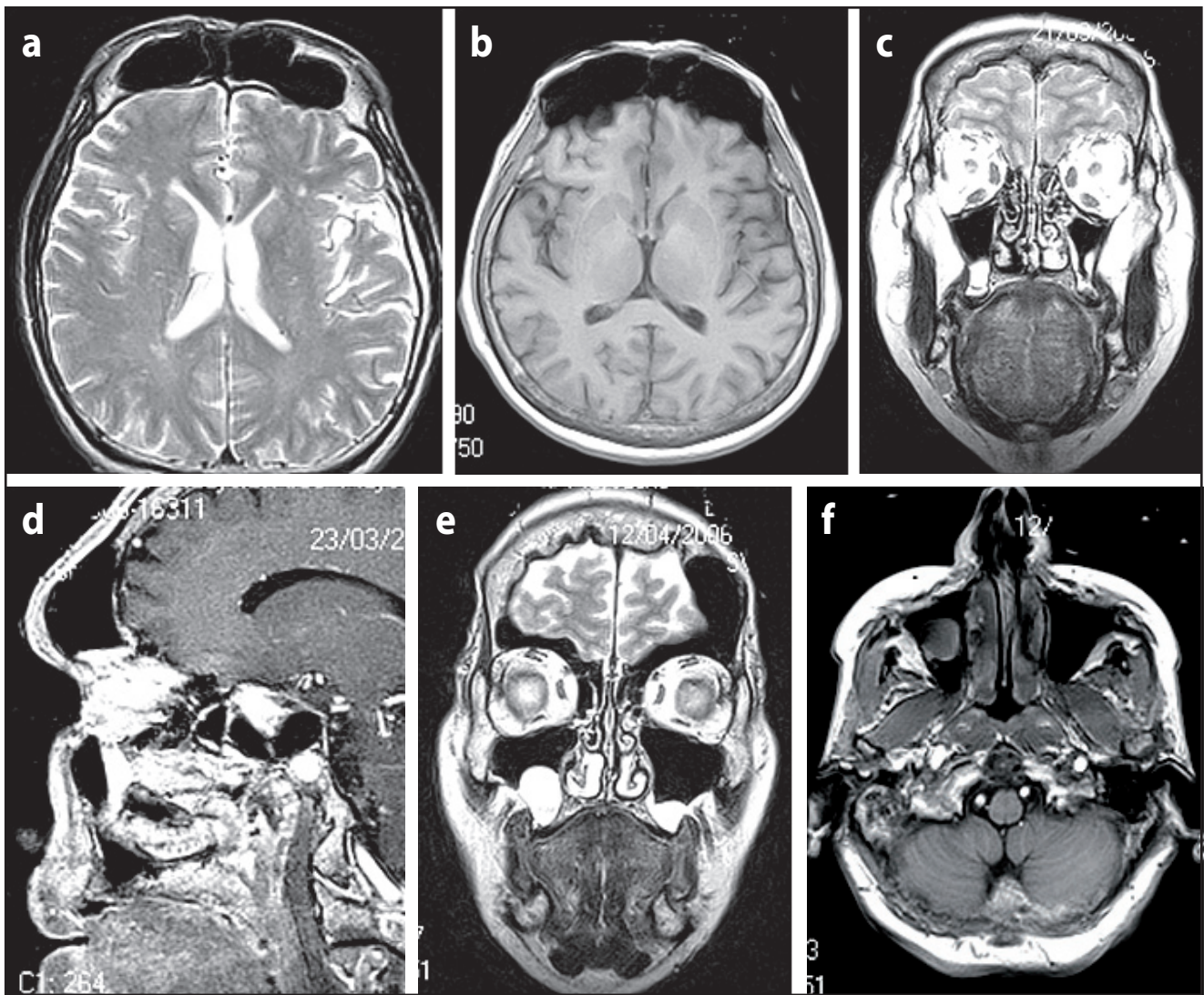


Fig. 3. MR images of examined patients. **a.** Enlarged frontal sinuses; **b.** Enlarged frontal sinuses; **c.** Fluid and thickening of mucosa in maxillary sinuses, encysted fluid in sinus ostia; **d.** Significant protuberance of the anterior wall, of the frontal sinus and fluid in ostia region, filling material in sphenoid sinus; **e.** Cysts of maxillary sinuses; **f.** Cysts of maxillary sinuses.

1978). In rare descriptions of otologic surgery in acromegaly patients (Meniere's disease, cholesteatoma) there is information about considerable thickening of the cortical bone layer of the mastoid process, thickening of all external auditory meatus or its posterior wall and thickening of the middle ear's cave bone. Middle ear's anatomy and topography was unchanged. In an X-ray of temporal bone in one of operated patients with mixed and sensorineural hearing loss physiological, proper and symmetric internal auditory meatuses were found (Graham & Brackmann 1978). In our study no pathologic changes in temporal bone, middle and inner ear anatomy and structure were stated. Auditory ossicles showed proper anatomy, size and position to each other and to oval fenestra. No stenoses in internal auditory meatus was stated.

In intraoperative descriptions of changes in nose and paranasal sinuses polyposis of ethmoidal sinuses were often – 67% of patients, and in sphenoid sinus – 43% of patients. Mucosa thickening, without polyps were found in 21% of patients in ethmoidal sinuses and 19% in sphenoid sinus. This changes were statistically significant in comparison with the control group. Neither nasal cavities nor maxillary sinuses showed statistically significant changes in comparison with the control group (Skinner & Richards 1988). In our study presence of polyps in nasal sinuses or cavities was not observed, but changes like mucosa thickening were present in all paranasal sinuses. The most important changes were present in maxillary sinuses. Noticed by Skinner *et al.* (1988) dependence between duration of acromegaly and sinus changes' intensity is confirmed in our study. Most of patients from our study group suffer from acromegaly over 3 years. Skinner *et al.* noticed more important intensity of changes in patients suffering longer, independent of age and level of GH (Skinner & Richards 1988).

In patients examined using MR because of neurological indications (different than sclerosis multiplex, which is connected with changes in paranasal sinuses) existence of incidental changes in paranasal sinuses in T2-weighted images was studied. Anomalies were stated in 38% of patients. Most often changes were in ethmoid sinus (44.8%), maxillary (38%) and sphenoid (14%). 20% of patients had changes in more than one sinus. This disorders had no statistical validity with ailments applied by patients except infection symptoms in upper respiratory tract (Wani *et al.* 2001). The most popular change was thickening of mucosa. Similar studies, carried out by Patel *et al.* showed incidental changes in paranasal sinuses in 49.2% of patients, where ethmoid sinuses were most often affected, and as the second affected were described maxillary sinuses (Patel *et al.* 1996). Only in 6.3% of patients bilateral changes were detected (Patel *et al.* 1996). In studies of Cooke *et al.* incidental disorders were explored in 37.5% patients, however changes in maxillary sinuses were more frequent than in ethmoid sinuses (Cooke & Hadley 1991).

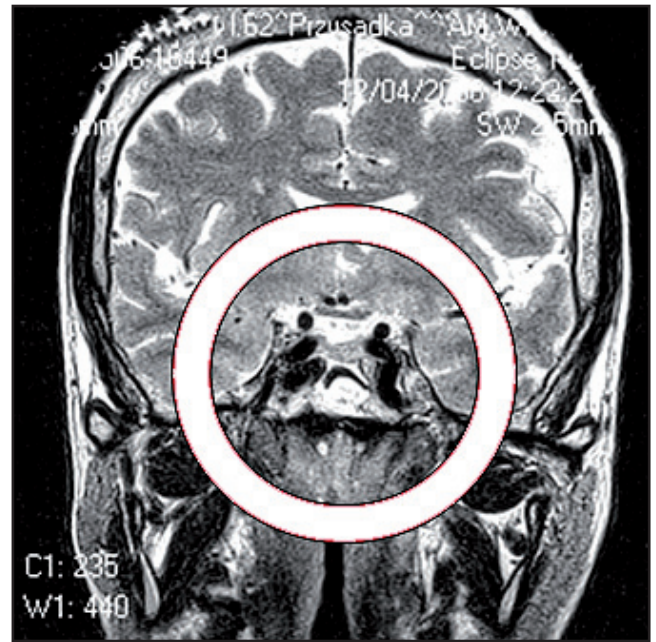


Fig. 4. Example of evaluation difficulties of sphenoid sinus after transsphenoidal hypophysectomy.

This study, evaluating changes in paranasal sinuses in patients examined from different than ENT reasons can be considered as a control to studied acromegaly group. In this study the stated high traceability of changes in paranasal sinuses can have no clinical value. However in the group of examined acromegalic patients the presence of changes in all patients, bilaterally, with accompanying nasal obturation (difficulties with nasal breathing), with headaches in some cases, seems to have clinical value. Average rate of septal deviation in general population is between 35 to 43 percent (Teul *et al.* 2009; Zielnik-Jurkiewicz & Olszewska-Sosińska 2006) and in the examined group was present in every case. Furthermore, not meaningless is the transsphenoidal approach to hypophysectomy during acromegaly treatment. It often results with nasal septum deviation, what influences the air flow and circulation through nasal cavities and nasal mucosa irritating. Kurowska *et al.* described case of 55 year old man suffering for acromegaly for 15 years, with a normal pituitary gland and ectopic somatotrophic pituitary adenoma revealed in the sphenoid sinus. MR helped to prove the absence of the connection between the tumor and the sellar pituitary (Kurowska *et al.* 2008).

Despite numerous discussions concerning CT and MR implementation in the diagnostics of paranasal sinuses disorders (Wani *et al.* 2001; Beahm *et al.* 1990; Patel *et al.* 1996) it is believed that MR is better than CT in evaluating changes in soft tissues, especially in differential diagnostics between malignant changes and fluid. It ought to be reserved to the expanded diagnostic of the paranasal sinuses. CT is suitable to evaluate

small bony changes and in qualifying for a surgery like functional endoscopic sinus surgery (FESS) (Wani *et al.* 2001; Cooke & Hadley 1991; Beahm *et al.* 1990; Branstetter & Weissman 2005).

CONCLUSIONS

1. In all patients with acromegaly, morphological changes in paranasal sinuses were shown. They were mostly pronounced within the maxillary sinuses including the mucosa thickening up to 6 mm and encysted fluid occurrence.
2. CT of temporal bone did not reveal structural changes of internal and median ear.
3. There is a need for further studies on hearing impairment in patients with acromegaly.

ACKNOWLEDGMENTS

The study was financially supported by grant no. 1296 from a reserve of the Wrocław Medical University for own research in years 2005–2006.

REFERENCES

- 1 Beahm E, Terasi E, Lufkin R, Hanafee W (1990). MR of the paranasal sinuses; *Surg Radiol Anat.* **12**: 203–208.
- 2 Bolanowski M, Zatońska K, Kaluzny M, Zielinski G, Bednarek-Tupikowska G, Bohdanowicz-Pawlak A, Daroszewski J, Szymczak J, Podgorski JK (2006). A follow-up of 130 patients with acromegaly in a single centre. *Neuro Endocrinol Lett.* **27**(6): 828–832.
- 3 Branstetter BF, Weissman JL (2005). Role of MR and CT in the paranasal sinuses. *Otolaryngol Clin North Am.* **38**(6): 1279–1299.
- 4 Cooke LD, Hadley DM (1991). MRI of the paranasal sinuses: incidental abnormalities and their relationship to symptoms. *J Laryngol Otol.* **105**: 278–281.
- 5 Doig JA, Gatehouse S (1984). Hearing in acromegaly. *J Laryngol Otol.* **98**: 1097–101.
- 6 Goldhill DR, Dalgleish JG, Lake RHN (1982). Respiratory problems and acromegaly. *Anaesthesia.* **37**: 1200–1203.
- 7 Graham MD, Brackmann DE (1978). Acromegaly and the temporal bone. *J Laryngol Otol.* **92**(4): 275–279.
- 8 Kurowska M, Tarach JS, Zgliczyński W, Malicka J, Zieliński G, Janczarek M (2008). Acromegaly in a patient with normal pituitary gland and somatotrophic adenoma located in the sphenoid sinus. *Endokrynol Pol.* **59**(4): 348–351.
- 9 Molitch M. Clinical manifestations of acromegaly (1992). *Endocrinol Metab Clin North Am.* **21**: 597–614.
- 10 Nabarro JDN (1987). Acromegaly. *Clin Endocrinol.* **26**: 481–512.
- 11 Patel K, Chavda SV, Violaris N, Pahor AL (1996). Incidental paranasal sinus inflammatory changes in a British population. *J Laryngol Otol.* **110**: 649–651.
- 12 Rajasoorya C, Holdaway IM, Wrightson P, Scott DJ, Ibbertson HK (1994). Determinants of clinical outcome and survival in acromegaly. *Clin Endocrinol.* **41**: 95–102.
- 13 Skinner DW, Richards SH (1988). Acromegaly- the mucosal changes within the nose and paranasal sinuses, *J Laryngol Otol.* **102**: 1107–1110.
- 14 Teul I, Zbislowski W, Baran S, Czerwinski F (2009). Deformation of the nasal septum in children, adolescents, and adults in Western Pomerania province of Poland. *Eur J Med Res.* **14**(4): 244–247.
- 15 Wani MK, Ruckenstein MJ, Parikh S (2001). Magnetic resonance imaging of the paranasal sinuses: Incidental abnormalities and their relationship to patient symptoms. *J Otolaryngol.* **30**(5): 257–262.
- 16 Zalesska-Kręcicka M, Zatoński T, Bolanowski M, Zatońska K (2006). ENT disorders in acromegalic patients. *Adv Clin Exp Med.* **15**(3): 549–551.
- 17 Zielnik-Jurkiewicz B, Olszewska-Sosińska O (2006). The nasal septum deformities in children and adolescents from Warsaw, Poland. *Int J Pediatr Otorhinolaryngol.* **70**(4): 731–736.