

Laparoscopic management of ectopic pregnancy

Malgorzata GAJEWSKA¹, Pawel KAMINSKI¹, Mirosław WIELGOS¹, Iwona SZYMUSIK¹,
Mariusz ZIMMER², Natalia MAZANOWSKA¹ and Tomasz FUCHS²

1. 1st Department of Obstetrics and Gynecology, Medical University of Warsaw, Poland.
Head of the Department: Professor Leszek Bablok MD, PhD

2. Department of Gynecology Obstetrics and Neonatology, Wrocław Medical University, Poland.
Head of the Department: Professor Mariusz Zimmer MD, PhD

Correspondence to: Ass. Prof. Mirosław Wielgos, MD, PhD
1st Department of Obstetrics and Gynecology, Medical University of Warsaw,
Plac Starynkiewicza 1/3, 02-015 Warsaw, Poland
TEL: +48 22 5021421; FAX: +48 22 5022157
E-MAIL: mwielgos@amwaw.edu.pl

Submitted: 2008-03-20 Accepted: 2008-03-31 Published online: 2008-04-18

Key words: **ectopic pregnancy; laparoscopy; laparoscopic treatment**

Neuroendocrinol Lett 2008; 29(2):267-271 PMID: 18404137 NEL290208A12 ©2008 Neuroendocrinology Letters • www.nel.edu

Abstract

OBJECTIVES: To assess the diagnostic process, laparoscopic treatment and post-operative period in patients hospitalized with a suspicion of ectopic pregnancy.

MATERIALS AND METHODS: 211 women who underwent a typical laparoscopic surgery due to ectopic pregnancy, from 1993 through to 2006, were included in the study. The diagnosis was based on the patient's history, gynecological examination, transvaginal ultrasound findings and β hCG concentration.

RESULTS: The abnormal uterine bleeding was the most often reported symptom at admission (70.1%). The typical triad for ectopic pregnancy – amenorrhoea, abnormal bleeding and pain were present in only 55 patients (26%). The most frequent ultrasound findings were abnormal echogenic structures on the side of operated ectopic pregnancy (77.3%). 15.7% of women had no abnormalities described. The most frequent site of ectopic pregnancy implantation was the ampulla of the Fallopian tube (59.7%). Salpingectomy was performed in 53.5% of the cases, while salpingotomy in 35%. The postoperative period was generally uneventful in the majority of patients. There were only two cases that required a second surgery because of the worsening general clinical condition of the patient.

CONCLUSIONS: The ectopic pregnancy is currently diagnosed quite early and therefore can be treated with the use of endoscopic tools in a scheduled operation time. Nowadays, only a small percentage of women still require a sudden open surgery intervention.

INTRODUCTION

The incidence of ectopic pregnancy, the implantation of an embryo outside the uterine cavity, reaches 1.3–2% of all pregnancies. Unfortunately, it is the leading cause of maternal mortality during the first trimester, as it is responsible for 9–13% of all maternal deaths related to pregnancy [4, 23]. The mortality rate accompanying ectopic

pregnancy has decreased from 16 to 3/10000 over the last 20 years. However, the rate continues to be very high in developing countries – for example in Cameroon it reaches 100 to 300 per 10000 pregnancies [4].

Biochemical tests (human chorionic gonadotrophin β serum concentration) and transvaginal ultrasound findings are the main and basic tools in diagnosing ectopic pregnancy. The classical

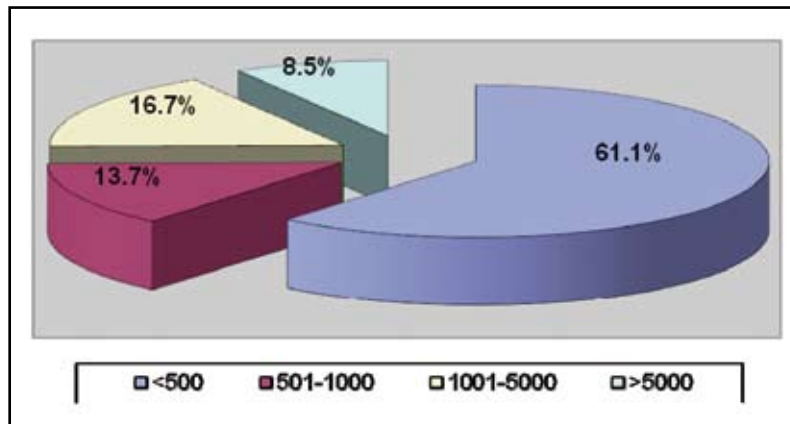


Figure 1. The distribution of serum β hCG concentrations (mIU/ml) before surgery

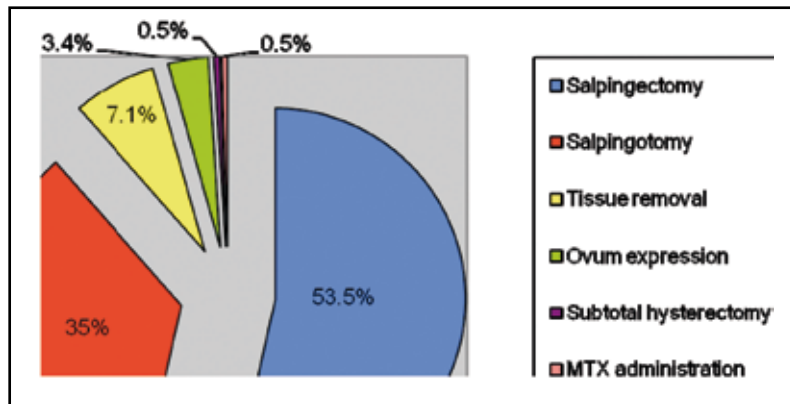


Figure 3. The type of performed procedure

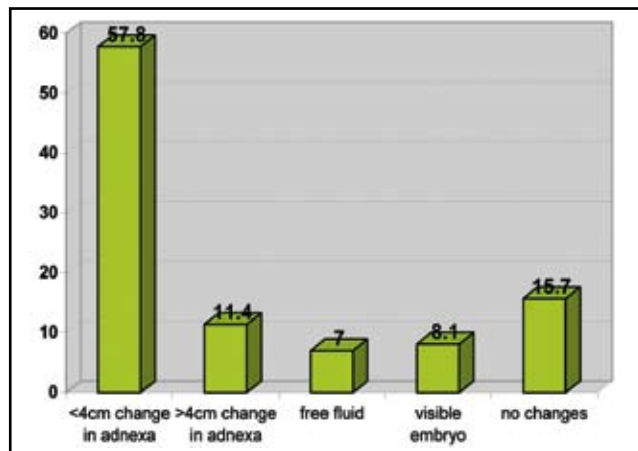


Figure 2. Ultrasound image in the group of women with ectopic pregnancy

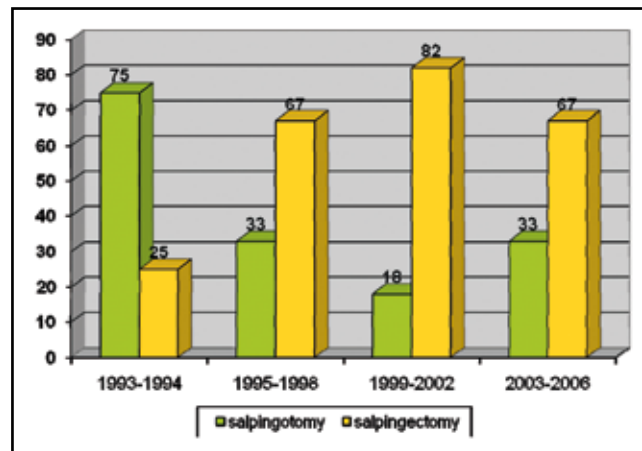


Figure 4. The rate of salpingotomies and salpingectomies performed over the studied period

presentation includes amenorrhoea, pain and bleeding – relying on symptoms only, however, would be misleading. This pathology can be suspected when β hCG concentration exceeds the normal range and there are no signs of intrauterine pregnancy on a transvaginal ultrasound scan. It should also be taken into account if β hCG concentrations stay around the same level in several consecutive samples. Physiologically, during normal pregnancy, levels of hCG roughly double over 48 hours, or the increase is at least 66% [13].

In 1884 Lawson Tait performed the first successful laparotomy because of a ruptured tubal pregnancy, removing the destroyed Fallopian tube with the trophoblast. Almost 70 years later, in 1953, Stromme performed the first salpingotomy in order to preserve the tube. Laparoscopic surgery in the management of ectopic pregnancy was introduced in the 1970's: salpingectomy in 1973 by Shapiro and salpingotomy five years later by Bruhat [15]. Today laparoscopy is a leading method of surgical treatment for ectopic pregnancy.

Table 1. The symptoms reported by patients from the study group

SYMPTOMS	n=211	%
Abnormal uterine bleeding	148	70.1
Abdominal pain	121	57.3
Amenorrhoea	116	55.0
Sudden acute pain in the lower abdomen	9	4.3
Fainting	5	2.4
Peritoneal signs	14	6.6
No clinical manifestation	2	0.2

The objective of the study was to assess the diagnostic process, laparoscopic treatment and postoperative period in patients who were hospitalized with a suspicion of ectopic pregnancy.

MATERIAL AND METHODS

The study group consisted of 211 women who underwent laparoscopic surgery due to ectopic pregnancy, from 1993 through to 2006. The diagnosis was based on the patient's history, gynecological examination, transvaginal ultrasound findings and β hCG concentration. Laparoscopy was performed typically in general anesthesia with endotracheal intubation. Karl Storz optics and Karl Storz, Olympus, Stryker and Pajunk instruments were used, as in previous studies from the same Department [11].

RESULTS

211 patients, aged 18–42 (average 29.3 ± 4.9 age), hospitalized due to ectopic pregnancy suspicion, were included in the study. In the study group 90 women (43%) had never been pregnant before. The remaining 121 (57%) had previously undergone one or more miscarriages (47 patients – 22%) and / or spontaneous vaginal delivery (77 women – 36%) or cesarean section (14 patients – 7%).

The risk factors of ectopic pregnancy were assessed in the whole study group. The previous history of adnexitis was reported by 12 women (5.7%), while 8 of them (3.8%) had had infertility treatment. Every fourth patient (54 women – 25.6%) had a medical history of abdominal surgery: ectopic pregnancy (18 women – 8.5%), cesarean section (14 women – 7%), appendectomy (13 – 6.2%) or other (9 patients – 4.3%). Among the patients who had previously undergone a surgery due to ectopic pregnancy, 12 (66.7%) had only one Fallopian tube, while in the remaining 6 women (23.3%) the current pregnancy implanted in the same tube that had previously been operated on (trophoblast removed by salpingotomy).

The symptoms reported by patients were afterwards analyzed (Table 1) and it proved that the abnormal uterine bleeding was the most frequent (148 women –

70.1%). The typical triad of symptoms for ectopic pregnancy – amenorrhoea, abnormal bleeding and pain were present in only 55 patients (26%). However, all of them had elevated serum β hCG concentration (Figure 1).

All the patients had a transvaginal ultrasound examination performed before the decision on operation was made. The examination showed abnormal echogenic structures on the side of operated ectopic pregnancy in 163 women (77.3%) – Figure 2. In 15 patients (7%) the only abnormality during ultrasound examination was the free fluid in the pelvic region. 33 women (15.7%) had no abnormalities described.

The most frequent site of ectopic pregnancy implantation was the ampulla of the Fallopian tube – 126 (59.7%) cases. A bulged and completely destroyed tube was found in 40 women (19%). Other kinds of ectopic localizations of pregnancy were more rare: 16 women (7.6%) had isthmic pregnancy, 12 (5.7%) – infundibular pregnancy, 2 (0.9%) had an intramural one. Fifteen patients (7.1%) had ampullar abortion diagnosed at the time of operation.

Figure 3 shows the treatment analysis in the operated women. Salpingectomy was the most frequently performed procedure (113 patients – 53.5%). Salpingotomy (the incision of the tube and evacuation of pregnancy) was in the second place (74 women – 35%). All the patients who underwent ampullar abortion had the tissues removed from the abdominal cavity. In 7 cases of infundibular pregnancy (3.4%) the contents of the tube were expressed into the pelvic cavity and afterwards removed. One patient with intramural pregnancy had a subtotal hysterectomy performed, while the other had methotrexate injected into the ovum at the time of laparoscopy. Figure 4 shows the rates of salpingotomies and salpingectomies performed in analyzed period.

All 211 women were qualified for laparoscopic surgery. Only four of them (1.9%) had laparoconversion: two due to massive adhesions in the pelvic region and one because of heavy abdominal bleeding. The last laparoconversion took place in a woman with intramural pregnancy, when the decision to perform a subtotal hysterectomy was made.

In 8% of the patients (17) a coexisting ovarian cyst was enucleated. The most frequent histopathological

diagnosis was the corpus luteum cyst (9 cases; 53%), while serous cystadenofibroma was described in two cases (11.8%).

The postoperative period was generally uneventful in the majority of patients. There were only two cases that required a second surgery because of the worsening general clinical condition of the patient. The first laparotomy was performed in a woman after local methotrexate administration – she suffered from increasing abdominal pain in the postoperative period. At the time of surgery the left uterine corn was bulged and livid, therefore it was removed. The second patient who required laparotomy bled from the abdominal ostium of the tube after ampullar abortion – therefore the decision to remove the oviduct was made.

DISCUSSION

The prevalence of ectopic pregnancy had been increasing over the past 30 years, probably due to the widespread infection with *Chlamydia*. Nowadays, a slight decrease has been observed, because the young population is more conscious of sexually transmitted infections and therefore they are better at prevention [4].

In the above presented study the mean age of the studied group was 29.3 years. It is generally very close to the average age of ectopic pregnancy prevalence presented by other authors – 29.5 [12], 30 [20] and 29.9 [15].

The history of adnexitis is one of the major risk factors of having ectopic pregnancy in the future due to the destructive influence of inflammation on tubal function. However, it was only reported by 5.7% of all studied women. The rate is usually higher – reaching 14.8% [12]. Only Karri et al. [7] mentioned the history of adnexitis in 0.9% of the operated patients. Additionally, the history of ectopic pregnancy itself increases the risk of undergoing another one in the future, especially if the conservative treatment was chosen. In the above presented study 8.5% of women had suffered from and had been operated on due to ectopic implantation in the past. The rate is smaller than the majority of those reported in the literature – 11.9 [12], 18.6 [20] and similar to that mentioned by Karri et al. [7]. The percentage of patients with a history of cesarean section was also smaller than described in the literature – 11.4% [12].

The course of an ectopic pregnancy with no symptoms nor discomfort is rather rare. The most common amenorrhoea is present in about 70% of cases with abnormal implantation. Only two women in the above study were asymptomatic (0.2%), while the rate mentioned by Karri et al. was much higher and reached 3.5% [7].

The tubal ampulla is the most frequent site of an ectopic pregnancy, which was confirmed in the above (59.7%) and other studies dealing with this clinical problem – 76.8% [22].

While taking laparoscopic treatment into consideration several risk factors of failure must be discussed. Beside demographic factor, obesity, history of laparotomies, laparoscopies, endometriosis or inflammatory conditions of small pelvis, the presence of free fluid in the pelvic region is now thought to be important [21]. Hsu et al. [6] claim that the amount of free fluid greater than 7cm in any dimension is related to a significant risk of intraperitoneal haemorrhage, however, it is not a predictive factor of laparoscopic surgery failure. Similarly, the serum β hCG concentration exceeding 5000mIU/ml can be correlated with a higher rate of intraperitoneal haemorrhage.

Nowadays, laparoscopy is a leading method of treatment for ectopic pregnancies. Hemodynamic instability of a patient is the major contraindication to perform laparoscopic surgery [14]. Classical abdominal surgeries are generally more often performed in such cases [10]. However, Canis et al. [2], Li et al. [9], Lo et al. [10] and Takeda et al. [22] consider the hemodynamic shock not to be a contraindication to endoscopic treatment. It is of great importance that the laparoscopy is then performed by experienced surgeons. Takeda et al. [22] and Li et al. [9] both underline the meaning of autotransfusion while such a procedure is performed during massive intraperitoneal haemorrhage. Li et al. [9] performed autotransfusion in 95% of women operated on during haemorrhagic shock and none of them required blood transfusion in the postoperative period.

The range of the performed procedure remains controversial. Conservative surgical treatment allows surgeons to spare the patient's tubes, however, the rate of consecutive ectopic pregnancy in such cases reaches 5 to 20% [14, 15]. Despite that fact, the percentage of intrauterine pregnancies after salpingotomy is still higher than after radical treatment [20]. It is important to monitor serum β hCG concentration following conservative surgery every week until negative values are obtained [14]. There are, however, various contraindications to salpingotomy: ruptured oviduct, lack of haemostasis at the site of operation, the size of the change exceeding 5cm, heterotopic pregnancy and the end of reproductive period. In the above presented study radical treatment outweighed conservative management (53.3% vs. 35%), which is similar to literature data: 89 vs. 11% [19], 75 vs. 19% [20], 98 vs. 2% [7], 68 vs. 27% [15], 80 vs. 16.7% [12] and 56 vs. 15.6% [1]. The increase in radical procedures during the last couple of years may be due to assisted reproductive technologies.

The literature widely discusses the problem of intramural pregnancy [8]. Both women in our study group had a uterine corn removed, one of them after earlier unsuccessful methotrexate administration. According to Canis et al. [2] intramural localization of pregnancy is an indication to pharmacological treatment as long as the patient is clinically stable. Chan et al. [3] described a successful laparoscopic treatment of such a pregnancy, in which the uterine corn was incised and the

trophoblast evacuated. A second-look laparoscopy after six months period showed completely normal uterus. Beside intramural pregnancy, the abdominal, cervical and ovarian pregnancies are also indications to pharmacological treatment. Methotrexate administration is moreover used in persistent ectopic pregnancy and as a prophylaxis of such a condition while there problems with trophoblast removal were encountered during an operation. Various centers apply methotrexate as a primary treatment in tubal pregnancy as well.

In the above study there was a need of laparoconversion in 4 (1.9%) women out of 211 who underwent an endoscopic operation; similar was obtained by Tahseen et al. – 2.7% [20]. That rate can generally be considered rather low in comparison to those mentioned in the literature: 7.27% [7], 14.5% [1], 15.7% [12], 20% [18], 27.6% [6], 31% [15] and even 36% [19]. Only Sagiv et al. [17] had to perform laparoconversion in one patient out of 101 (0.99%). In accordance with the literature, the most frequent causes of laparoconversions were massive adhesions and problems with haemostasis at the site of an operation.

Fujishita et al. discussed the problem of suturing the tubes after the incision and trophoblast removal. However, there were no shown advantages of such management on second-look laparoscopy after three months period [5]. Orazi et al. underlined the importance of intraperitoneal lavage and trophoblast removal in an endo-bag [16].

In conclusion, owing to the developing diagnostic procedures, the ectopic pregnancy is currently diagnosed quite early and therefore can be treated with the use of endoscopic tools in a scheduled operation time. The remaining small percentage of women still require a sudden intervention (most often classical open surgery), because they present with haemorrhagic shock as their first symptom.

REFERENCES

- Bukovic D, Simic M, Kopjar M, Zadro M, Fures R, Viskovic T, Unusic J. Early diagnosis and treatment of ectopic pregnancy. *Coll Antropol* 2000; **2**: 391–395.
- Canis M, Savary D, Pouly JL, Wattiez A, Mage G. Ectopic pregnancy: criteria to decide between medical and conservative surgical treatment? *J Gynecol Obstet Biol Reprod (Paris)*. 2003; **32**: 54–63.
- Chan LY, Yuen PM. Successful treatment of ruptured interstitial pregnancy with laparoscopic surgery. A report of 2 cases. *J Reprod Med* 2003; **48**(7): 569–71.
- Farquhar CM. Ectopic pregnancy. *Lancet* 2005; **366**: 583–591.
- Fujishita A, Masuzaki H, Khan KN, Kitajima M, Hiraki K, Ishimaru T. Laparoscopic salpingotomy for tubal pregnancy: comparison of linear salpingotomy with and without suturing. *Hum Reprod* 2004; **19**(5): 1195–200.
- Hsu S, Martin D, Aly A. Operative laparoscopy in tubal pregnancy: preoperative ultrasonographic measurement of hemoperitoneum as a predictor of blood loss and outcome. *J Reprod Med* 2005; **50**(2): 117–22.
- Karri K, Harris CP. Successful laparoscopic management of ectopic pregnancy In a district general hospital. *J Obstet Gynaecol* 2005; **8**: 769–771.
- Klimek M, Skotniczny K, Banas T, Wicherek L. A case of left interstitial pregnancy after left adnexectomy--why surgical management? *Neuro Endocrinol Lett* 2006; **27**(1–2): 288–9.
- Li ZG, Leng JH, Lang JH, Liu ZF, Sun DW, Lan Z. Laparoscopic surgery in patients with hypovolemic shock due to ectopic pregnancy. *Chin Med Sci J* 2005; **20**(1): 40–3.
- Lo L, Pun TC, Chan S. Tubal ectopic pregnancy: an evaluation of laparoscopic surgery versus laparotomy in 614 patients. *Aust N Z J Obstet Gynaecol* 1999; **39**(2): 185–7.
- Marianowski P, Kaminski P, Wielgos M, Szymusik I, Ludwikowski G. The comparison of microlaparoscopy and laparoscopy in pelvic region assessment in infertile women. *Neuro Endocrinol Lett* 2007; **28**(5): 704–7.
- Mohamed H, Maiti S, Phillips G. Laparoscopic management of ectopic pregnancy: a 5-year experience. *J Obstet Gynaecol* 2002; **4**: 411–414.
- Moore J. Early pregnancy units and problems in early pregnancy. *Current Obstet Gynaecol* 2006; **16**: 327–332.
- Murray H, Baakdah H, Bardell T, Tulandi T. Diagnosis and treatment of ectopic pregnancy. *CMAJ* 2005; **173**: 905–12.
- Olagundoye V, Adeghe J, Guirguis M, Cox C, Murphy D. Laparoscopic surgical management of ectopic pregnancy: a district general hospital experience. *J Obstet Gynaecol* 2000; **6**: 620–623.
- Orazi G, Cosson M. Surgical treatment of ectopic pregnancy. *J Gynecol Obstet Biol Reprod* 2003; **32**(7 Suppl): 75–82.
- Sagiv R, Debby A, Sadan O, Malinger G, Glezerman M, Golan A. Laparoscopic surgery for extrauterine pregnancy in hemodynamically unstable patients. *J Am Assoc Gynecol Laparosc* 2001; **8**(4): 529–32.
- Stoikov S, Emin A, Nikolova M. Gynecological laparoscopy and treatment of ectopic pregnancy. *Akush Ginekol (Sofia)* 2005; **44**(2): 23–5.
- Subair O, Omojole F, Mistry N, Morgan H. Trainees and management of ectopic pregnancy. *J Obstet Gynaecol* 2004; **7**: 811–812.
- Tahseen S, Wylde M. A comparative case-controlled study of laparoscopic vs laparotomy management of ectopic pregnancy: an evaluation of reproductive performance after radical vs conservative treatment of tubal ectopic pregnancy. *J Obstet Gynaecol* 2003; **2**: 189–190.
- Takacs P, Latchaw G, Gaitan L, Chakhtoura N, De Santis T. Risk factors for conversion to laparotomy during laparoscopic management of an ectopic pregnancy. *Arch Gynecol Obstet* 2005; **273**(1): 32–4.
- Takeda A, Manabe S, Mitsui T, Nakamura H. Management of patients with ectopic pregnancy with Massie hemoperitoneum by laparoscopic surgery with intraoperative autologous blood transfusion. *J Minim Invasive Gynecol* 2006; **13**: 43–48.
- Tulandi T, Sammour A. Evidence-based management of ectopic pregnancy. *Curr Opin Obstet Gynecol* 2000; **12**: 289–292.