

# Hyperprolactinemia presenting with encephalomalacia-associated seizure disorder and infertility: A novel application for bromocriptine therapy in reproductive endocrinology

David John Saie<sup>1</sup> & Eric Scott Sills<sup>2</sup>

<sup>1</sup> St. Christopher's College of Medicine, Luton, Bedfordshire, United Kingdom

<sup>2</sup> Division of Reproductive Endocrinology and Infertility, Department of Obstetrics and Gynecology, Atlanta Medical Center/Georgia Reproductive Specialists, Atlanta, Georgia USA

*Correspondence to:* Eric Scott Sills, M.D.  
Suite 270, 5445 Meridian Mark Road,  
Atlanta, Georgia 30342 USA  
EMAIL: [dr.sills@ivf.com](mailto:dr.sills@ivf.com) FAX: +1 404-843-0812

*Submitted:* June 30, 2005      *Accepted:* August 10, 2005

*Key words:*      **Encephalomalacia; hyperprolactinemia; infertility**

Neuroendocrinol Lett 2005; **26**(5):533-535    PMID: 16264405    NEL260505A17    © Neuroendocrinology Letters [www.nel.edu](http://www.nel.edu)

## Abstract

**OBJECTIVES:** To describe successful oral bromocriptine therapy for hyperprolactinemia accompanied by seizure disorder and encephalomalacia identified during infertility evaluation.

**MATERIALS & METHODS:** A 32 year-old male with an unspecified seizure disorder was referred for infertility consultation. The initial seizure was at age 12, and was treated sequentially with phenytoin, phenobarbital, and carbamazepine monotherapy which was maintained for six years and then discontinued. At age 26, a second seizure was experienced and 150mg lamotrigine b.i.d. was initiated. When the patient married it was discovered that erection was impossible; tadalafil was administered without success. At our center, total testosterone was low at 107ng/dl and semen analysis revealed oligoasthenozoospermia. Serum prolactin was 79.3ng/ml; visual field examination was normal. Brain MR showed no pituitary enlargement. However, encephalomalacia of the right occipital lobe with porencephalic dilation of the occipital horn of the right lateral ventricle was present.

**RESULTS:** The patient was initially placed on 2.5mg/d bromocriptine but after three months only a nominal reduction of serum prolactin was achieved. Serum prolactin normalized (25.4ng/ml) after bromocriptine was increased to 7.5mg/d. Repeat semen analysis showed overall sperm concentration of 85M/ml, 30% motility and 12% normal forms morphology (Kruger strict criteria). Total testosterone level was 191ng/dl after final bromocriptine dose was attained, which was well tolerated.

**DISCUSSION:** Bromocriptine has an established role in the management of hyperprolactinemia, particularly in women. For males with elevated serum prolactin even when associated with focal encephalomalacia and seizure disorder, bromocriptine therapy can offer safe benefits including improved semen parameters and normal serum testosterone levels.

## Introduction

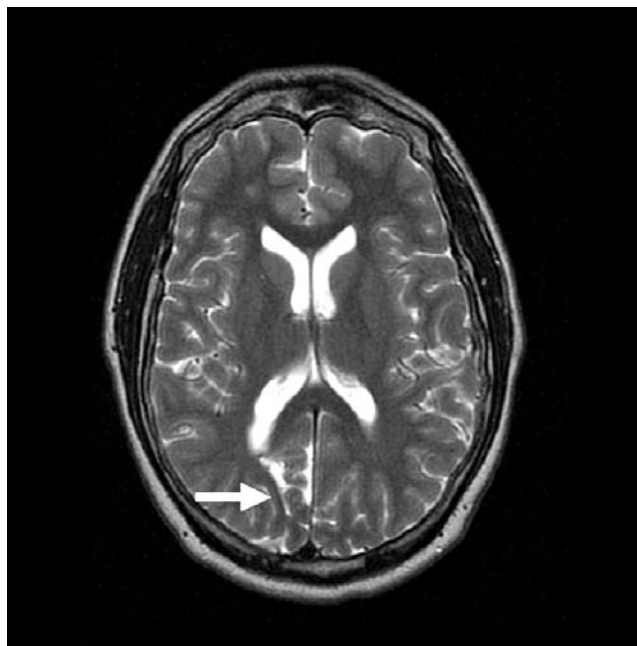
Hyperprolactinemia is encountered frequently during evaluation of the infertile couple, although in most cases the abnormality is identified in the female. Indeed, in reproductive endocrinology practice, detection of elevated prolactin is uncommon among men since onset of symptoms is typically delayed. In this report, management of male hyperprolactinemia in the context of seizure disorder and encephalomalacia is outlined. Successful correction of prolactin disorder and normalization of semen parameters is described using an established oral dopamine-agonist approach. The mechanism of action of such medications in the treatment of hyperprolactinemia is also reviewed.

## Case report

A 28 year-old female and 32 year-old male were referred for treatment of primary infertility of 12 months duration. The female was in good general health but had been diagnosed with benign multinodular thyroid six months earlier. This condition required no treatment and euthyroid status was confirmed at our center. Blood tests and cervical cytology were normal. At the time of the initial consultation the patient had not received any ovulation induction therapy and hysterosalpingography had not been performed.

The male had suffered from an unspecified epileptiform disorder from childhood. His seizures were believed to be associated with preterm delivery and/or birth trauma, but medical records could not confirm this hypothesis. At age 12, he was placed on antiepileptic therapy and had received a sequence of phenytoin, phenobarbitol, and finally carbamazepine monotherapy over the next several years. Carbamazepine was discontinued at age 18, and the patient remained seizure free for the next eight years. At age 26, a second large seizure occurred with no apparent inciting stimulus and the patient was placed on 150mg lamotrigine twice daily. Within two years the patient married and discovered erection was impossible; tadalafil was prescribed but the problem was not resolved.

Reproductive endocrinology consultation was requested and a serum total testosterone was found to be low in the male at 107ng/dl. At our center semen analysis showed both sperm concentration and motility to be moderately impaired; sperm morphology



**Figure 1:** Brain MR demonstrating encephalomalacia of the right occipital lobe (arrow) and porencephalic dilation of the occipital horn of the right lateral ventricle. Pituitary structure was normal.

was normal (Table 1). Serum prolactin was elevated at 79.3ng/ml. The patient denied headache and visual field examination was normal. Brain MR showed no pituitary enlargement, but conspicuous encephalomalacia of the right occipital lobe with porencephalic dilation of the occipital horn of the right lateral ventricle was noted (Figure 1).

With the exception of cystic fibrosis testing screen identifying the wife as a heterozygous carrier, the female's blood tests were unremarkable. The male was also tested and did not have any known cystic fibrosis mutation. Hysterosalpingogram showed normal intra-uterine contours, left tubal patency, and a large right hydrosalpinx. Laparoscopic (unilateral) salpingectomy was recommended for the wife before ovulation induction but insurance preauthorization could not be obtained for this procedure; her surgical plan was not final at the time of this report.

The husband was placed on 2.5mg/d oral bromocriptine and serum prolactin was retested one month later. Reduction of serum prolactin was achieved although the level remained above the normal refer-

**Table 1:** Selected andrology parameters measured as a function of oral bromocriptine therapy for prolactin elevation in a male with seizure disorder and encephalomalacia.

	semen analysis data			serum testosterone (ng/dl)
	concentration (M/ml)	motility (%)	morphology <sup>1</sup>	
t <sub>0</sub>	15	2	11	107
t <sub>1</sub>	85	30	12	191

<sup>1</sup>strict/Kruger criteria t<sub>0</sub> = baseline/pre-treatment, t<sub>1</sub> = post-treatment with bromocriptine (7.5mg/d)

ence range (29.8ng/ml). Bromocriptine was adjusted to 5mg/d for one month and the serum prolactin was attenuated further to 25.4ng/ml. The level still above the normal reference range, the bromocriptine dose was adjusted upward to 7.5mg/d for one month. Serum testosterone after treatment was 191ng/dl. During phases of bromocriptine dosage increase the patient described no hypersomnolence but did report agitation and “feeling wired”. For this reason, the customary nighttime administration of bromocriptine was reconfigured to a better-tolerated morning dose regimen. The semen analysis was repeated after bromocriptine therapy and improvements were noted for all parameters (*Table 1*); serum testosterone was also optimized post-treatment. No dosage adjustments were required for lamotrigine during treatment, and the patient remained seizure free during combined bromocriptine + lamotrigine therapy.

## Discussion

Sexual dysfunction resulting from hyperprolactinemia in males due to interference with pulsatile gonadotropin release has been a recognized clinical phenomenon for many years [3]. In contrast, associations among prolactin elevation, encephalomalacia and seizure disorder have not been previously reported. In our case a thorough neurological evaluation preceded initiation of effective antiepileptic therapy although the duration of hyperprolactinemia could not be known with certainty.

The exploration for causes of hyperprolactinemia in patients with a complex neurological presentation must include careful assessment of medications which may alter pituitary function. Our patient’s only medication was lamotrigine, a relatively new antiepileptic agent not known to elicit an immediate hyperprolactinemia response. However, hyperprolactinemia has been identified as a possible result of rapid lamotrigine dose titration [4]. Additional study is needed to determine whether or not prolactin elevation might result from a constant lamotrigine dose maintained over several years, as was the case for our patient. Animal studies of lamotrigine with respect to serum androgen levels and fertility showed both impaired sperm dynamics and testosterone concentration [2].

Bromocriptine is a non-hormonal dopamine receptor agonist which activates post-synaptic dopamine receptors and inhibits anterior pituitary release of prolactin. While dopamine agonists have been used successfully as first-line therapy for simple hyperprolactinemia for many years, there is less clinical experience with lamotrigine. Indeed, no published studies exist describing clinical outcomes when the two agents are used concomitantly. Given the fact that our patient remained seizure free while receiving both medications, our case suggests the antiepileptic efficacy of lamotrigine is not adversely affected by simultaneous bromocriptine therapy.

The role of encephalomalacia in our case is unclear and likely represents a distinct intracranial lesion not related to the hyperprolactinemia. Indeed, encephalomalacia involving the occipital lobe accompanied by porencephalic dilation of the occipital horn of the right lateral ventricle is more likely associated with epileptiform disorder. Despite the multiple brain abnormalities identified here, correction of hyperprolactinemia and improvement in sexual response was achieved with oral bromocriptine. A refractory response to first line bromocriptine therapy is encountered only in a minority of cases, and for these individuals transsphenoidal resection of a pituitary adenoma may be required.

## REFERENCES

- 1 Danila DC, Klibanski A. Prolactin secreting pituitary tumors in men. *Endocrinologist* 2001; **11**(2):105–111.
- 2 Daoud AS, Bataineh H, Ootom S, Abdul-Zahra E. The effect of vigabatrin, lamotrigine and gabapentin on the fertility, weights, and sex hormones and biochemical profiles of male rats. *Neuro Endocrinol Lett* 2004; **25**:178–83.
- 3 Friesen HG. The discovery of human prolactin: a very personal account. *Clin Invest Med* 1995; **18**:66–72.
- 4 McIntyre RS. Psychotropic drugs and adverse events in the treatment of bipolar disorders revisited. *J Clin Psychiatry* 2002; **63** Suppl 3:15–20.