

A pituitary abscess with one year follow-up after conservative treatment: A case report

Ning YUAN¹, Sanbao CHAI¹, Jianbin SUN¹, Yufang LIU¹, Sixu XIN¹,
Linong Ji², Xiaomei ZHANG¹

¹ Department of Endocrinology, Peking University International Hospital, Beijing 102206, China

² Department of Endocrinology, Peking University People's Hospital, Beijing 100044, China

Correspondence to: Xiaomei Zhang
Department of Endocrinology, Peking University International Hospital
Beijing 102206, China.
E-MAIL: z.x.mei@163.com

Submitted: 2017-07-13 Accepted: 2017-10-17 Published online: 2018-01-23

Key words: **pituitary abscess; sphenoiditis; type 2 diabetes**

Neuroendocrinol Lett 2017; **38**(8):532-536 PMID: 29504730 NEL380817C01 © 2017 Neuroendocrinology Letters • www.nel.edu

Abstract

Pituitary abscess (PA) is a rare intrasellar infectious disease presented in less than one percent of all cases of pituitary disease. We reported a case of a 58-year-old woman with a history of type 2 diabetes (T2DM) exhibited with headaches, nasal discharge, anosmia, diabetes insipidus and hypopituitarism due to PA, she was diagnosed based on clinical presentations, endocrine examination and MRI image features. She was treated with nasal wash and antibiotic therapy without surgical intervention. She has received hormone replacement therapy for one year and her condition has gradually become stabilized. Meanwhile, the lesion of MRI image didn't become serious after one year. Conservative treatment might be an option for the patients with PA, those rejected operation or in a stable condition.

INTRODUCTION

Pituitary abscess is a rare intrasellar infectious disease associated with a clinical syndrome characterized by headache, diabetes insipidus, antehypophysis hypofunction and vision disturbance. It has been rarely reported in the medical literatures (Ciappetta *et al.* 2008). PA is divided into primary and secondary according to their etiology. The diagnostics of PA is based on clinical presentations, endocrine examination, MRI image and the histology after surgery. Its treatment is mainly abscission, however, some cases have been treated with conservative medication (Dechambenoit *et al.* 2008; Kaur *et al.* 2005). There was rarely long-term follow-up data in the literature, while hypopituitarism remained in the most patients following treatment. Here, we report an interesting case of pituitary abscess with a history of chronic Spheno-

noiditis. She was treated with nasal wash and antibiotic therapy without surgical intervention and was in a stable condition with permanent hormone replacement therapy.

CASE PRESENTATION

A fifty year-old woman suffered with headaches, nasal discharge and anosmia for ten months. The headache showed periodic spasmodically pain. During the last one month, she had become weak, nausea and vomiting. She was referred to the Otolaryngology Department of the local hospital and was diagnosed with Sphenoiditis. Since the patient had a history of T2DM for two years together with polydipsia, polyuria, nausea and vomiting at this time, the blood glucose was high and urine ketone was positive. She was diagnosed diabetic ketosis and treated with fluid infusion and insulin

injection. However, after the blood glucose was finally normal again and urine ketone became negative, the symptoms have not been improved and then she consulted our hospital. The patient hadn't any other past medical history and she was not taking any regular medication. She is a nonsmoker and did not drink any alcohol. The woman is postmenopausal for a year. And she is married and has two healthy children through breast feeding.

Investigation

As we diagnosed the patient's vital signs in our department, she exhibited body temperature of 36.5 °C a heart rate of 84 beats/min, respiratory rate of 18 breaths/min, and blood pressure of 100/70 mmHg, while her body mass index (BMI) was 26.0 kg/m². On physical exam, the patient presented apathetic facial expressions, slow response, xerosis cutis and deep voices. Rhythm of the heart was stable, lungs were clear and abdomen examination was benign. There were no galactorrhea, no meningeal signs and no neurological or cranial nerve deficit signs.

Laboratory investigation including biochemical profile, complete blood count, immunoserologic indexes and C-reactive protein (CRP) levels, were all

within the normal range. The urine-specific gravity of a urinalysis was 1.008 and plasma osmolality was 260 mOsm/kg H₂O (Table 1). The water deprivation test was positive and the diagnosis of central diabetes insipidus was confirmed combining with the symptoms of thirsty, polydipsia and polyuria. The results of the endocrine investigations were consistent with hypopituitarism including thyroid-stimulating hormone (TSH), adrenocorticotropic hormone (ACTH), follicle-stimulating hormone (FSH), luteinizing hormone (LH), serum prolactin (PRL) and so on (Table 2). Magnetic resonance imaging (MRI) of sphenoid showed high signal on T1WI and on T2WI involving the sellar, with heterogeneous density in enhanced scan (Figure 1). MRI of pituitary showed a sellar and suprasellar mass measuring 9×13 mm (Figure 1). The high signal on both T1WI and T2WI, with peripheral enhancement after administration of contrast material. The lesion became smaller after 10 days of conservative therapy including nasal wash and antibiotic. The sphenoid sinus was high signal on T1WI and on T2WI, with heterogeneous density in enhanced scan (Figure 1A–D).

Diagnosis and treatment

The patient was diagnosed from hypopituitarism according to the clinical symptoms, the masculine symptom and the auxiliary inspection. In order to explore the cause of hypopituitarism, we inquired the medical history in detailed and detected IgG4, immune parameters and tumor markers. Unfortunately, no positive results were obtained. The imaging specialists considered the lesion conformed to pituitary abscess according to the feature of lesion. Otolaryngologist thought pituitary abscess was caused by chronic Sphenoiditis and suggested nasal wash and antibiotic treatment. Neurosurgeon advised surgical procedure was carried out, but the patient refused the surgery. Then we decided to give the patient conservative treatment. Nasal wash and antibiotic (Levofloxacin) treatment for one month were given to the patient according to the suggestion of Otolaryngologist. At the same time, hydrocortisone and euthyrox replacements were initiated. Five days later, the patient became better and began to eat normal food again. After desmopressin acetate was given to the patient, the 24 h urine volume reduced from 4000–5000 ml/24 h to 2000 ml/24 h.

Follow-up and outcome

During 6-months the patient's headaches, nausea and vomit have gradually disappeared and the 24 h urine volume has reduced to 2000 ml/24 h. One year later, the patient still received Hydrocortisone and Euthyrox replacement therapy. The lesion of MRI image showed a sellar and suprasellar mass measuring 10×11 mm. The signal was high signal on T1WI and on T2WI, with peripheral enhancement after administration of contrast material (Figure 1E and F).

Tab. 1. Patient's biochemistry results.

Test	Result	Normal range
White blood cell count	6.85×10 ⁹ /L	3.5–9.5×10 ⁹ /L
Urine-specific gravity	1.000	1.003–1.030
Osm	260 mOsm/Kg	600–1000 mOsm/kg

Tab. 2. Patient's endocrine biochemical test.

Test	Result	Normal range
LH	0.01 U/L	5.16–61.99 U/L
FSH	0.24 U/L	26.72–133.41 U/L
PRL	1.70 ng/ml	5.18–26.53 ng/ml
Prog	<0.10 ng/ml	0–0.2 ng/ml
Testo	<0.45 nmol/L	0.38–1.97 nmol/L
E2	<10.00 pg/ml	<10–28 pg/ml
GH	<0.050 ng/ml	≤10.000 ng/ml
FT4	6.70 pmol/l	12.00–22.00 pmol/l
TSH	0.044 μIU/ml	0.270–4.200 μIU/ml
CORT 8am	0.08 μg/dl	6.2–19.5 μg/dl
CORT 4pm	0.09 μg/dl	2.3–11.9 μg/dl
CORT 0am	0.27 μg/dl	2.3–11.9 μg/dl
ACTH 8am	2.55 pmol/L	1.10–10.21 pmol/L
ACTH 4pm	<2.20 pmol/L	1.10–10.21 pmol/L
ACTH 0am	<2.20 pmol/L	1.10–10.21 mol/L

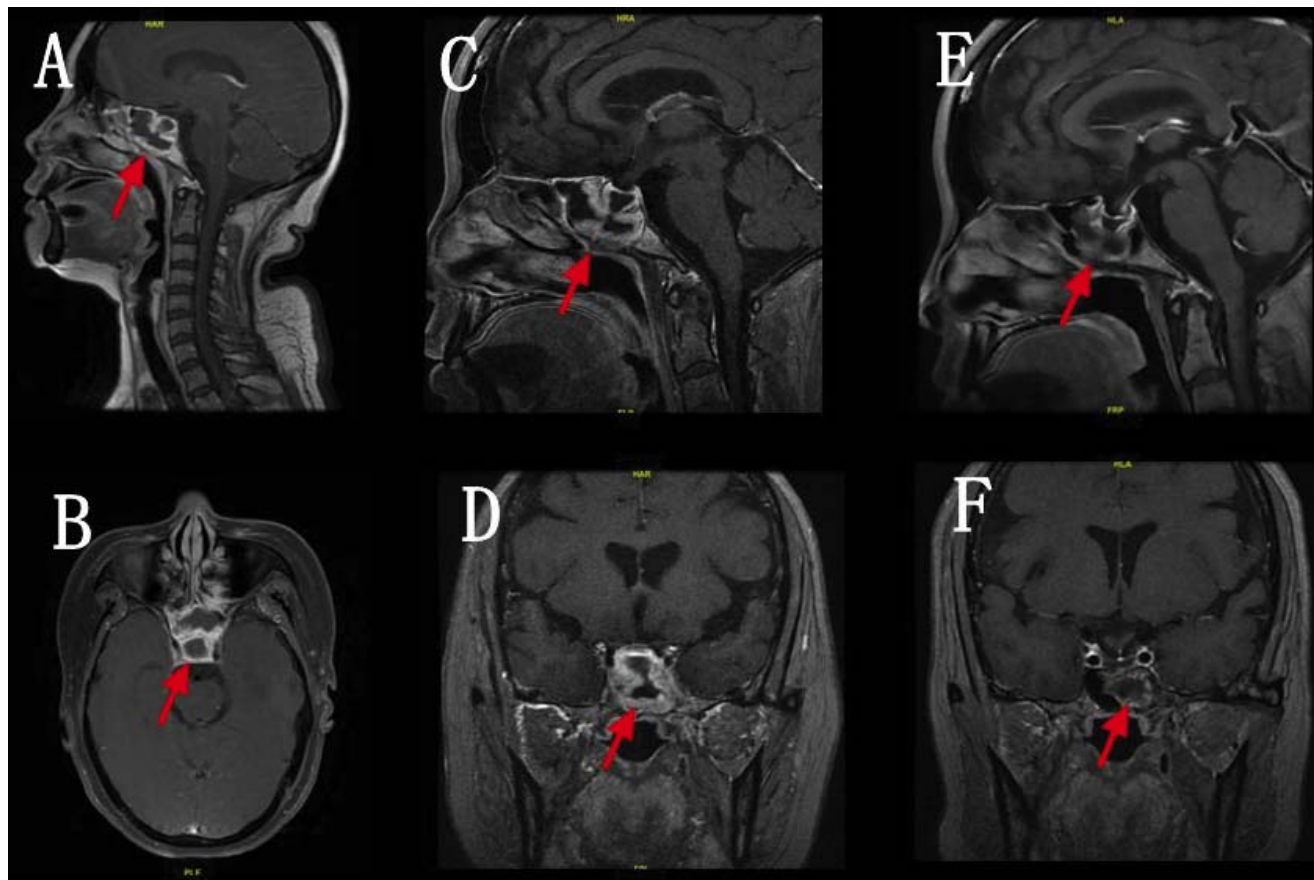


Fig. 1. Pituitary abscess demonstrated in sagittal views (A, C and E) and in axial views (B, D and F). MRI of sphenoid (A and B) showed high signal on T1WI and on T2WI involving the sellar, with heterogeneous density in enhanced scan. MRI of pituitary (C and D) showed a sellar and suprasellar mass measuring 9×13 mm. The signal was high signal on T1WI and on T2WI, with peripheral enhancement after administration of contrast material. Also the sphenoid sinus was high signal on T1WI and on T2WI, with heterogeneous density in enhanced scan. MRI of pituitary (E and F) of one year later showed a sellar and suprasellar mass measuring 10×11 mm. As the signal was high signal on T1WI and on T2WI, with peripheral enhancement after administration of contrast material.

DISCUSSION

PA is an odd disease which was first reported by Heslop in 1848. So far, there was approximately 250 cases which were reported by case reports in the medical literature (Ciappetta *et al.* 2008; Ouyang *et al.* 2015; Liu & You 2015; Liebert *et al.* 2010). The frequency of PA is 1.04% (66 PA cases out of 6361 pituitary disease cases) of operated pituitary lesions was reported by Lu Gao in Peking Union Medical College Hospital between January 1991 and December 2013 (Gao *et al.* 2017).

The clinical manifestations of PA are non-specific and obscure. Headache is the most common symptom. Other symptoms such as diabetes insipidus, hypopituitarism and vision disturbance are common. Diabetes insipidus is common in PA, but is a bizarre symptom in pituitary adenomas (Liu *et al.* 2011). Although PA is an infectious disease, only one-third of the PA patients have infectious manifestations, such as fever, an elevated white blood cell count and CRP (Shuster *et al.* 2010). The presentation of PA is different from those of other common infectious diseases. Firstly, half of the patients do not have risk factors for pituitary infection, includ-

ing bloodstream infections, an intrasellar tumor or post-pituitary operation (Tekkök *et al.* 2001). Secondly only 24–33% of patients with a pituitary abscess had systemic signs of inflammation (Vates *et al.* 2001; Dalan & Leow 2008). The main clinical manifestations of our patient were headaches, diabetes insipidus and antehypophysis hypofunction without vision disturbance. Diabetes insipidus became apparent after corticosteroid replacement therapy. Our patient had a history of chronic Sphenoiditis and could present no fever and elevated white blood cell count.

MRI is often used for diagnosis of the illness in sellar region. Patients usually showed typical features of abscess, including isointensity or hypointensity on T1-weighted imaging (T1WI), isointensity or hyperintensity on T2-weighted imaging (T2WI), and a cystic sellar lesion with peripheral ring-shaped enhancement after gadolinium injection. Other features of MRI appears inhomogeneous intensities on T1WI and T2WI, with irregular enhancement (Guo *et al.* 2017; Shuster *et al.* 2010). Our patient's pituitary MRI showed a sellar and suprasellar mass measuring 9×13mm. The signal was consistent with typical features of PA showed

high signal on T1WI and on T2WI, with peripheral enhancement after administration of contrast material. After nasal irrigation and antibiotics, the lesion of PA became smaller one year later.

The diagnostics of PA was based on clinical presentations, endocrine examination and MRI image before operation. However the final diagnosis is usually based on the histology after surgery. However, some patient refused to have an operation such as our patient. For these patients, the clinical diagnosis of PA was mainly based on the typical features, endocrine examination and MRI image. Lu Gao *et al.* (2017) found that a diagnosis of PA was correctly made in 39 patients (59.1%) before surgery. Our patient had typical features, endocrine examination and MRI image of PA and was clinically diagnosed as PA without surgery.

PA is divided into two main categories: primary and secondary according to their etiology. Primary PA occurs in previously healthy normal glands, such as Cavernous Sinus Thrombophlebitis and Suppurative Sphenoiditis. Secondary PA occurs in pre-existing lesions in the pituitary region, such as craniopharyngioma, meningiomas, pituitary adenoma, Rathke's cleft cysts. The proportion of primary PA and secondary PA are 69.7% and 30.3% (Gao *et al.* 2017).

In this report, the female had a history of chronic Sphenoiditis and on other pituitary disorder, so she belonged to primary PA. We thought PA was caused by chronic Sphenoiditis as following reasons. Firstly, although there was seldom case reports about chronic Sphenoiditis and PA, our patient only had a history of diabetes and hadn't prior transsphenoidal surgery, radiation and immune suppression. Secondly our patient's MRI showed sellar bone was discontinuous, so pus could discharge from sellar. Moreover after one year, anasal irrigation, the patient's symptom such as headache and the lesion of PA became smaller. Sphenoiditis is relatively rare occurred in adults, which may cause headache, blurred vision and intracranial complications include meningitis, cavernous sinus thrombosis, subdural empyema and epidural/subdural/brain abscess, while PA is rarely mentioned (Seto *et al.* 2014). Our patient presented with headaches, nasal discharge and anosmia and MRI of sphenoid sinus showed increase of sinus cavity density and the circular thickening of sinus ring. Indefinitely she was possibly diagnosed chronic Sphenoiditis. Although the case reports about PA caused by chronic Sphenoiditis were seldom, we could find sellar bone erosion possibly caused by Sphenoiditis in our patient. Our patient was clinically diagnosed with PA finally by the consultations of multiple disciplinary team (MDT) including imaging specialists, otolaryngologist and neurosurgeon.

Prior transsphenoidal surgery, radiation and immune suppression are the common risk factors. However, there are still unknown risk factors in some cases. In this report, the patient had a history of chronic Sphenoiditis without prior transsphenoidal surgery,

radiation and immune suppression. The patient had a history of diabetes with insulin treatment, while the blood glucose wasn't satisfactory. A large clinical cohort study showed that DM appeared to have an important impact on chronic rhinosinusitis (Zhang *et al.* 2014). Compared to chronic rhinosinusitis patients without DM, patients with DM were significantly more likely to have positive *P. aeruginosa* and other gram negative rods. Maybe diabetes and unsatisfied blood glucose were risk factors of PA caused by chronic rhinosinusitis.

Pathogen spectra of PA were extensive, which were reported in literature, including gram-negative bacteria, gram-positive bacteria, anaerobic bacteria and fungi. Coagulase-negative Staphylococcus is the most commonly isolated microorganism (Dalan & Leow 2008). The positive detection rate and pathogen spectra differed between primary PA and secondary PA. Primary PA had a lower positive detection rate and were primarily Gram-positive or Gram-negative bacteria, including little fungal. On the other hand, secondary PA had a higher positive detection rate and was primarily *Aspergillus fumigatus* (Gao *et al.* 2017). Blood culture wasn't obtained because the patient had no fever and inflammatory indicators were generally normal.

The treatments of PA consist of transsphenoidal surgical drainage and antibiotic therapy. Broad-spectrum antibiotic therapy should be the best way for patients with PA. Endocrine deficiencies may need permanent hormone replacement therapy. Visual deficiencies are usually improved after operation. In this report, the patient refused the operation and would like to receive antibiotic and permanent hormone replacement therapy. She didn't suffer visual deficiencies and become more serious, moreover, the lesion of MRI image became smaller after one year. We would continue to give her long time follow up. Thus, most cases were postoperative visiting and there were seldom follow-up cases with conservative treatment reported in the literatures.

CONCLUSIONS

In conclusion, this case report highlights the alternative process of medical treatment for PA, without undergoing in surgery is an option. However, hypopituitarism following PA is a potentially life-threatening disease, and the patient must be closely monitored. If significant improvement is absent or if the patient's condition deteriorates, surgery is urgently required.

REFERENCES

- 1 Ciappetta P, Calace A, D'Urso PI, De Candia N (2008). Endoscopic treatment of pituitary abscess: two case reports and literature review. *Neurosurg Rev.* **31**: 237–246.
- 2 Dalan R, Leow MK (2008). Pituitary abscess: our experience with a case and a review of the literature. *Pituitary.* **11**: 299–306.
- 3 Dechambenoit G, Datie A, Grunitzky EK, Ba Zeze V, Boni N, Kakou M, Santini JJ (1993). Pituitary abscess, treated by medication. *Revue Neurologique.* **149**: 567–571.

- 4 Gao L, Guo X, Tian R, Wang Q, Feng M, Bao X, Deng K, Yao Y, Lian W, Wang R, Xing B (2017). Pituitary abscess: clinical manifestations, diagnosis and treatment of 66 cases from a large pituitary center over 23 years. *Pituitary*. **20**: 189–194.
- 5 Heslop TP (1848). A case of hypertrophy with abscess of the pituitary body. *Dublin Quart J M*. **6**: 466.
- 6 Kaur A, Agrawal A, Mittal M (2005). Presumed pituitary abscess without infectious source treated successfully with antibiotics alone. *Journal of Neuro-Ophthalmology*. **25**: 185–188.
- 7 Liebert W, Szymas´ J, Was´ko R, Paprzycki W (2010). Pituitary abscess: a case report. *Neuro Endocrinol Lett*. **31**: 597–601.
- 8 Liu F, Li G, Yao Y, Yang Y, Ma W, Li Y, Chen G, Wang R(2011). Diagnosis and management of pituitary abscess: experiences from 33 cases. *Clin Endocrinol (Oxf)*. **74**: 79–88.
- 9 Liu J, You C (2015). Primary pituitary abscess. *Neurol India*. **63**: 1000–1001.
- 10 Ouyang T, Zhang N, Wang L, Jiao J, Zhao Y, Li Z, Chen J (2015). Primary aspergillus sellar abscess simulating pituitary tumor in immunocompetent patient. *J Craniofac Surg*. **26**: e86–8.
- 11 Seto T, Takesada H, Matsushita N, Ishibashi K, Tsuyuguchi N, Shimonoto T, Hikita N, Hattori T, Tanaka K, Shintaku H (2014). Twelve-year-old girl with intracranial epidural abscess and sphenoiditis. *Brain & Development*. **36**: 359–361.
- 12 Shuster A, Gunnarsson T, Sommer D, Miller E (2010). Pituitary abscess: an unexpected diagnosis. *Pediatr Radiol*. **40**: 219–222.
- 13 Tekkk IH, Akpınar G and Gungen Y (2001). Abscess formation within a pituitary adenoma: report of a case and review of the literature. *Infect Dis Clin Pract*. **10**: 367–373.
- 14 Vates GE, Berger MS, Wilson CB (2001). Diagnosis and management of pituitary abscess: a review of twenty-four cases. *J Neurosurg*. **95**: 233–241.
- 15 Zhang Z, Adappa ND, Lautenbach E, Chiu AG, Doghramji L, Howland TJ, Cohen NA, Palmer JN (2014). The effect of diabetes mellitus on chronic rhinosinusitis and sinus surgery outcome. *Int Forum Allergy Rhinol*. **4**: 315–320.