

Treatment of macular degeneration (A controlled case)

Petr Soucek & Ilona Cihelková

The Eye Department, University Hospital, Prague, CZECH REPUBLIC.

Correspondence to: Petr Soucek, M.D.,
The Eye Department,
University Hospital,
Šrobárova 50, 100 34 Prague, CZECH REPUBLIC.
TEL: +420 2 6716 2390; FAX: +420 2 6716 2491
E-MAIL: soucek@fnkv.cz

Submitted: July 11, 2002

Accepted: July 13, 2002

Key words: **Age-related macular degeneration; choroidal neovascularization; verteporfin; photodynamic therapy; fluorescein angiography; optical coherence tomography**

Neuroendocrinology Letters 2002; 23:370-372 pii: NEL230402A12 Copyright © Neuroendocrinology Letters 2002

Abstract

Our controlled case describes the drug possibility to stabilize the exudative form of Age-related Macular Degeneration. The new approach of selective destruction of choroidal neovascularization (CNV) can be applied in patients with subfoveal lesions. Photodynamic therapy (PDT) is based on the reaction of photoactivable drug with the light of low-energy laser beam. So far only verteporfin [Visudyne, Novartis] as sensitizer is marketed and laser with wavelength of 689 nm is used. But it is questionable whether to apply this very costly treatment to extremely old people. An example of treatment of 90-year old woman with AMD with classic form of CNV is presented. Her BCVA was 0.05 OD. She underwent four session of PDT. At the last visit (eighteen months after initial and ten months after last session of PDT) the BCVA remained 0.05 OD. The patient is using a special magnifying lens for reading achieving near vision of 0.32.

The presented example indicates the necessity of detailed study of every case to promote the therapeutic decisions for the benefit of progress in the field.

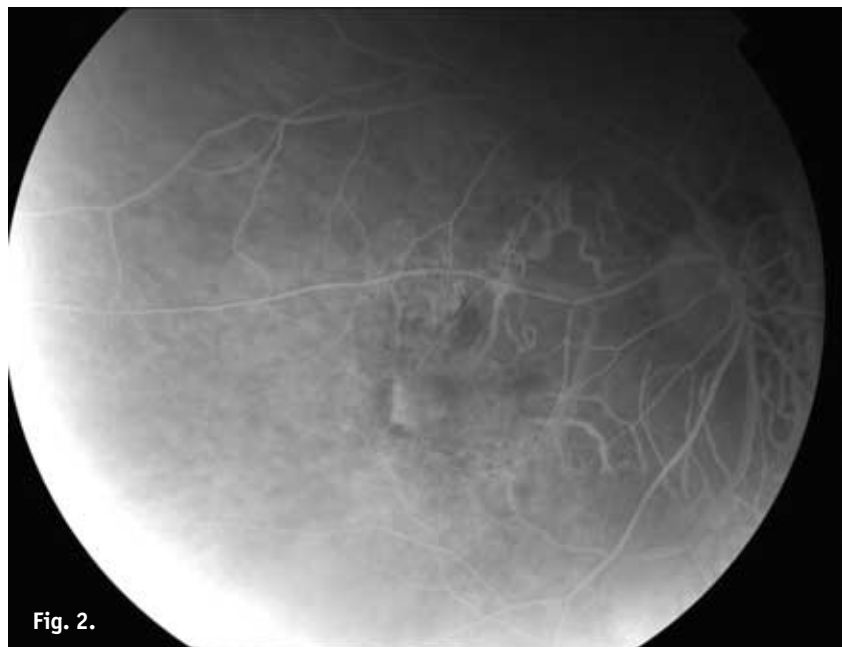
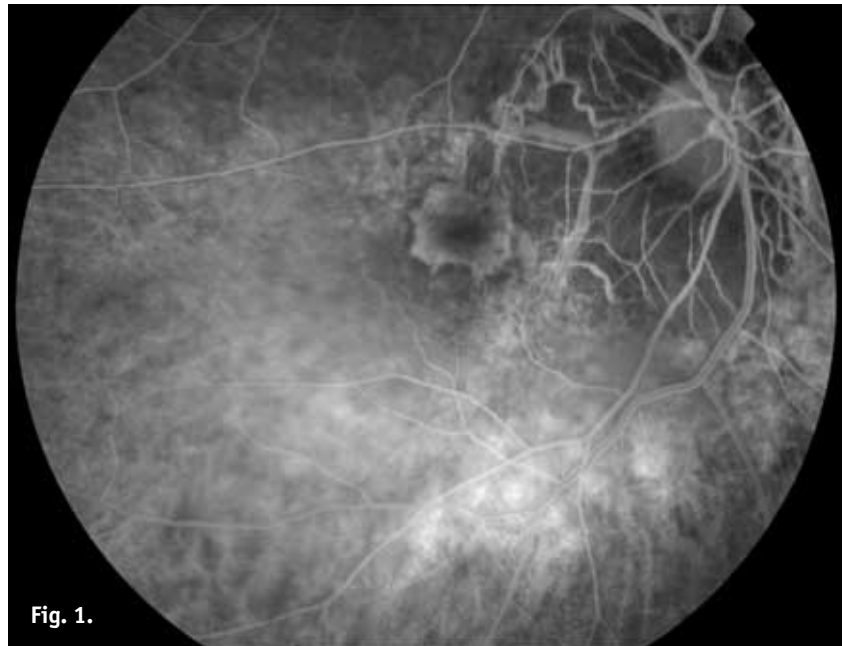


Figure 1. Subfoveal CNV on the fluorescein angiography before treatment.
Figure 2. More than 50% of classic CNV closed without leakage on fluorescein angiography after four sessions of treatment.

In developed countries the Age-related Macular Degeneration (AMD) is the most frequent cause of severe central visual loss among people older than 65 years (1). There are two forms of AMD: the dry and the wet. The slowly progressive dry (non-vascular) form accounts for about 90% of all cases. It is characterized by abnormalities of the retinal pigment epithelium (drusen, atrophy, hypopigmentation or hyperpigmentation). The wet or neovascular AMD (about 10% of all cases) is characterized by choroidal neovascularisation (CNV) (1). New vessels from the choriocapillaris proliferate through breaks in Bruch's membrane under the retinal pigment epithelium and further grow into the subretinal space. This process can lead to subretinal hemorrhage, detachment of the retinal pigment epi-

thelium and the neurosensory retina. The formation of a fibrovascular scar follows. The wet form is frequently devastating and in some cases vision may be lost within a few weeks.

So far there is no treatment possibility for patients with the dry form of AMD. For patients with the wet form there are two possibilities: photocoagulation or photodynamic therapy (PDT).

Laser photocoagulation of CNV causes nonselective thermal tissue destruction. It destroys not only surrounding choriocapillaris, but also retinal pigment epithelium and adjacent photoreceptors. This leads to an absolute scotoma at the area of treatment. Thus only extrafoveal CNV can be treated by this method (2).

The new approach of selective destruction of CNV can be applied in patients with subfoveal lesions. This treatment is based on the reaction of photoactivable drug with the light of low-energy laser beam (3). The method used in PDT is as follows. The first step is the intravenous administration of a sensitizer. It distributes throughout the choroid with preferential accumulation in CNV. The second step is its activation by non-thermal laser. Exposure to light induces generation of singlet oxygen, free radicals and other cytotoxic species. This leads to the damage of endothelial cells followed by platelet adhesion and degranulation and finally to thrombosis of the CNV selectively within the treated area.

So far only verteporfin [Visudyne, Novartis] as sensitizer is marketed and laser with wavelength of 689 nm is used. Patients with subfoveal predominantly classic lesion on fluorescein angiography (FA) and vision better than 0.1 are indicated for PDT with verteporfin (3). After several sessions (6 in two years in average) vision can be stabilized and leakage from CNV diminished as show our own results (4). But it is questionable whether to apply this very costly treatment to extremely old people.

A 90-year old woman with AMD was presented with decline of vision. An ophthalmologic evaluation elsewhere revealed the best-corrected visual acuity (BCVA) of 0.4 OD due to AMD and the BCVA of 0.01 OS due to amblyopia. Two months later BCVA worsened to 0.2 OD. After next 2 months the patient was examined in our department. The BCVA was 0.05 OD. There was bilateral nuclear sclerosis. Fundus examination revealed peripapillary atrophy of retinal pigment epithelium. Subretinal tissue in the center of macula corresponded with findings on FA, where subfoveal CNV was found, with 80% of classic component, *Figure 1*. The patient underwent first session of PDT.

Three months later leakage from CNV was found on FA. We performed retreatment at this time, 4 and 8 months later. On the last FA more than 50% of classic CNV was closed without leakage, *Figure 2*. At the last visit (eighteen months after initial and ten months after last session) the BCVA was 0.05 OD. Thickness of neuroretina on Optical Coherence Tomography was 133–250 μm , *Figure 3*. The patient is using a special magnifying lens for reading (Coil 6) achieving near vision of 0.32. The patient was able to read through the TVi Zoom device even before PDT and is able to do so today.

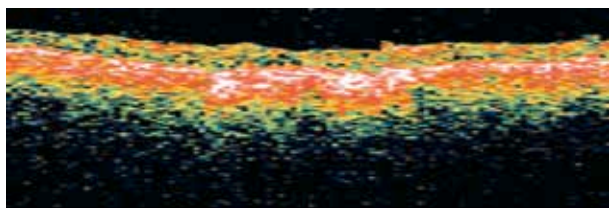


Figure 3. Thickness of the neuroretina on Optical Coherence Tomography at the last visit.

The presented example indicates the necessity of detailed study of every case to promote the therapeutic decisions for the benefit of progress in the field.

REFERENCES

- 1 Macular Photocoagulation Study Group. Argon Laser Photocoagulation for Senile Macular Degeneration: results of a randomized clinical trial. *Arch. Ophthalmol* 1982; **100**:912–8.
- 2 Soucek P, Boguszaková J, Gajdošíková Z, Machýčková J. Diagnostika, sledování a laserová léčba klasické formy chorioidální neovaskularizace u pacientu s věkem podmíněnou makulární degenerací. [(Diagnosis, follow-up and laser treatment of the classic choroidal neovascularization in patients with age-related macular degeneration.)(In Czech with English abstract.)] *Cs Oftal* 1997; **53**:94–100.
- 3 Treatment of Age-Related Macular Degeneration with Photodynamic Therapy (TAP) Study Group. Photodynamic Therapy of Subfoveal Choroidal Neovascularization in Age-related Macular Degeneration with Verteporfin: one-year results of 2 randomized clinical trials – TAP report 1. *Arch Ophthalmol* 1999; **117**: 1329–45.
- 4 Soucek P, Boguszaková J, Cihelková I. Fotodynamická terapie s preparátem Visudyne u makulární degenerace se subfoveolárně uloženou převážně klasickou chorioidální neovaskularizací. [(Photodynamic therapy with Visudyne in Macular Degeneration with Subfoveal Predominantly Classic Choroidal Neovascularization.)(In Czech with English abstract.)] *Ces a slov Oftal* 2002; **58**:89–97.