

Increased cytochrome oxidase activity in adrenal glands of thioacetamide-cirrhotic rats*

Magdalena Méndez-López¹, Marta Méndez¹, Laudino López¹, Maria-Angeles Aller², Héctor González-Pardo¹, María-Paz Nava³, Fernando Sánchez-Patán², Jaime Arias² & Jorge-Luis Arias¹

¹ Psychobiology Department. School of Psychology, University of Oviedo. Asturias Spain.

² Surgery Chair. Surgery Dept. I. School of Medicine. Complutense University of Madrid. Spain.

³ Animal Physiology Dept. (Physiology II). School of Biological Sciences. Complutense University of Madrid. Spain.

Correspondence to: M.A. Aller, MD
Cátedra de Cirugía
Facultad de Medicina, UCM
Pza. Ramón y Cajal, s/n.
28040 Madrid. SPAIN
PHONE: +34 91 394 1388
EMAIL: maaller@med.ucm.es

Submitted: October 17, 2005

Accepted: October 26, 2005

Key words: **Cytochrome oxidase; portal hypertension; thioacetamide; cirrhosis; adrenal gland; rat**

Neuroendocrinol Lett 2005; **26**(6):719-723 PMID: 16380689 NEL260605A23 © Neuroendocrinology Letters www.nel.edu

* Work supported by grants from the Ministerio de CIENCIA y Tecnología MEC-SEJ 2004/07445/PSIC, Principado de Asturias (PR-O-1-GE-2) and Foundation MMA (SV-O4-FMM-02).

Abstract

OBJECTIVES: Cytochrome oxidase activity has been determined in the adrenal glands of thioacetamide (TAA)-cirrhotic rats.

MATERIAL AND METHODS: Two groups of animals (Control group; n=10 and TAA group; n=11) of three months evolution were used to study the cytochrome oxidase activity in the suprarenal cortex (glomerular, fascicular and reticular layers) and medulla. TAA was administered orally and cytochrome oxidase (COX) activity was assayed by an immunohistochemical technique.

RESULTS: In TAA-cirrhotic rats, COX activity increases in the cortex fascicular layer (221 ± 1.79 vs 181.9 ± 2.75 ; $p < 0.001$) as well as in the medulla (146.6 ± 1.72 vs 129 ± 3.09 ; $p < 0.001$).

CONCLUSION: These results make it possible to consider the existence of hypothalamic-pituitary-adrenal-axis and adrenomedullary sympathetic system hyperactivity, both peripheral limbs of the stress system, in this experimental model of cirrhosis.

Abbreviations:

ACTH – Adrenocorticotrophic hormone
ATP – Adenosin triphosphate
COX – Cytochrome C oxidase
CRF – Corticotropin releasing factor
HPAA – Hypothalamic-pituitary-adrenal axis
TAA – Thioacetamide

Introduction

Thioacetamide (TAA) is a potent drug to induce liver macronodular cirrhosis [1,2], TAA-induced cirrhotic rats manifest clinical symptoms of portal hypertension [2,3], splanchnic and systemic hyperdynamic circulation and portal-systemic shunting [3].

These systemic and splanchnic hemodynamics alterations in experimental liver cirrhotic-rats induced by TAA [3] could be considered as a type of trigger response of the stress system. Therefore, TAA-cirrhotic rats could present a response of the stress system in which the peripheral limbs are the hypothalamic-pituitary-adrenal axis (HPAA) and the sympathetic and adrenomedullary (sympathetic) systems [4].

One way to assess the neuroendocrine response to hemodynamic alterations in TAA-cirrhotic rats consists of studying the metabolic and functional activity patterns in adrenal glands (cortex and medulla), using mitochondrial enzyme cytochrome C oxidase (COX) as a histochemical marker [5,6,7]. COX catalyzes electron transfer from cytochrome C to oxygen and the reaction necessary for ATP synthesis by its coupling with oxidative phosphorylation [8]. Increased cell activity, therefore, leads to increased cellular respiration and COX activity to produce more ATP [6]. For this reason, COX is used as an endogenous marker of local tissue metabolic capacity due to its pivotal role in cellular respiration [5].

Material and methods

Male Wistar rats, with weights ranging between 200 and 250 g from the Vivarium of the Complutense University of Madrid were used.

The experimental procedures employed in this study are in accordance with the principles and practices of the 1986 Guidelines for the Care and Use of Laboratory Animals, published in the RD 1201/2005 in Spain.

Experimental Design.

The animals were divided into two groups: a Control group (Group I; n= 10), in which the animals did not undergo any operative intervention and TAA treated rats (Group II; n =11), in which TAA was administered in the drinking water, according to the method described by Li et al [2]. In brief, the rats receive an initial dose of TAA (0,04%) which was subsequently modified according to the weight changes in response to TAA during the time of cirrhosis induction (16 weeks).

All the animals were sacrificed by pentothal overdose at 3 months of evolution and body (BW), liver (LW) and spleen (SW) weights were determined.

Portosystemic collateral circulation study method.

Portosystemic collateral circulation was studied as follows. First, a midline abdominal incision with a large bilateral subcostal extension was performed and then the areas in which the collateral venous circulation was developed, i.e. the splenorenal, gastroesophageal, colorectal and hepatic hilum, were carefully studied for the presence of increased collateral venous [9].

Portal vein pressure measurement.

Splenic pulp pressure, an indirect measurement of portal pressure (PP), was measured by inserting a fluid-filled 20-gauge needle into the splenic parenchyma [10]. The needle was joined to a PE-50 tube and then con-

nected to a pressure recorder (PowerLab 200 ML 201) and to a transducer (Sensoror SN-844) with a Chart V 4,0 computer program (ADI Instruments) and was calibrated before each experiment. The pressure reading was considered satisfactory when a stable recording was produced and respiratory variations were observed. Previous studies have demonstrated the excellent correlation between splenic pulp pressure and PP [11].

COX histochemical labeling of tissue.

The animals were vascularly perfused with 0.1 M phosphate buffer (pH 7.4). After perfusion, suprarenal glands (left and right) were extracted, sectioned along the middle and immersed in phosphate buffer (0.1 M and pH 7.4) for 24 hours. Then, the samples were coated with a cryoprotective gel (Tissue Freezing Medium, Leica, Nussloch, Germany), frozen with Klea 134-a, and stored at -80°C . They were sectioned in a cryostat (Microm, Heidelberg, Germany) at -20°C and 20 μm -thick sections were obtained. The sections were histochemically processed to reveal COX by diaminobenzidine according to a modification of the Wong-Riley method [5] by Sukekawa [12].

To quantify COX activity, the method described by Gonzalez-Lima and Jones [13] was used. Our research group has previously used an adaptation of this technique in developmental brain studies [14]. The densitometry of the histochemical COX stain was measured by a computer image analyzer (System IMCO-10) attached to a microscope (Leica, Q-Win, Wetzlar, Germany). Organ regions were selected on the screen using a digitizer board as input device. The image pixels inside these regions are automatically converted to gray tones that correspond to integrated mean optical density values. The scale of gray values was modified according to the tissue studied and converted to a relative scale. This scale is created by taking a white space as a point of reference to create the gray tone scale discounting tones recorded in the white space. The microscope light source remains constant across measurements, since its intensity is computer controlled. Six measurements of each of the differentiated regions of the suprarenal samples (cortex, glomerular, fascicular and reticular layers and medulla) were taken.

Statistical analysis.

The results of body and organ weights as well as the portal pressure are expressed as the mean \pm standard error. The Student's test for unpaired samples was used for statistical comparison of these variables between Groups I and II. The COX activity values are expressed as median and interquartile range and the Mann Whitney U non-parametric test for comparison of hypotheses to compare Groups I and II after showing non compliance with the assumption of homogeneity of variance. All comparisons were considered to be statistically significant if $p < 0,05$.

Table 1. Body weight increase (BWI), liver (LW) and splenic (SW) weights and liver weight to body weight ratio (LW/BW x 100) in control rats (Group I) and thioacetamide treated rats (TAA) (Group II).

GROUP	BWI (g)	LW (g)	LW/BW X100	SW (g)
I (Control) (n=10)	216.56 ± 28.64	10.95 ± 0.83	2.70 ± 0.12	0.87 ± 0.13
II (TAA) (n=11)	3.11 ± 32.98*	11.55 ± 1.12*	4.96 ± 1.12*	0.82 ± 0.16

Mean ± SE

(*) p<0,01 statistically significant value in relation to Group I.

Results

Body and organ weights.

The animals treated with TAA (Group II) suffered a decrease (p<0.01) in body weight in relation to the Control animals (Group I). Liver weight to body weight ratio (LW/BW x 100) also shows a decrease (p<0.01) in Group II (TAA Group) in relation to Group I (Control Group) (Table 1).

There was a significant increase (p<0.01) in the liver weight/body weight index in Group II (TAA Group) compared to the Control group (Group I). However, there were no significant alterations in spleen weight (Table 1). All the livers from Group II (TAA Group) had numerous macronodules on the surface.

Porto-collateral circulation.

The animals which were TAA administered (Group II) did not show any type of extrahepatic portosystemic collateral circulation.

Portal pressure value.

The animals belonging to Group II, which were treated with TAA, showed an increase in portal pressure compared to the control animals (Group I) (Group II: 14.56 ± 2.92 vs 7 ± 0.89 mmHg in Group I) (p<0.001).

COX activity.

In the suprarenal cortex, COX values increase in the fascicular layer (p<0,001) in Group II (TAA Group) compared to Group I (Control). However, COX activity in the glomerular and reticular layers is similar in both groups (Figure 1).

In the suprarenal medulla, COX activity increased (p<0.001) in Group II (TAA Group) compared to Group I (Control) (Figure 2).

Discussion

These results show that TAA-treated rats (Group II) present an increased COX activity in the cortex fascicular layer and medulla of the suprarenal glands (FIGURE 1). These results seem to suggest a response of the stress system in rats with TAA-induced cirrhosis. In this response, both peripheral limbs, i.e. HPAA and the sympathetic adrenomedullary system [4], are activated.

Although the adrenal medulla is known to be a very active participant in the host response to stress, this response is also mediated by the sympathetic autonomic nervous system [4]. In humans, infection, trauma [15], hypotension [16] and congestive heart failure [17,18] all produce marked increases in plasma catecholamines.

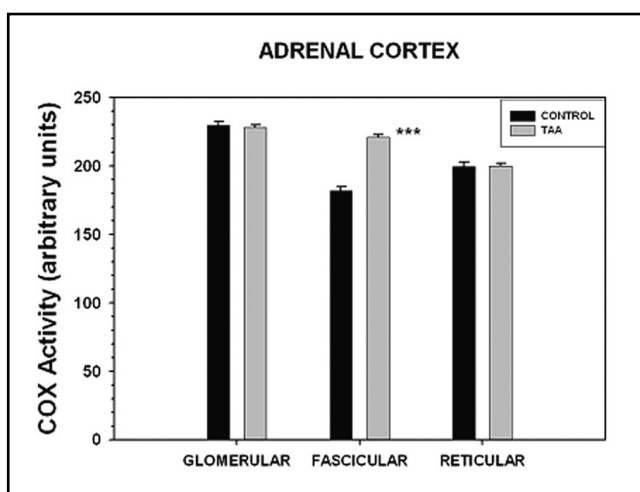


Figure 1. Cytochrome oxidase (COX) activity in adrenal cortex layers in control and Thioacetamide-cirrhotic (TAA) rats. p<0.001: statistically significant value in relation to control group.

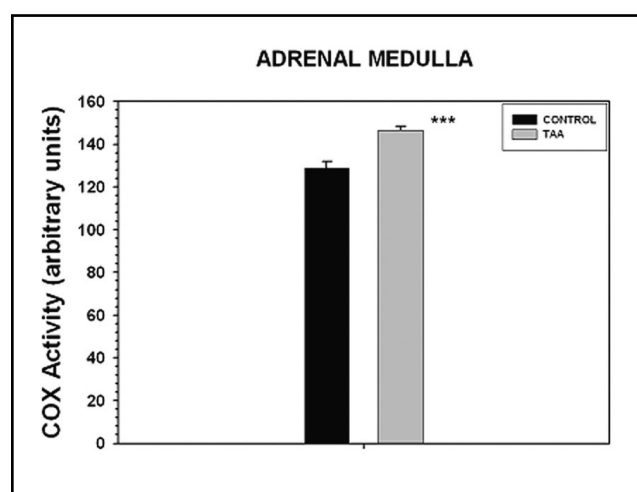


Figure 2. Cytochrome oxidase (COX) activity in adrenal medulla in control and Thioacetamide-cirrhotic (TAA) rats. p<0.001: statistically significant value in relation to control group.

Also, chronic liver disease is associated with a spectrum of neuro-endocrine disturbance (or disorders), among which changed activity and function of the adrenergic or sympathetic nervous system are prominent [19].

There is overwhelming evidence for sympathetic nervous overactivity, with elevated circulating noradrenaline and adrenaline in patients with cirrhosis and portal hypertension [19, 20]. Also, the development of more specific sympatho-adrenal blocking agents is considered to have a potential role in the future pharmacological therapy of chronic liver disease [21]. In particular, sympathetic nervous system inhibitors markedly reduced experimentally-induced liver fibrosis [22]. In this sense, it has been demonstrated that hepatic stellate cells are hepatic neuroglia that produce and respond to sympathetic nervous system neurotransmitters to promote hepatic fibrosis [23]. Likewise, owing to its antiapoptotic effect the sympathetic nervous system promotes liver cirrhosis in carbon tetrachloride treated rats [24].

In TAA-treated rats (Group II), the increased COX adrenomedullary activity would reflect the sympathetic hyperactivity that is produced in the suprarenal medulla. Enhanced adrenomedullary sympathetic activity with hyperproduction of potent vasoconstrictors such as catecholamines (adrenaline and noradrenaline) could correspond to a response to the hyperdynamic circulation developed by the TAA-treated rats [3]. This changed activity and function of the peripheral sympathetic system could, in turn, promote TAA-induced cirrhosis [23, 24].

The increased COX activity in the suprarenal cortex of TAA rats is placed in the middle fascicular layer (Figure 1) and would, therefore, indicate the existence of an increased metabolic capacity for the synthesis of glucocorticoids. Glucocorticoids are the effectors of the hypothalamic-pituitary-adrenal limb of the stress system [4, 25] and hyperactivity of the HPA axis manifesting as hypercortisolism is considered as the classical form of a generalised stress response which has escaped its usual counter-regulation [26].

The central effector of this stress response is the corticotropin-releasing factor (CRF) [4,27]. Cytokines and inflammatory mediators stimulate hypothalamic CRF release, which leads to pituitary adrenocorticotrophic (ACTH) hormone secretion into the peripheral circulation. ACTH in turn, leads to adrenal glucocorticoid production and release from the fascicular cells layer through a series of enzymatic reactions using cholesterol as the precursor [4,27,28].

CRF, like other central neuropeptides plays an important role in many cases of physiological and pathophysiological regulation mediated through the autonomic nervous system [29]. Regarding the liver, CRF aggravates carbon tetrachloride-induced acute liver injury through the sympathetic nervous pathway in rats [29,30]. Also, CRF has been involved in IFN- γ and TNF- α hyperproduction mediated by serotonin [31].

Assuming that the rise in COX activity in the fascicular region of the suprarenal gland of TAA-rats,

reflects HPA axis hyperactivity, the increased level of glucocorticoids, would have an immunosuppressive and anti-inflammatory [32] effect in response to the overproduction of proinflammatory cytokines such as TNF- α [33].

In conclusion, the changes in suprarenal gland COX activity observed in TAA-treated rats would reflect the response of the stress system, with its two peripheral limbs, that is the HPA axis and adrenomedullary sympathetic system, in this experimental model of cirrhosis.

Acknowledgements

We would like to thank Piedad Burgos and Begoña Valdes for their technical assistance.

REFERENCES

- 1 Dashti H, Jeppson B, Hägerstrand I, Hultberg B, Srinivas U, Abdulla M, Bengmark S. Thioacetamide- and carbon tetrachloride-induced liver cirrhosis. *Eur Surg Res.* 1989; **21**: 83–91.
- 2 Li X, Beenjamin IS, Alexander B. Reproducible production of thioacetamide-induced macronodular cirrhosis in the rat with no mortality. *J Hepatol* 2002; **36**:488–93.
- 3 Hori N, Okanoue T, Sawa Y, Mori T, Kashima K. Hemodynamic characterization in experimental cirrhosis induced by thioacetamide administration. *Dig Dis Sci* 1993; **38**:2195–202.
- 4 O'Connor TM, O'Halloran DJ, Shanahan F. The stress response and the hypothalamic-pituitary-adrenal axis: from molecule to melancholia. *Q J M* 2000; **93**:323–33.
- 5 Wong-Riley MTT. Cytochrome oxidase: an endogenous metabolic marker for neuronal activity. *Trends Neurosci* 1989; **12**: 94–101.
- 6 Gonzalez-Lima F. Brain imaging of auditory learning functions in rats: studies with fluorodeoxyglucose autoradiography and cytochrome oxidase histochemistry. In: Gonzalez-Lima F, Finkenshtadt TH, Sheikh H, editors. London: Kluwer. Academic Publishers; 1992; p.39–109.
- 7 Hevner RF, Liu S, Wong-Riley MTT. A metabolic map of cytochrome oxidase in the rat brain: histochemical, densitometric and biochemical studies. *Neuroscience* 1995; **65**: 313–42.
- 8 Janssen W, Fuggle SV, Rela M, Koo DDH, Heaton ND. The role of mitochondria in ischemia/reperfusion injury. *Transplantation* 2002; **73**: 493–99.
- 9 Dieguez B, Aller MA, Nava MP, Palma MD, Arias JL, Lopez L. et al. Chronic portal hypertension in the rat by triple-portal stenosing ligation. *J Invest Surg* 2002; **15**: 329–36.
- 10 Castañeda B, Dubernardi-Venon W, Bandi JC, Andreu V, Perez del Pulgar S, Moitinho E, et al. The role of portal pressure in the severity of bleeding in portal hypertensive rats. *Hepatology* 2000; **31**: 581–86.
- 11 Kravetz D, Sikuler E, Groszmann RJ. Splanchnic and systemic hemodynamics in portal hypertensive rats during hemorrhage and blood volume restitution. *Gastroenterology* 1986; **90**: 1232–40.
- 12 Sukekawa K. A fresh mount method for cytochrome oxidase histochemistry. *Biotechnol Histochem* 1991; **1**: 99–101.
- 13 Gonzalez-Lima F, Jones D. Quantitative mapping of cytochrome oxidase activity in the central auditory system of the gerbil: a study with calibrated activity standards and metal intensified histochemistry. *Brain Res* 1993; **60**: 34–49.
- 14 Gonzalez-Pardo H, Novelli A, Menendez-Patterson A, Arias JL. The development of oxidative metabolism in diencephalic structures of the rat: a quantitative study. *Brain Res Bull* 1998; **41**: 31–8.
- 15 Namazi MR. The cellular immunodeficiency associated with post-traumatic stress disorder may be the result of sympathetic overactivity and be correctable by beta-2-blockers. *Neuroendocrinol Lett* 2003; **24**: 468.
- 16 Benedict CR, Grahame-Smith DG. Plasma noradrenaline and adrenaline concentrations and dopamine-beta-hydroxylase activity in patients with shock due to septicemia, trauma and hemorrhage. *Q J M* 1978; **47**: 1–20.

- 17 Fedak PWM, Verma S, Weisel RD, Li R-K. Cardiac remodeling and failure. From molecules to man (Part I). *Cardiovasc Pathol* 2005; **14**: 1–11.
- 18 Kaye D, Esler M. Sympathetic neuronal regulation of the heart in aging and heart failure. *Cardiovasc Res* 2005; **66**: 256–64.
- 19 Henriksen JH, Moller S, Ring-Larsen H, Christensen NJ. The sympathetic nervous system in liver disease. *J Hepatol* 1998; **29**: 328–41.
- 20 Henriksen JH, Christensen NJ, Ring-Larsen H. Noradrenaline and adrenaline in various vascular beds in patients with cirrhosis. Relation to haemodynamics. *Clin Physiol* 1981; **1**: 293–304.
- 21 Moller S, Bendtsen F, Henriksen JH. Splanchnic and systemic hemodynamic derangement in decompensated cirrhosis. *Can J Gastroenterol* 2001; **15**: 94–106.
- 22 Dubuisson L, Desmouliere A, Decourt B, et al. Inhibition of rat liver fibrogenesis through noradrenergic antagonism. *Hepatology* 2002; **35**: 325–31.
- 23 Oben JA, Roskams T, Yang S, Lin H, Sinelli N, Torbenson M, et al. Hepatic fibrogenesis requires sympathetic neurotransmitters. *Gut* 2004; **53**: 438–45.
- 24 Hamasaki K, Nakashima M, Naito S, Akiyama Y, Ohtsuru A, Hamanaka Y, et al. The sympathetic nervous system promotes carbon tetrachloride-induced cirrhosis in rats by suppressing apoptosis and enhancing the growth of regenerating hepatocytes. *J Gastroenterol* 2001; **36**: 111–20.
- 25 Chrousos GP. The hypothalamic-pituitary-adrenal axis and immune-mediated inflammation. *N Engl J Med* 1995; **332**: 1351–62.
- 26 Gold PW, Goodwin FK, Chrousos GP. Clinical and biochemical manifestations of depression: relationship to the neurobiology of stress (parts 1 and 2). *N Engl J Med*. 1988; **319**: 348–53.
- 27 Campeau S, Day HEW, Helmreich DL, Kollach-Walker S, Watson SJ. Principles of psychoneuroendocrinology. *Psychiatr Clin North Am* 1998; **25**: 259–76.
- 28 Cooper MS, Stewart PM. Corticosteroid insufficiency in acutely ill patients. *N Engl J Med* 2003; **348**: 727–34.
- 29 Yokohama S, Yoneda M, Nakamura K, Makino I. Effect of central corticotropin-releasing factor on carbon tetrachloride-induced acute liver injury in rats. *Am J Physiol Gastrointest Liver Physiol*. 1999; **276**:G622–8.
- 30 Nakade Y, Yoneda M, Nakamura K, Makino I, Terano A. Involvement of endogenous CRF in carbon tetrachloride-induced acute liver injury in rats. *Am J Physiol Regul Integr Comp Physiol* 2002; **282**:R1782–8.
- 31 Maes M, Kenis G, Kubera M, Bosmans E. In humans, corticotropin releasing hormone antagonizes some of the negative immunoregulatory effects of serotonin. *Neuroendocrinol Lett* 2003; **24**: 420–4.
- 32 Pruetz SB. Stress and the immune system. *Pathophysiology* 2003; **9**:133–53.
- 33 Luo B, Liu L, Tang L, Zhang J, Ling Y, Fallon MB. ET-1 and TNF- α in HPS: analysis in prehepatic portal hypertension and biliary and non biliary cirrhosis in rats. *Am J Physiol Gastrointest Liver Physiol* 2004; **286**: G294–303.